

PAPILLARY CYSTADENOMA LYMPHOMATOSUM

A Review and Report of Eight Cases

GEORGE F. STEVENSON, M.D.* and JOHN B. HAZARD, M.D.

Department of Pathology

PAPILLARY cystadenoma lymphomatousum, a distinctive benign neoplasm occurring in or adjacent to the parotid gland, has been known by a variety of names including adenolymphoma, onkocytoma, onkocytic cystadenoma, orbital inclusion cystadenoma, and branchiogenic adenoma. Although this neoplasm was first mentioned by Hildebrand¹ in 1895 it was not until 1910 that it was recognized as a distinct entity by Albrecht and Arzt.² Since then many cases have been reported, the total reaching 108 in 1946.³

A review of some aspects of this neoplasm and a summary of 8 additional cases are included in this report.

Histogenesis

Many theories as to the mode of origin of papillary cystadenoma lymphomatousum have been proposed. Hildebrand¹ thought that it was of branchial cyst origin, a view that has been supported by a number of observers. Albrecht and Arzt,² however, believed that the neoplasm arose in embryologically misplaced salivary gland tissue occurring in lymph nodes adjacent to the parotid gland. Subsequently various authors postulated that the tumor originated from evaginations of the embryonal buccal endoderm,⁴ ectopic tonsil,⁵ thymic anlage,⁶ undifferentiated salivary structures,⁷ or vestigial orbital inclusions.⁸ Warthin⁹ in describing the first case reported in the American literature (1929), believed that it began in accessory eustachian tube anlage which had assumed a neoplastic tendency. In 1931 a new theory was introduced by Hamperl^{10,11} who suggested that papillary cystadenoma lymphomatousum originated from onkocytes—granular eosinophilic cells appearing in the parotid glands of adults. Recently a number of observers have concluded that histogenesis from parotid ducts provides a simple and adequate explanation of various features of the neoplasm.

None of the histogenetic theories contribute a completely acceptable explanation of the origin of the components of the tumor. It seems obvious that the neoplastic epithelium is of parotid duct origin, as evidenced by the facts that cells morphologically identical with those of the tumor may be found at times within the parotid ducts, and that the small foci of neutrophilic cells sometimes observed in the tumors resemble those of the normal parotid duct. The extraparotid location of some of the tumors is satisfactorily explained on the basis of embryologic inclusion of parotid gland tissue within lymph nodes in the parotid region. The origin of the lymphoid tissue within the neoplasm is still doubtful; it is still uncertain whether its production is facilitated or demanded by the oxyphilic cells, or whether it is embryologically misplaced

*Former Fellow, now at Northwestern University Medical School.

tissue. The question of whether the lymphoid stroma is neoplastic or incidental also is problematical.

Pathology

Gross Findings: The gross appearance (fig. 1) of papillary cystadenoma lymphomatosum is generally distinctive but not often diagnostic. The tumors, varying in greatest diameter from 1 to 6 cm., are round to oval with a smooth or lobulated pink-gray external surface. There is usually a thin but distinct, tough, pink, fibrous tissue capsule which separates the neoplasm from the surrounding structures. Occasionally encapsulation is incomplete and the tumor may appear to infiltrate the adjacent salivary gland tissue. Generally the mass is soft or fluctuant but often firm portions exist. The neoplasm cuts with ease to reveal a substance that is usually partially cystic; it may, however, be wholly or entirely cystic. The cysts, which vary in size from a few millimeters to several centimeters, are of irregular contour. They are lined by granular tan tissue which generally forms tiny but distinct papillary intrusions into the lumina.

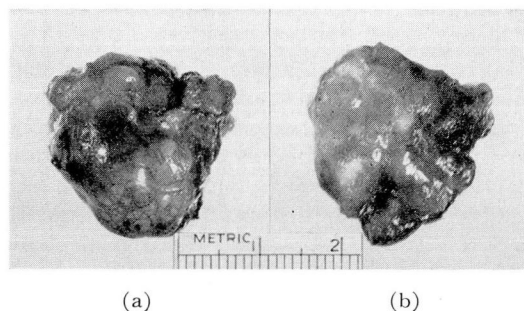


FIG. 1. Gross photograph of a typical neoplasm showing (a) outer surface with thin capsule and (b) slightly everted cut surface. The tissue was of tan color.

The spaces contain thin fluid which may be mucoid, milky or clear. The solid portions of the neoplasm have a homogenous, finely granular, moist appearance. The most diagnostic gross finding is the color of the solid portions of the cut surface and the lining of the cysts which typically is amber or pale gray-brown with an appearance identical with that of the oxyphilic (Hurthle cell) adenoma of the thyroid gland.

Microscopic Findings: The neoplasm is formed essentially of eosinophilic columnar cells arranged as branching papillary formations with stalks of dense lymphoid tissue (fig. 2). In the grossly cystic portions of the tumor the columnar cells also line large irregular spaces. In the grossly solid parts, and sometimes in the areas between the cysts, the cells are arranged also as small acini, irregular tubular structures, or rarely as solid cords. A thin capsule of dense collagenous connective tissue generally encloses these elements, sharply delimiting them from the surrounding tissues. Sometimes, however, the capsule is incomplete or even absent; in such cases there is a gradual transition from tumor to normal parotid tissue. In some instances the tissues surrounding part of the neoplasm may resemble those of a lymph node.

The columnar epithelial cells are approximately 10 by 30 microns in size;

they have eosinophilic cytoplasm containing numerous fine or prominent eosinophilic granules. Several authors^{9,12} state that cilia are present, but this feature is generally denied.^{13,14} The nuclei, placed at the outer edge of the columnar cells, are uniformly spherical, 6 to 8 microns in diameter, with coarse chromatin granules; mitoses are rarely found. Many of the nuclei are nucleolated. The columnar cells may form a single continuous layer on a thin basement membrane, but usually several layers of cells are present. Within such layers only the cells at the surface have the typical characteristics described. Interspersed between them or forming several imperfect layers at the base are smaller cuboidal to triangular cells sometimes with less eosinophilic cytoplasm and smaller nuclei. The arrangement of the layers of cells may

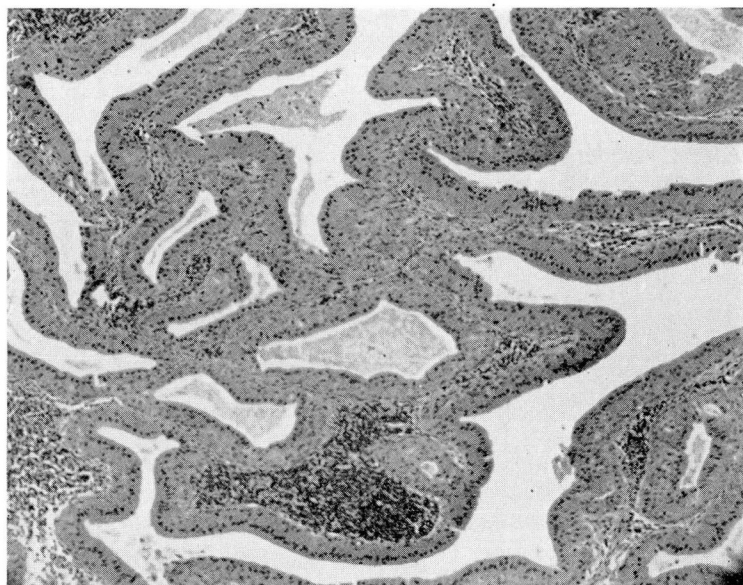


FIG. 2. Photomicrograph showing columnar epithelium, coarse papillary arrangement and a dense mass of lymphocytes in the stroma. The epithelium was oxyphilic (x70).

resemble that of pseudostratified columnar epithelium. Infrequently areas of squamous metaplasia may be present.^{12,13} Several authors^{15,16,17} have described intercellular secretion channels, but this feature has not been mentioned by other observers. The spaces enclosed by the tumor cells are filled by granular or homogenous eosinophilic material. Small foci of neutrophilic cells are usually evident either in the stroma, in the form of small solid cords, or in the lining of the spaces into which they usually extend as small crescent-shaped intrusions. These neutrophilic nongranular cells, which resemble the "basal" cells normally found in the parotid ducts, seldom exceed the oxyphilic cells in number. In such instances, especially if the lymphoid component is scant, the neoplasm may be difficult to distinguish microscopically from well-differentiated papillary carcinoma of the thyroid gland.

The neoplastic stroma is formed largely, if not entirely, by closely packed mature lymphocytes; large and well-formed germinal follicles are usually present, often in the tips of the papillary formations. In a few areas dense collagenous tissue, sometimes hyalinized, may replace the lymphoid tissue. Plasma cells and polymorphonuclear neutrophils and eosinophils frequently are discovered focally in moderate numbers in the stroma, within which also appear a few small blood vessels of normal appearance. Hemorrhage and necrosis are seen rarely.

Incidence

According to Martin and Ehrlich¹⁸ papillary cystadenoma lymphomatosum comprises about 10 per cent of benign parotid tumors and about 6 per cent of all parotid neoplasms. The lesion was encountered in the Cleveland Clinic 8 times among 159 benign and malignant parotid neoplasms (5 per cent) during a period of 25 years. It accounted for 8 per cent of all benign parotid tumors; the ratio to mixed tumors of the parotid gland was approximately 1 to 11.

Papillary cystadenoma lymphomatosum occurs predominantly in the older age groups. In Plaut's¹⁹ comprehensive series, 75 per cent of cases occurred in the fifth, sixth and seventh decades, the average age being 52. Instances have been reported, however, at the age of 12 years,² and 16 years.²⁰ The authenticity of the case described in a 2 year old child¹⁰ may be questionable. The sex distribution is striking; a large majority of the tumors has occurred in males, the sex ratio in several series varying from 4 to 1;¹⁹ 10 to 1.¹⁸

Site

Papillary cystadenoma lymphomatosum presumably may occur in or near any major salivary gland. In the majority of cases the neoplasm involves the parotid gland proper; not uncommonly, however, it lies adjacent to but distinct from the parotid gland. The submaxillary gland or its vicinity is said to be the next most common salivary gland involved. With regard to submaxillary gland location, however, there is the possibility that cases reported in this site may not be authentic because of the close anatomic relationship between the tail of the parotid gland and the posterior superior surface of the submaxillary gland.¹⁸ Carmichael's review¹³ showed the following disposition: parotid gland 20 cases, periparotid region 6 cases, submaxillary gland 6 cases. It is doubtful that the instances described in the larynx²¹ and trachea²² should be included in the group of tumors under discussion. The extraparotid neoplasms generally lie near the parotid gland but may be found anywhere along the mandible, in the retroauricular region, or along the sternocleidomastoid muscle. In the parotid and periparotid locations the neoplasms are distributed equally between the right and left sides. Bilateral tumors are not uncommon; Kerr²³ mentions 6 instances occurring among 93 cases (6.4 per cent). Multiple unilateral tumors also occur.¹⁸

Clinical Features

Papillary cystadenoma lymphomatosum follows a clinical course similar to that of the mixed tumor of the salivary glands. The neoplasm usually is noticed accidentally and may be fairly large when first seen by the physician.

Growth is typically slow and without discomfort. As a consequence the tumor may be present for many years before medical attention is sought. The pre-operative duration in the reported cases has varied from a few months to as long as 30 years, with an average of about 6 years. During this time there is generally a brief period during which rapid enlargement of the tumor occurs. Undoubtedly this is the result of rapid accumulation of fluid within the cysts rather than accelerated growth of the neoplasm. Characteristically the neoplasm is painless, although pain may occur during a phase of rapid enlargement or with secondary infection.

Examination shows a well-defined rounded mass, generally situated rather superficially in any of the locations mentioned. The tumor is usually soft, sometimes with a fluctuant character; with rapid enlargement, however, it may become firm. Fixation to adjacent structures does not occur so that the neoplasm is freely movable. Surface ulceration takes place infrequently. There is no interference with the function of the fifth nerve.

The correct diagnosis apparently has never been made solely on clinical grounds, the majority of the neoplasms having been diagnosed as mixed tumor, lymphadenitis, or branchial cyst. Sialography is of no great aid in diagnosis according to Martin and Ehrlich¹⁸ who, however, obtained positive needle biopsy specimens in 12 of 18 cases.

Excision, the treatment of choice, usually is accomplished easily because of the readily accessible location of the tumor and its sharp definition from the surrounding structures. Complete removal is generally curative but incomplete excision results in prompt recurrence. Radiation therapy is considered of little or no value.^{18,24}

Recurrence of the neoplasm has been noted in about 5 per cent of cases after apparent complete excision. Such recurrence is never prompt but occurs characteristically after several or many years. Of the 40 cases reviewed by Plaut¹⁹ 38 had no recurrence, while 2 reappeared, after 3 and 10 years respectively. In these and other instances of recurrence the second neoplasm was identical, both clinically and pathologically, with the first. The length of time before recurrence, the similarity of the clinical picture, the absence of microscopic changes, and the occasional simultaneous occurrence of multicentric tumors^{18,25} suggest perhaps that a so-called recurrence may represent the development of a new neoplasm at or near the original site.

Although several authors^{9,26,27} have suggested the possibility of malignant change in papillary cystadenoma lymphomatousum, only 6 cases have been considered in various recent reports as malignant tumors. Examination of the original reports^{28,29,30,31,32} confirms the opinion that none of these cases can be considered authentic. It can be stated unequivocally that no acceptable report has been presented on a true malignant form of papillary cystadenoma lymphomatousum.

Case Reports

The clinical and pathologic findings in the 8 cases of papillary cystadenoma lymphomatousum seen at the Cleveland Clinic are generally similar to those previously described, and may be summarized briefly in chart form.

Table 1
SUMMARY OF SOME CLINICAL FINDINGS IN 8 CASES OF
PAPILLARY CYSTADENOMA LYMPHOMATOSUM

Case	Age	Sex	Duration of Symptoms	Location	Side	Miscellaneous
1	57	M	not known	within parotid	L	recurred after 7 years
2	58	F	15 mos.	within parotid	R	
3	58	M	7 mos.	within parotid	R	
4	54	M	4 mos.	within parotid	L	two separate neoplasms
5	51	M	6 mos.	within parotid	L	
6	59	M	36 mos.	within parotid	R	
7	58	M	8 mos.	within parotid	R	recurred 1 month after incomplete removal
8	51	F	3 mos.	periparotid	L	

The principal complaint in each instance was the presence of a mass in the parotid region, associated at some time, in 4 of the 8 cases, with pain of varying severity. It seems noteworthy that in 2 of the cases the mass was noticed first during an episode of acute upper respiratory infectious disease, an occurrence which may be of diagnostic significance. In both instances the neoplasm was partially cystic so that enlargement may be attributed to the more rapid accumulation of fluid within the spaces during the course of the infection. All of the tumors were well-circumscribed clinically, freely movable, and, with one exception, nontender. All cases were treated surgically by simple excision of the tumor. In one instance curettage, performed because of an erroneous diagnosis, was followed by recurrence within a month; complete excision was carried out promptly and the patient has now lived for 1 year without further reappearance of the tumor. The recurrence of the neoplasm in 1 case, 7 years after an apparently complete incision, is especially interesting because the second tumor arose adjacent to, rather than at the site of, the original tumor.

Table 2
SUMMARY OF GROSS CHARACTERISTICS OF 8 CASES OF
PAPILLARY CYSTADENOMA LYMPHOMATOSUM

Case	Size (cm.)	Shape	Color	Consistency	Character
1	3.5 x 3 x 2	ovoid; nodular	gray-brown	firm	principally cystic
2	not known	round	gray	—	cystic
3	3 x 2.8 x 0.7	ovoid	pink-brown	—	cystic
4	2.5 x 1.5 x 1.4	ovoid	gray-brown	firm	solid
5	1.5 x 1 x 1 2.5 x 2 x 1.5	ovoid	pink-tan	soft	solid
6	2.4 x 1.2 x 1.2	ovoid	gray-brown	soft	equally solid and cystic
7	3.5 x 3.4 x 2.5	ovoid; nodular	amber	firm	principally solid
8	2.2 x 1.2 x 0.5	ovoid	gray-tan	firm	equally solid and cystic

Some of the pathologic features are of unusual interest. Although all the tumors appeared well encapsulated grossly this did not prove to be true microscopically. In 3 instances the usual connective tissue capsule was lacking, at least in part. In these the neoplastic epithelium merged with the parotid tissue, although it appeared not to infiltrate it. One of these cases was that of recurrence 7 years after apparently complete excision. In 4 of the cases, including the latter, the neoplasm was partially surrounded by a zone of dense lymphoid tissue, the architecture of which resembled that of a lymph node except that lymph sinuses could not be identified. The outer border of the lymphoid tissue zone in each instance was convex, and appeared well-defined from the adjacent parotid gland tissue—in 1 case separated from it by a thin collagenous connective tissue capsule. The lymphoid tissue of these areas was continuous with the stroma of the neoplasm. Such findings, in 4 of the 8 cases, would tend to support the theory that the lymphoid tissue of the neoplasm was derived from pre-existing immature or imperfectly formed lymph nodes at the site of origin of the neoplasm. In case 8, however, it appears probable that the tumor originated in a periparotid lymph node within which, originally, there must have been embryologically displaced parotid gland tissue.

Summary

1. The histogenesis of papillary cystadenoma lymphomatosum is discussed, together with the evidence supporting origin from parotid duct epithelium.
2. From the description of the clinical and pathologic aspects of the neoplasm, it is evident that there are no clinically diagnostic features; the microscopic findings, however, and some of the gross characteristics of the tumor are distinctive.
3. A review of the reports of malignancy in papillary cystadenoma lymphomatosum discredits the authenticity of these cases.
4. Some features of 8 additional cases of papillary cystadenoma lymphomatosum are summarized.

References

1. Hildebrand, O.: Ueber angeborene epitheliale Cysten und Fisteln des Halses. Arch. f. Klin. Chir. **49**:167, 1895.
2. Albrecht, H. and Arzt, L.: Papillare Cystadenome in Lymphdrusen. Ztschr. f. Path. **4**:47, 1910.
3. McNeely, R. G. D.: Adenolymphoma of salivary glands. Canad. M. A. J. **54**:124 (Feb.) 1946.
4. Morestin, cited by Kraissl, C. J. and Stout, A. P.⁸
5. Brachetto-Brian, cited by Martin H. and Ehrlich, H. E.¹⁸
6. Delanglade, cited by Kraissl, C. J. and Stout, A. P.⁸
7. Menetrier, cited by Kraissl, C. J. and Stout, A. P.⁸
8. Kraissl, C. J. and Stout, A. P.: "Orbital inclusion" cysts and cystoadenomas of parotid salivary glands. Arch. Surg. **26**:485 (March) 1933.
9. Warthin, A. S.: Papillary cystadenoma lymphomatosum. J. Cancer Research **13**:116 (July) 1929.
10. Hamperl, H.: Onkocyten und Geschwulste der Speicheldrüsen. Virchows Arch. f. path. Anat. **282**:724, 1931.
11. Idem: Ueber das Vorkommen von Onkocyten in verschiedenen Organen. Virchows Anat. **298**:327, 1936.
12. Robinson, D. W. and Harless, M.: Papillary cystadenoma lymphomatosum of parotid gland. Surg., Gynec. and Obst. **76**:449 (April) 1943.

13. Carmichael, R., Davie, T. B. and Stewart, M. J.: Adenolymphoma of salivary glands J. Path. and Bact. **40**:601 (May) 1935.
14. Harris, P. N.: Adenocystoma lymphomatosum of salivary glands. Am. J. Path. **13**:81 (Jan.) 1937.
15. Jaffe, R. H. Adenolymphoma (onkocytoma) of parotid gland. Am. J. Cancer **16**:1415 (Nov.) 1932.
16. Freshman, A. W. and Kurland, S. K.: Cystadenoma lymphomatosum. Am. J. Clin. Path. **8**:422 (July) 1938.
17. Wood, D. A.: Papillary cystadenoma lymphomatosum of parotid gland (onkocytoma). Am. J. Path. **11**:889 (Sept.) 1935.
18. Martin, H. and Ehrlich, H. E.: Papillary cystadenoma lymphomatosum (Warthin's tumor) of parotid salivary gland. Surg., Gynec. and Obst. **79**:611 (Dec.) 1944.
19. Plaut, J. A.: Adenolymphoma of parotid gland. Ann. Surg. **116**:43 (July) 1942.
20. Cunningham, W. F.: Branchial cysts of parotid gland. Ann. Surg. **90**:114 (July) 1929.
21. Som, M. L. and Peimer, R.: Oncocytic cystadenoma of larynx. Ann. Otol. Rhin. and Laryngol. **58**:234 (March) 1949.
22. Palmer, A.: Oncocytoma of trachea. Laryngoscope **53**:377 (June) 1943.
23. Kerr, D. A. Warthin's tumor (papillary adenocystoma lymphomatosum). Am. J. Orthodontics **33**:552 (July) 1947.
24. Beyer, T. E. and Blair, J. R.: Adenolymphoma of parotid gland. Laryngoscope **58**:1253 (Nov.) 1948.
25. Ackerman, L. V.: Oncocytoma of parotid gland. Arch. Path. **36**:508 (Nov.) 1943.
26. Swinton, N. W. and Warren, S.: Salivary gland tumors. Surg., Gynec. and Obst. **67**:424 (Oct.) 1938.
27. Wendel, A., Jr.: Papillary cystadenoma lymphomatosum. J. Cancer Research **14**:123 (March) 1930.
28. Ssoblew, L. W.: Zur Kasuistik der Branchiome. Ztschr. f. Path. **11**:462, 1912.
29. Oden, C.: Papillary cystadenoma lymphomatosum of parotid gland. Am. J. Surg. **30**:57 (Oct.) 1935.
30. McFarland J.: Histopathologic diagnosis of salivary gland mixed tumors. Am. J. M. Sc. **203**:502 (April) 1942.
31. Lederman, M.: Adenolymphoma of parotid salivary gland. Brit. J. Radiol. **16**:383 (Dec.) 1943.
32. Gaston, E. A. and Tedeschi, C. G.: Adenolymphoma of parotid and submaxillary salivary glands. Ann. Surg. **123**:1075 (June) 1946.