

# PULMONARY HAMARTOMA

## *Report of Three Cases*

DONALD B. EFFLER, M.D. and J. E. SCHEID, M.D.

Department of Thoracic Surgery

**H**AMARTOMA has been described in most organs of the body. Earliest recognition of this tumor is credited to Chiari<sup>1</sup> in 1833. Albrecht,<sup>2</sup> in 1904, described a vascular tumor of the liver, and suggested the term "hamartoma" or "error tumor." In so doing, Albrecht proposed the concept of a tumor formed by the normal tissue elements expected in that location. The term "reduplication cyst" has also been used to indicate a growth whose tissue elements are abnormal only in their quantitative value.

The hamartoma is not always a vascular neoplasm. In the lung this tumor usually is composed of bronchial elements including cartilage, muscle, fat, and mucosa. The bronchial hamartoma is ordinarily a solitary parenchymal lesion but may appear as a pedunculated, endobronchial growth. The latter type is rare; less than 15 case reports are found in the literature.<sup>3</sup>

## **Incidence**

Hamartoma of the lung is an uncommon tumor. Many are described as incidental postmortem findings which apparently had produced no clinical symptoms. Johnson and Clagett<sup>4</sup> report 2 hamartomas in a series of 384 lung resections of all types, an incidence of 0.5 per cent. Effler and Blades<sup>5</sup> list 1 hamartoma in a series of 24 resected solitary lung tumors which were asymptomatic.

The endobronchial hamartoma is extremely rare. Postlethwait and Hagerty<sup>3</sup> collected 12 cases in the world literature and reported 1 of their own. Nine of these were detected clinically, while 3 were discovered at autopsy.

## **Etiology**

The etiology of pulmonary hamartoma is not understood. A summary of the etiologic concepts reviewed by Branchi and Etchegoyen<sup>6</sup> includes 4 groups: 1. congenital malformation; 2. hyperplasia of normal structures; 3. neoplastic origin and 4. inflammatory origin.

In general, it appears that this tumor is developmental in inception and arises in misplaced bronchial anlage. Some authors<sup>7</sup> call attention to the fact that anthracosis has never been observed in this lesion despite the fact that it may be present to a noticeable degree in the surrounding parenchyma. Jones<sup>8</sup> described a large hamartoma in a newborn infant. It has been emphasized<sup>9</sup> that the lungs develop by a process of budding from the primitive bronchi with

the most primitive areas at the periphery. The columnar epithelium of these primary bronchi is surrounded by the membrana propria or basement membrane. This layer forms the connective tissue framework of the lung; muscle and cartilage develop from the fetal epithelium. It has been postulated that localized changes in the arrangement, quantity or differentiation of bronchial components could produce the hamartoma.

### Clinical Findings

The peripheral hamartoma rarely manifests itself except as an unexpected finding on the chest film. The radiographic appearance is that of a solitary "coin lesion" and is indistinguishable from tuberculoma, solitary metastasis,

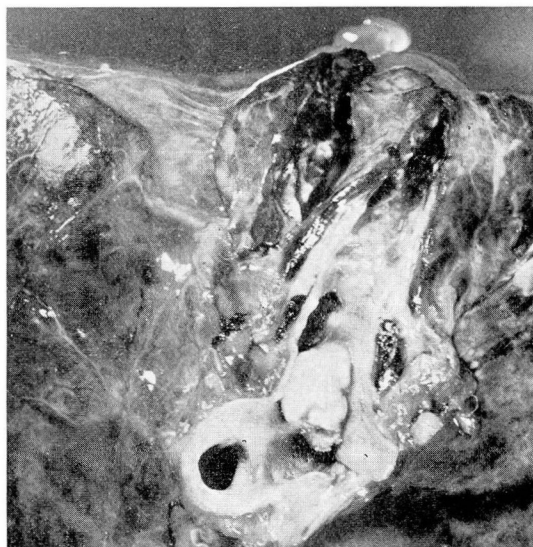

FIG. 1. Endobronchial hamartoma. Cut section through left main stem bronchus.

bronchogenic cyst, or any other lesion that may produce a spherical density in the lung field. In recent reports, Hall<sup>10</sup> and Bragg and Levene<sup>11</sup> have suggested that the diagnosis of hamartoma may be suspected in so-called "coin lesions" which have spicule-like dispersion of the calcium.

Endobronchial hamartoma is manifested by the symptoms of bronchial irritation and obstruction and clinically is indistinguishable from the bronchial adenoma, fibroma or polyp. The symptoms may be insidious in onset and intermittent in character. Usually there will be cough, hemoptysis, fever, fatigue, weight loss and chest discomfort. The patient may cough up fragments of necrotic tumor. The radiographic studies of the chest usually are compatible with obstructive pneumonitis or atelectasis.

### Case Reports

**Case 1.** A 56-year-old patient presented a history of cough, hemoptysis, and febrile episodes, for a period of 1 and  $\frac{1}{2}$  years. The cough was persistent and productive of mucoid sputum. There had been 2 major pulmonary hemorrhages, 1 of which resulted in an emergency hospitalization.

Initial examination in the Cleveland Clinic revealed a well developed Negro who did not appear ill. Physical examination and laboratory studies were noncontributory. Radiographic studies, however, were significant, and the diagnosis of left upper lobe atelectasis was made.

Endoscopic examination revealed an intrabronchial mass protruding from the left upper lobe orifice. It appeared to be polypoid in nature and was covered in part with mucosa. A biopsy was obtained and the impression of benign tumor was recorded.

Thoracotomy was performed on December 12, 1949 and the clinical impression of upper lobe atelectasis confirmed. Extensive inflammatory reaction made total pneumonectomy mandatory. The postoperative period was uneventful, and the patient has remained symptom-free to date.

Examination of the specimen (fig. 1) revealed a pedunculated mass arising from the left upper lobe bronchus. The growth which was 1 cm. in diameter and 2 cm. in length completely occluded the upper lobe bronchus. The microscopic examination revealed a central core of fat, cartilage and collagenous connective tissue surrounded by respiratory epithelium. The cartilage was distributed in bar-like arrangement and had a well-defined perichondrium. At the base of the lesion this cartilage appeared to

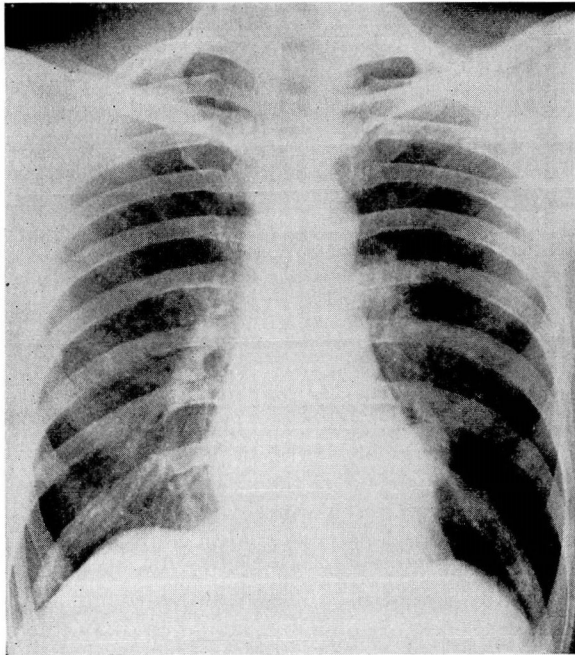


FIG. 2. Case 2. "Coin lesion" in left lower lung field.



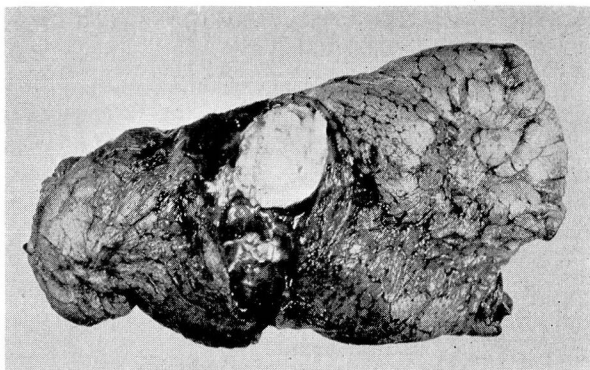


FIG. 3. Case 2. Cut section of left lower lobe revealing well-circumscribed peripheral hamartoma.

be continuous with the cartilage beneath the mucosa of the normal bronchus. There was no evidence of malignancy.

**Case 2.** A 45-year-old patient was examined at the Clinic on October 10, 1949 because of rectal bleeding. Internal hemorrhoids were observed and surgery advised. The routine chest survey revealed a "coin lesion" in the lower left lung field (fig. 2). There were no symptoms of pulmonary disease.

The tumor was removed by lobectomy a week subsequent to examination. The patient recovered promptly, and on the eighth postoperative day the hemorrhoidectomy was performed.

The gross examination of the resected tumor revealed a firm mass in the central portion of the lobe (fig. 3). On cut section the tumor measured 3 cm. in diameter and presented a mottled yellow appearance. It was firm in consistency and there appeared to be islands of cartilagenous material. On microscopic examination, nests of hyaline cartilage predominated and were imbedded in loose connective tissue. Smooth muscle, fat and epithelial lined spaces were also distributed in the stroma.

**Case 3.** A 56-year-old man was referred to the Clinic for treatment of diabetes mellitus. Roentgen examination of the chest revealed a solitary lesion in the left upper lobe that appeared uniform in density, spherical in contour and the size of a ping-pong ball (fig. 4a). There were no associated localizing symptoms. The clinical impression was either tuberculoma or peripheral bronchogenic carcinoma.

A left upper lobe lobectomy was performed on October 12, 1950. The mass seemed to be centrally located in the parenchyma of the lung. Resistance was encountered when cutting through the thick gristle-like mass which grossly consisted of white cartilaginous material dispersed in convolutions. Microscopic sections revealed broad islands of hyaline cartilage with narrow interspersed zones of loose connective tissue and small areas with cuboidal epithelium, plasma cells and occasional lymphocytes. The pathologic report was hamartoma, bronchial type (fig. 4b).

### Discussion

Parenchymal hamartoma is usually a benign, asymptomatic lesion which is detected by radiographic survey. The diagnosis can only be made by tissue study obtained at operation or postmortem examination. The significance of

this tumor from the standpoint of incidence and clinical import is slight in comparison to other solitary parenchymal lesions. Simon and Ballon<sup>12</sup> reported a hamartoma which showed local changes of malignancy although metastases were not demonstrated. In general, however, the hamartoma is considered benign.

Endobronchial hamartoma is a rare tumor which manifests itself by obstructive symptoms; though a benign neoplasm, the resultant lung damage due to bronchial occlusion may be serious. Massive hemorrhage is a distinct possibility. Comparatively few of these interesting lesions have been described, nevertheless one questions their extreme rarity. Undoubtedly some of the so-called bronchial adenomata could be classified authentically as hamartoma.

The treatment of any endobronchial benign lesion is total extirpation. Endoscopic removal is indicated when residual lung damage is slight. If irreversible secondary pulmonary changes have occurred, some form of resection is indicated. In the cases collected by Postlethwait and Hagerty,<sup>3</sup> 5 tumors were removed endoscopically and 1 by lobectomy.

### Conclusion

Pulmonary hamartoma is an interesting and rare tumor. Unless it is an endobronchial lesion, hamartoma is probably of slight clinical significance. Nevertheless, the surgical removal of all solitary asymptomatic lung tumors is generally advocated, and consequently more of these neoplasms will be discovered. Whereas the diagnosis of hamartoma may seem to be only of aca-

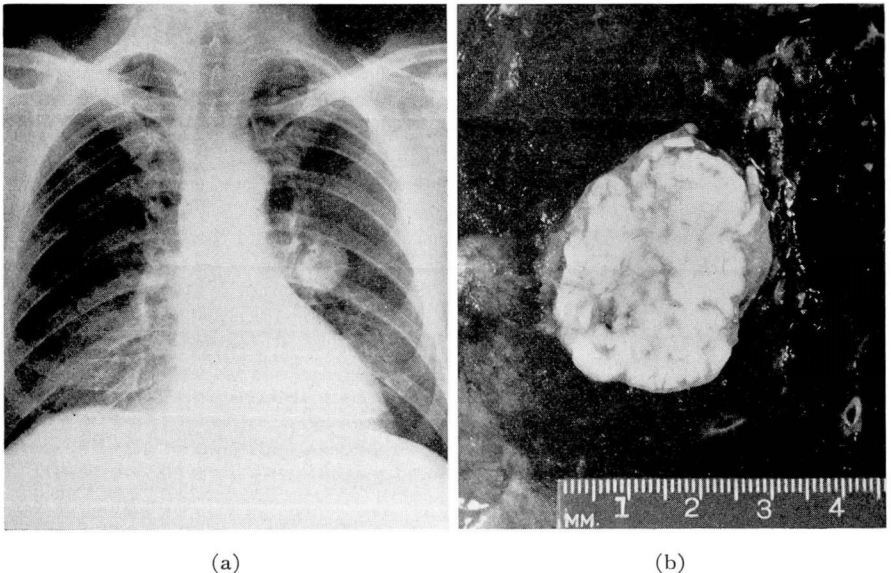


Fig. 4. (a) Roentgenogram demonstrates discrete lesion in left lung. Lateral projection localized tumor in upper lobe. (b) Cut section of specimen showing the convolutions of cartilage within the tumor.

demic interest, the pathologic identity of the solitary lung tumor makes its recognition mandatory.

### References

1. Chiari, cited by McDonald, J. R., Harrington, S. W. and Clagett, O. T.: Hamartoma of lung. *J. Thoracic Surg.* **14**:128 (April) 1945.
2. Albrecht, E.: Ueber Hamartome. *Verhandl. d. deutsch. path.* **7**:153, 1904.
3. Postlethwait, R. W., Hagerty, R. F. and Trent, J. C.: Endobronchial polypoid hamartochondroma. *Surgery* **24**:732 (Oct.) 1948.
4. Johnson, C. R., Clagett, O. T. and Good, C. A.: Importance of exploratory thoracotomy in diagnosis of certain pulmonary lesions. *Surgery* **25**:218 (Feb.) 1949.
5. Effler, D. B., Blades, B. and Marks, C.: Problem of solitary lung tumors. *Surgery* **24**:917 (Dec.) 1948.
6. Branchi, A. E. and Etchegoyen, H.: Intrapulmonary bronchial hamartoma; two cases. *Rev. Assoc. med. Argent.* **59**:787 (July 15) 1945.
7. Hickey, P. M. and Simpson, W. M.: Primary chondroma of lung. *Acta Radiol.* **5**:475, 1926.
8. Jones, C. J.: Unusual hamartoma of lung in new-born infant. *Arch. Path.* **48**:150 (Aug.) 1949.
9. Goldsworthy, N. E.: Chondroma of lung (hamartoma chondromatosum pulmonis). *J. Path. and Bact.* **39**:291 (Sept.) 1934.
10. Hall, W. C.: Roentgenologic significance of hamartoma of lung. *Am. J. Roentgenol.* **60**:605 (Nov.) 1948.
11. Bragg, E. A., Jr. and Levene, G.: Hamartoma of lung. *Radiology* **54**:227 (Feb.) 1950.
12. Simon, M. A. and Ballou, H. C.: Unusual hamartoma (so-called chondroma of lung). *J. Thoracic Surg.* **16**:379 (Aug.) 1947.