

# RUBBER TUBE IN COMMON BILE DUCT FOR TWENTY-FIVE YEARS

## *A Case Report*

STANLEY O. HOERR, M.D.  
Department of General Surgery

and

CHARLES H. BROWN, M.D.  
Department of Gastroenterology

THE following case report is believed to be of unusual interest because a rubber tube remained in the common hepatic duct of the patient for more than 25 years before it resulted in any appreciable symptomatology.

## **Case Report**

A 57-year-old bartender was first examined at the Cleveland Clinic in January 1950 because of attacks of chills, fever, and mild intermittent epigastric pain of 4 months' duration. There had been a weight loss of approximately 20 pounds during the same

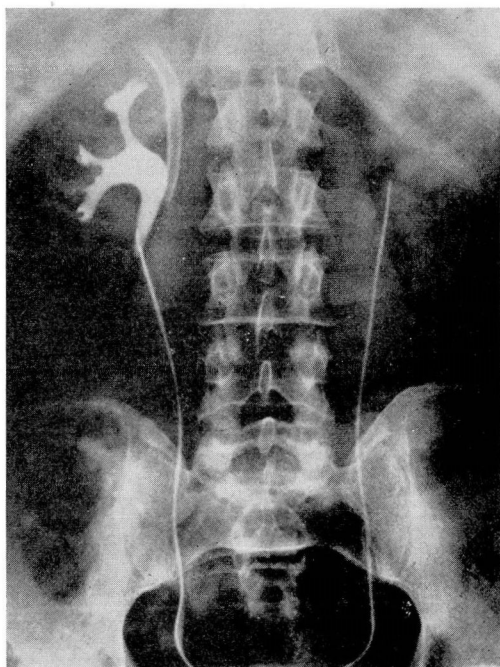


FIG. 1. Retrograde pyelogram, right. Radio-opaque rubber tube is shown just medial to shadow of renal pelvis.

## RUBBER TUBE IN BILE DUCT

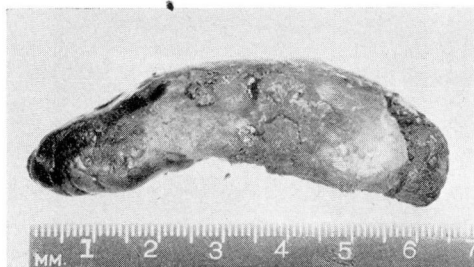

FIG. 2. Longitudinal view of calculus-encrusted rubber tube.

period. The patient thought he had detected blood in the urine on several recent occasions.

The past history included typhoid and malaria in childhood, syphilis in 1914 and gonorrhea in 1927. He had a cholecystectomy for gallstones in 1924 in another city. Fortunately, the other hospital keeps excellent records, and the following data concerning the operation are available:

The patient, then aged 32 years, entered the hospital on September 12, 1924, complaining of abdominal pain which had persisted for 3 days. Physical examination was negative except for the presence of tenderness and rigidity in the right upper quadrant of the abdomen. The urine was normal. A diagnosis of acute cholecystitis was made and operation performed a few hours after admission. The abdomen was opened through a vertical incision and the gallbladder wall found to be thickened, dark red in color with purple and gray patches. A stone could be felt in the region of the cystic duct. What was taken to be the cystic duct was divided, but it was recognized immediately that the common duct had been divided instead. The true cystic duct and cystic vessels were then identified and divided, and the gallbladder removed. The divided common duct was repaired over a rubber tube with interrupted sutures of fine catgut. The common hepatic duct was drained. The abdomen was drained and the wall closed. The pathologist reported active, chronic purulent cholecystitis with cholelithiasis. An x-ray of the abdomen taken on the fourteenth postoperative day showed the rubber

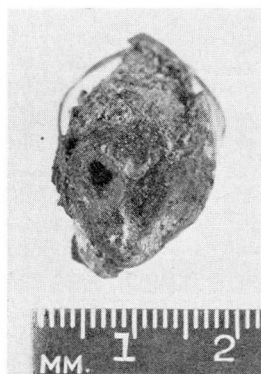

FIG. 3. View of cross-section of calculus showing lumen of rubber partially preserved at this point. (The ends were occluded.)

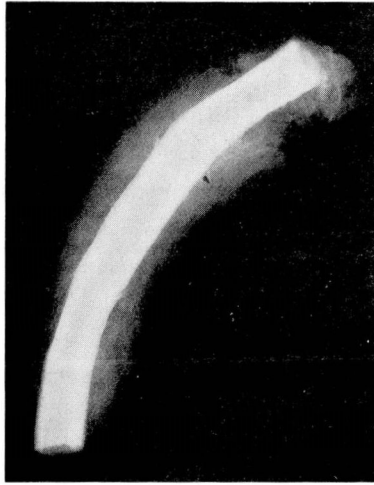

FIG. 4. X-ray of removed specimen showing rubber tube in center.

tube slightly to the right side of the spine and well below the liver shadow. The patient was discharged on the fifteenth postoperative day after a satisfactory convalescence.

Prior to the present illness the patient's health had been excellent except for mild postprandial bloating and belching, and episodes of painless vomiting once or twice a year which persisted for a day or two. There had been no jaundice, severe abdominal pain, food intolerance, change in bowel habits or alterations in the character of the stool.

**Physical examination:** Temperature was 98 F., pulse 76 and blood pressure 100/70. The patient was a tired-appearing, chronically ill man. The skin was swarthy. There was questionable icterus of the sclerae. The heart and lungs were normal. A well-healed scar was noted in the right upper abdomen. The liver edge was palpable 4 cm. below the costal margin and was regular, sharp and firm. The spleen was not palpable. There were small external hemorrhoids and moderate prostatic enlargement.

**Laboratory data:** Leukocyte and erythrocyte counts and hemoglobin determinations were within normal limits. Urine was negative except for a few pus cells in one of several specimens; the urine culture was sterile. The blood Wassermann and Kahn tests were negative. The sedimentation rate was elevated to 2 mm. per minute (normal 0.5 mm. per minute). The bromsulphalein retention was 24 per cent, 40 per cent and 40 per cent (normal 10 per cent) on three occasions. The cephalin flocculation test was negative and the icterus index was 10 units (normal to 8). The indirect serum bilirubin test was 2.7 mg. and 2.0 mg. on two examinations (normal to 1.5 mg.).

**X-rays:** The chest was normal. KUB examination showed a radio-opaque tube in the right upper quadrant. Esophagus, stomach, duodenum and colon were normal by barium study. A right retrograde pyelogram made at the time of cystoscopy was also normal, and showed that the tube was not related to the kidney (fig. 1).

**Operation:** The abdomen was explored on March 14, 1950 after excision of the old operative scar; gas-oxygen ether endotracheal anesthesia was used. There were dense adhesions but the calculus was readily palpated and exposed in a greatly dilated common duct. The lumen of the common duct was almost completely occluded by the cigar-shaped calculus containing the rubber tube in its center (figs. 2, 3 and 4). The

calculus was removed easily and a T tube inserted into the common duct. The abdomen was drained and closed with wire sutures and skin clips.

The removed specimen was described as follows: "A hard mass of black and yellow mottled color, which measured 6.5 by 1.5 cm. in greatest diameter. Cross sections reveal a central red rubber catheter with partly obliterated lumen."

Convalescence was smooth except for deep induration about the operative wound suggesting an intra-abdominal inflammatory mass; this condition was unaccompanied by fever, and ultimately subsided. Cholangiograms on the ninth postoperative day were normal although the common duct was still dilated (fig. 5). The T tube was removed on the eleventh postoperative day and the patient discharged 3 days later. When last seen in June, 1950, nearly 3 months after the operation, the patient was well except for mild constipation. He had regained his preoperative weight and was planning to return to work. Liver function tests were normal as shown by a bromsulfalein retention of 6 per cent, a negative cephalin-flocculation test, a thymol turbidity of 1.2 units, serum albumin 4.2 Gm. and serum globulin 2.4 Gm.

### Comment

The foregoing case exemplifies the advantage of prompt recognition of a terrifying accident—the division of the common duct—with appropriate repair carried out at the time of the injury. Physicians familiar with the course

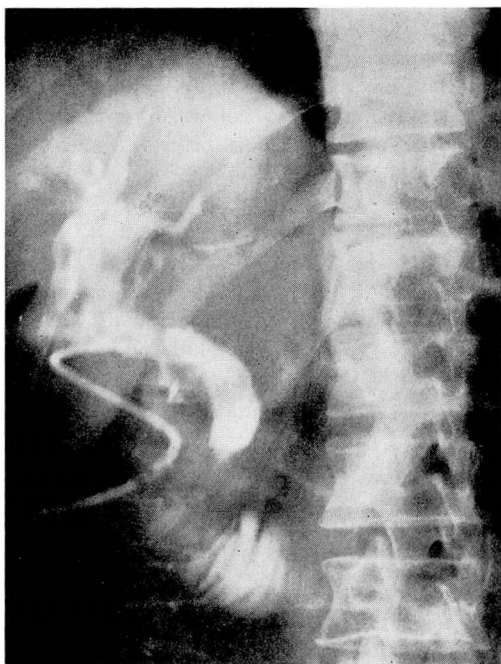


FIG. 5. Postoperative cholangiogram. Common duct still dilated but unobstructed; foreign body has been removed.



of "biliary cripples" who so often require repeated plastic procedures for a damaged common duct, will accept a 25 year "cure" as an excellent result. A rubber tube used as an internal splint for a repaired common duct usually will pass spontaneously, and it must be regarded as "hard luck" rather than poor management that the one used in this patient did not. It is noteworthy, however, that the common bile duct could retain a foreign body for such a long time before causing the host any appreciable difficulty. Finally, the case demonstrates that the common duct may be occluded almost completely by a foreign body without the development of clinical jaundice. The symptoms which did develop were undoubtedly the result of recurrent cholangitis and partial hepatic insufficiency. It may be that the "red urine" which the patient noted on two or three occasions actually represented bile in the urine, and that his naturally dark complexion obscured the other manifestations of a transient jaundice. Although the follow-up is short, the absence of symptoms and the apparent return of normal liver function suggest a good prognosis.

### Summary

A case is reported in which an accidental division of the common bile duct occurred during a cholecystectomy for acute cholecystitis more than 25 years previously. It was repaired immediately, and the surgeon utilized a short length of rubber tube as an internal splint. The tube failed to pass and ultimately became encrusted with sufficient calcareous deposit nearly to occlude the duct. Nevertheless, disabling attacks of cholangitis did not occur for 25 years, nor did an irreversible biliary cirrhosis develop. Operative removal of the large calculus which formed over the tube was easily effected, and the patient appeared to be in good health 3 months after the second operation.