

# MASSIVE VITAMIN B<sub>12</sub> THERAPY IN PERNICIOUS ANEMIA

DONALD W. BORTZ, M.D., and JOHN D. BATTLE, JR., M.D.

Department of Internal Medicine

RICKES<sup>1</sup> and his co-workers and Smith<sup>2</sup> in 1948 simultaneously reported the development of a new material which they had isolated and found to be of value in the treatment of pernicious anemia. Numerous reports have appeared in the literature since this initial introduction of vitamin B<sub>12</sub> to the medical profession. It is now generally recognized that the parenteral administration of this crystalline material commercially obtained from *Streptomyces griseus* is equally effective as liver extract in controlling the hematologic and neurologic manifestations of pernicious anemia.

A patient with neurologic manifestations of pernicious anemia was given massive parenteral injections of vitamin B<sub>12</sub>\* to determine whether a more rapid response could be obtained than with conventional methods of therapy.

## Case Report

A white housewife, 65 years of age, was first seen at the Clinic on October 10, 1949, with the chief complaint of difficulty in walking since a stroke 3 years before. In 1947 there had been an abrupt onset of inability to use the right arm and leg satisfactorily following a fall. Since that time she complained of difficulty in maintaining her balance and of numbness of both legs and the right arm. One week prior to admission she dislocated her right shoulder. The dislocation was reduced without difficulty. The patient's past history and that of her family were noncontributory; she denied any history of anemia.

Physical examination revealed an elderly, obese patient not appearing acutely ill. Her blood pressure was 190/110, pulse 100 and regular, temperature normal. The skin and mucous membranes disclosed no significant pallor, icterus or cyanosis. The tongue showed slight atrophy about the edges. The examination of the heart, chest, lungs, and abdomen was normal. The cranial nerves were normal. There was a peculiar limping gait favoring the right leg. The Romberg sign was equivocal. The deep tendon reflexes were normal, with the exception of the achilles tendon reflexes which were absent. Moderate hypesthesia was noted below the knees and vibratory sensation was absent. The clinical impression was arteriosclerosis with hypertension and residual changes of cerebrovascular accident.

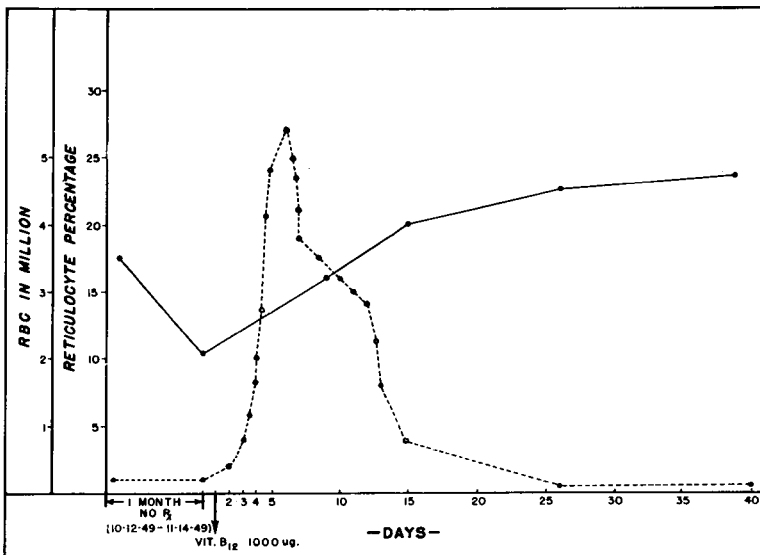
The red blood cell count was 3,560,000 per cu. mm., the hemoglobin was 9.8 Gm. per 100 cc. or 64 per cent of normal, the volume index was 1.03, color index 0.90, the white blood cell count was 3850 with a normal differential. The reticulocytes were 1 per cent. The icteric index was 4. The stained film revealed moderate anisocytosis and poikilocytosis. A routine urinalysis was normal. The blood sugar was 95 mg. per cent 5 hours after eating. The blood Wassermann and Kahn reactions were negative.

\*Kindly supplied by Merck and Company, Rahway, New Jersey.

The x-ray examination of the chest was normal, with the exception of moderate left ventricular enlargement and calcification of the arch of the aorta. The electrocardiogram revealed a left bundle branch block.

The patient was unable to remain for further studies or treatment so she was urged to return at her earliest convenience. She returned exactly 1 month later at which time she was unable to walk without assistance. Pallor of the skin and mucous membranes was clinically evident. The Romberg sign was positive and the vibratory sensation was absent below the waist. The biothesiometer test (quantitative vibratory determination) revealed a complete loss of vibratory perception below the iliac crest. There was no urinary bladder disturbance. The patient was admitted to the hospital and the diagnostic procedures were completed. The red blood cell count was 2,180,000, hemoglobin 6.5 Gm. (42 per cent of normal), volume index 1.07, color index 0.95. The white blood cell count was 2800. The reticulocytes were 1 per cent. The icteric index was 5. The stained blood film revealed severe anisocytosis with macrocytosis. Many of the granulocytes were hyperlobulated. The platelets were diminished. The bone marrow obtained by sternal aspiration was megaloblastic. The gastric analysis revealed an absence of free hydrochloric acid. The remainder of the laboratory studies were normal.

On November 14, 1949, the patient was given 1000 micrograms of vitamin B<sub>12</sub> intramuscularly and maintained on the regular hospital diet. An entirely satisfactory hematologic response was obtained (Table). Within a few days subjective improvement was noted in her appetite and sense of well being. In 1 week's time she was able to remain out of bed for several hours and to walk with minimal assistance. Two weeks following the administration of vitamin B<sub>12</sub>, there was distinct improvement in her walking ability although a re-check of the quantitative vibratory determination showed no change. Progress visits and examinations were made in the fifth, seventh, eighth, and thirteenth weeks following the initial injection of vitamin B<sub>12</sub>. By the thirteenth week she was remarkably improved in her walking ability and was able to walk without the assistance of crutches or a cane. At this time the position sense and epicritic sen-



sation of the feet and toes were normal. The vibratory sensation showed no appreciable improvement. She continued to complain of numbness, tingling and burning of her feet and, to a lesser extent, of her hands.

On February 6, 1950, approximately 13 weeks following the first injection of vitamin B<sub>12</sub>, she was given a similar dose of 1000 micrograms of vitamin B<sub>12</sub> intramuscularly. Progress examinations at monthly intervals showed slow though continued improvement in her walking ability, but no appreciable change in vibratory perception. Progress blood counts have been entirely normal.

### Discussion

A patient with severe and progressive posterolateral sclerosis was selected for the administration of huge clinical doses of parenteral vitamin B<sub>12</sub> to determine if these changes could be more rapidly and completely relieved than by the conventional method of daily injections of small doses. The hematologic response was entirely satisfactory with the single injection of 1000 micrograms of vitamin B<sub>12</sub>. The neurologic manifestations showed a gratifying response and the subjective and objective degree of improvement appeared to be greater and more rapid than one would expect with the daily injections of vitamin B<sub>12</sub> over the same period.

There is no way of determining the actual deficiency in liver units or micrograms of vitamin B<sub>12</sub> which exists in patients with pernicious anemia. The clinician is forced to give treatment in excess of the actual deficiency.

The fate of parenterally administered vitamin B<sub>12</sub> is not clear. There is evidence that part of it is excreted unchanged in the stool and urine. An undetermined percentage of the unaltered vitamin B<sub>12</sub> is stored in the liver. The metabolic or enzymatic changes of vitamin B<sub>12</sub> are unknown. There is no satisfactory method to determine how long the vitamin B<sub>12</sub> remains in the liver or other tissues. It is possible that preparation of a satisfactory radioactive vitamin B<sub>12</sub> will aid in clarifying the metabolism of this compound.

To date the parenteral injections of large doses (1000 micrograms) of vitamin B<sub>12</sub> have not produced any local or systemic toxic effects in this patient or in several others under observation. No evidence of allergy or skin sensitivity has been noted.

We believe that the further clinical trial of large doses of vitamin B<sub>12</sub> in patients with neurologic manifestations associated with pernicious anemia is warranted.

### Summary

A patient with pernicious anemia having severe posterolateral sclerosis was treated with large parenteral doses of vitamin B<sub>12</sub>. Improvement of the neurologic manifestations appeared to be more rapid than is usually observed in patients treated by conventional methods.

### References

1. Rickes, E. L. et al. Crystalline vitamin B<sub>12</sub>. *Science* **107**:396 (April 16) 1948.
2. Smith, E. L. Purification of anti-pernicious anemia factors from liver. *Nature* **161**:638 (April 24) 1948