

THE SURGICAL TREATMENT OF SPASMODIC TORTICOLLIS

A. T. BUNTS, M.D.

Department of Neurosurgery

THE involuntary, uncomfortable, and irregular jerking movements of the head which characterize spasmodic torticollis impose a physical and mental burden upon the patient. They interfere with and sometimes prevent the proper performance of occupational duties and enjoyment of social activities. The disorder has been recognized for centuries and has failed to respond to many forms of treatment. However, modern neurosurgical technics have brought many successful results.

Spasmodic torticollis has been adequately defined by Patterson and Little¹ as "an involuntary hyperkinesis manifesting itself by mobile, tonic, or clonic spasms of the neck musculature, and producing more or less stereotyped deviation of the head into an abnormal position, the chin being rotated to one side or the head bent directly forward (antecollis) or backward (retrocollis)." The spasms are abolished by sleep and aggravated by emotional stress, but the cause of the disorder is not known. Although a pure psychogenic origin is upheld by a few neurologists, such a cause is extremely rare, and most modern writers favor the theory of organic origin. This condition must be differentiated from the ischemic or traumatic wry-neck of childhood due to injury to the sternomastoid muscle; in the latter there is a constant contraction due to shortening of the muscle as a result of infiltration of the intramuscular fasciae, as pointed out by Rugh,² while the muscle contractions of spasmodic torticollis are irregular and clonic in nature. It is also obviously different from the constant moderate head tilt observed in ocular torticollis, caused by disorders of the eye muscles, as described by Kennedy.³

Although many patients with spasmodic torticollis appear to have an unstable nervous make-up, it is extremely difficult for a careful observer to attribute the violent and uncontrollable neck spasms which occur to "nervousness," hysteria, psychoneurosis, or other psychologic disorders. It seems much more likely that the condition is related to the dystonias and athetoses, in which definite organic changes have been found in the basal ganglia of the brain.

Opportunities for careful studies of the brain in spasmodic torticollis are rare, as the disease does not cause death. In 1 man who died at the age of 90, having had spasmodic torticollis for forty-seven years, Alpers and Drayer⁴ reported that postmortem examination of the brain revealed atrophy of the neostriatum, marked disease of the large ganglion cells of the putamen and caudate nucleus, less severe involvement of the small ganglion cells, and moderate disease of the pallidal ganglion cells. The cortex and the other basal ganglia were normal. These authors cited 4 other cases with necropsy studies in which neostriatal changes were found. They concluded that in some cases of spasmodic torticollis there is an organic basis. A cause for such changes in

the basal ganglia is not clear from analysis of the histories of most patients with spasmodic torticollis.

It has been thought by some that encephalitis might play an important role in etiology, but Patterson and Little¹ in a survey of 103 patients found a definite history of previous inflammation of the brain in only 5 cases. It was their impression that the extrapyramidal and vestibular systems are involved in the mediation of most cases of spasmodic torticollis and that psychogenic causation is rare. Trauma of the brain or of the cervical region of the spine does not appear to be of etiologic importance. In spite of an apparent organic basis for most cases, occasional reports of relief by psychotherapy, such as those of Rand⁵ and others, cannot be overlooked. Repeated rotational movements of the head over a prolonged period of time, as required in certain occupations, have been thought by some to play a part in the initiation of spasmodic torticollis.

The chief clinical manifestation of the condition is a series of irregular jerky movements of the head, the chin being turned toward one side and tilted upward. If the head is turned toward the left, the right sternomastoid muscle appears to be hypertrophied and to contract irregularly, and if turned toward the right, the left sternomastoid muscle appears to be affected. These movements may begin gradually at any time of life, becoming more severe with the passing of years, occurring throughout the patient's waking hours, and in abeyance only during sleep. The violent muscular contractions are most uncomfortable and may be painful. In addition to the evident spasm of the sternomastoid, all of the other superficial and deep rotator muscles of the neck are involved. The importance of the latter was not appreciated for many years. These include the smaller muscles such as the several rectus capitis and obliquus capitis muscles with attachments to the atlas, axis, and occipital bone, as well as the larger muscles such as the trapezius, splenius capitis, longissimus capitis, semispinalis capitis, longus capitis, levator scapulae, and scaleni. The patient is unable to control these movements voluntarily or to prevent them except, strangely enough, by slight pressure against the chin, a phenomenon which supported Brissaud's⁶ idea of a psychogenic origin.

In addition to psychotherapy, various nonsurgical measures have been tried for the relief of this condition. Physical therapy, including heat, massage, manipulation, head traction, and electricity, have failed, and sedatives, braces, and collars have proved of little or no avail. Rugh² has reported relief by prolonged fixation of the head, neck, and shoulders in plaster for periods of six months to two and a half years.

Prior to 1891 surgical efforts to relieve the condition were limited chiefly to sections, resection, or tenotomies of the sternomastoid muscle, although Campbell de Morgan⁷ (1866) was among the first to resect the spinal accessory nerve in the neck, thus paralyzing the muscle. Nerve stretching was also tried. None of these procedures gave satisfactory results. It finally became apparent that the nerve supply to the other rotator muscles of the neck must also be interrupted. In 1891 Keen⁸ reported unilateral section of the posterior divisions of the first three cervical nerves at their exits from the intervertebral foramina.

Later surgical experiences brought about important technical changes which gradually led to the modern operation.

Taylor⁹ (1915) reported the first intraspinal attack upon this condition, carrying out unilateral division of the sensory roots of the upper four cervical nerves, following a suggestion by Foerster¹⁰ for reduction of incoming stimuli from the muscles in the relief of the spasticity of Little's disease; in this case he also divided the spinal accessory nerve in the neck. McKenzie¹¹ (1924) reported an operation in which Cushing performed an intrameningeal section of the spinal accessory nerve at the jugular foramen and of the motor and sensory roots of the upper three cervical nerves on the same side. Finney and Hughson¹² (1925) divided both spinal accessory nerves in the neck and performed a bilateral section of the posterior divisions of the upper three cervical nerves at their points of emergence from the intervertebral foramina.

Dandy¹³ reported 8 cases in which he had performed intradural section of the anterior and posterior roots of the upper three cervical nerves on both sides and bilateral section of the spinal accessory nerves in the neck. Of these patients 5 were practically cured, 2 were greatly improved, and 1 died of pneumonia three weeks after operation. In later cases he performed the same operation but preserved the posterior roots, and the results were equally satisfactory. Since that time the latter operation has been employed by most neurosurgeons for the relief of intractable spasmodic torticollis. Adson, Young, and Ghormley¹⁴ (1946) found that this procedure sometimes resulted in subluxation and anterior curvature of the upper cervical vertebrae with falling forward of the patient's head and interference with swallowing, breathing, and speaking. In order to prevent this sequel they recommended the use of a bone graft from the ilium extending from the occipital bone to the level of the fifth cervical lamina on both sides. This was carried out immediately after the completion of the nerve sections, and the head and neck fixed in plaster for ten to twelve weeks.

In 1947 Putnam and Herz¹⁵ reported successful results with intradural section of the first three cervical anterior nerve roots on both sides and of the spinal accessory nerve in the neck. In the event that such an operation should give inadequate relief they recommended additional section of the posterior divisions of the fourth cervical to the seventh cervical nerves in the neck. In those cases in which the dystonia involved the muscles of the back or arms they suggested that anterior cordotomy might improve the condition.

Unsatisfactory experiences with conservative measures in the treatment of spasmodic torticollis at the Cleveland Clinic have led to the adoption of intradural section of the anterior cervical nerve roots and section of the spinal accessory nerve in the neck as the operation of choice. With the patient in the upright position under general anesthesia, a complete laminectomy of the first two cervical vertebrae is performed, and the anterior roots of the first three cervical nerves on both sides are divided between silver clips. In order to obtain adequate exposure of the third cervical nerve roots, it is advisable to remove also a portion of the upper margin of the lamina of the third cervical vertebra. Section of the posterior sensory nerve roots is not necessary. The

fourth cervical nerve roots must be left intact in order to avoid possible difficulty in swallowing and respiration. In our experience it has not been necessary to fix the head and neck in plaster after this procedure. About one week after the rhizotomy, an incision is made along the anterior border of the sternomastoid muscle which has been in spasm, and the spinal accessory nerve is identified as it enters the muscle and is resected and ligated. The latter procedure may be carried out first if so desired, but in the writer's experience section of the spinal accessory nerve alone has not given satisfactory relief, and it has always been necessary to divide the first three cervical anterior nerve roots as well. In one instance (case 5) rhizotomy alone succeeded in giving complete relief, and spinal accessory nerve section was not necessary. In the other cases the combined operation was required for adequate relief. In no case was section of both spinal accessory nerves required.

Case Reports

The following brief case reports illustrate indications for operation and the results obtained.

Case 1. A woman, aged 27, complained that five months previously her head had jerked slightly to the left several times within an hour. Three months later "something gave" in the back of the neck, and her head turned to the left and remained there. She tried head traction, chiropractic treatments, diathermy, massage, triple bromides, and benzedrine, without relief. Intradural section of the upper three cervical anterior nerve roots was performed on November 12, 1937, and the right spinal accessory nerve in the neck was divided two weeks later. Since then there has been no more spasm of the neck muscles, and the patient has been able to do her housework and care for her child. The motions of her head are quite limited, and there is some asymmetry of the neck due to the unilateral atrophy of the right sternomastoid and trapezius muscles. When last seen on November 21, 1946, she was nervous but in good general health and working steadily.

Case 2. A man, a clerk, aged 42, for twenty-three years had noticed a tired aching sensation in the back of the neck which was gradually increasing. Four years prior to admission his head had begun to turn to the left involuntarily and had developed irregular jerking movements in that direction. Chiropractic and osteopathic treatments, physical therapy, and saline injections failed to give relief. Examination showed spasmodic contractions of the right sternomastoid muscle with the head rotated to the left and the chin elevated. Bilateral section of the first three cervical anterior nerve roots was performed on October 14, 1938, and ten days later the right spinal accessory nerve was divided in the neck. Since then there has been no more jerking of the head, but the patient has continued to have a very fine tremor of the head and hands. In 1945 the left spinal accessory nerve was divided in the neck at another clinic in an effort to relieve the fine tremor of the head and hands. When last seen at the Cleveland Clinic on November 25, 1947, the patient was well and working, without his former violent head movements, but still exhibiting a fine tremor of the head and of the right hand.

Case 3. (Fig. 1) A woman, aged 39, complained that eighteen years previously while operating a comptometer her head had begun to turn involuntarily to the right. This condition had become worse and uncontrollable through the years. The patient was very nervous. Examination showed spasmodic contractions of the left sternomastoid, and the head was turned to the right. Bilateral anterior rhizotomy of the first three cervical nerves was carried out on April 29, 1940, and the left spinal accessory nerve in the neck was divided on May 8, 1940. She had no more violent jerking movements of the head after operation, but she continued to be generally nervous and when last seen at the Clinic on January 7, 1948,

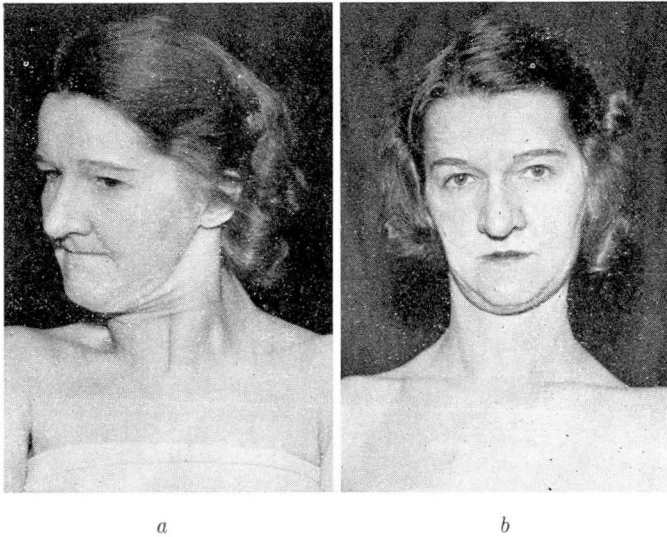


FIG. 1. Case 3. Spasmotic torticollis. (a) Before operation. (b) After operation.

still exhibited a slight head tremor and atrophy of the left sternomastoid and trapezius. She was working steadily.

Case 4. A man, a cook and meat-cutter, aged 52, eight months previously had noticed a burning sensation over the lower part of the right sternomastoid. Soon thereafter his head began to jerk spasmodically to the right, and the neck "cracked" and ached. The condition became steadily worse and failed to respond to manipulation, heat, massage, or medicine. Examination showed a nervous man with spasmodic jerking of the head to the right. There was also some apparent involvement of the muscles of expression in the face. Sedatives, heat, and massage had failed to produce relief. On November 16, 1945, the left spinal accessory nerve was divided, and one week later bilateral section of the anterior roots of the first three cervical nerves was carried out. One year later the patient was reported to be well and having no jerking of the head. He was steadily employed and able to enjoy fishing and hunting.

Case 5. (Fig. 2) A recently discharged soldier, aged 26, had noted a gradually progressive contraction of the neck muscles with turning of the head to the left side over a period of six months. He was able to replace his head in normal position with his hand, and while lying down or standing with his head against a wall he could control its movement in any direction. The disorder prevented him from working. A neck brace, psychiatric treatment, medication, chiropractic and osteopathic manipulations had not given relief. Examination showed the head tilted and turned to the left without spasm of the sternomastoids. Bilateral anterior rhizotomy of the first three cervical nerves was performed on December 5, 1946, producing complete relief so that it was not necessary to divide the spinal accessory nerve. When last seen ten months later the patient was comfortable, free from head tilt or neck spasm, and working steadily. There was a good range of motion in the neck.

In none of the cases discussed was there any obtainable history of severe injury to the head or neck, encephalitis, meningitis, or any specific emotional upset. The first 4 patients might be termed "high-strung" or "nervous." Roentgenologic examination of the cervical region of the spine in each patient failed to reveal any significant abnormal changes in the bones or joints which might help to explain the origin of the condition. The occupation of 1 patient

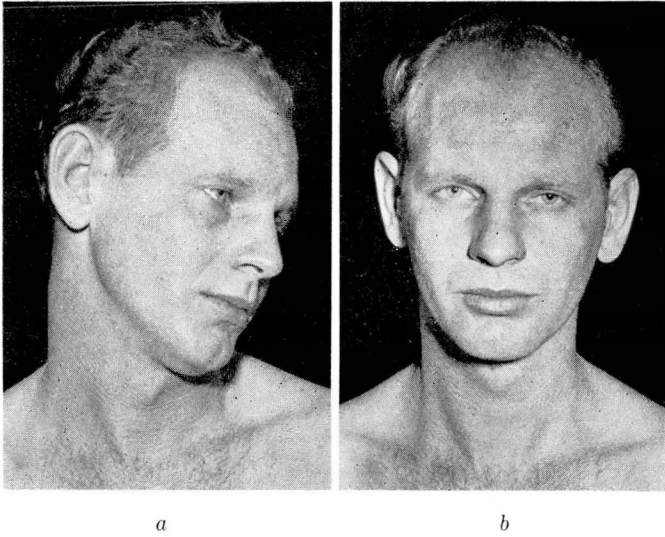


FIG. 2. Case 5. Spasmodic torticollis. (a) Before operation. (b) After operation.

(case 3), a comptometer operator, might be considered of some etiologic importance, inasmuch as her work required frequently repeated rotation of the head for several years. It is conceivable that a habit pattern might have been established by such motion.

By means of the operation described, satisfactory results have been obtained. Immobilization in plaster after operation or fixation with bone graft have not been found necessary (probably due to the fact that only one spinal accessory nerve is divided). The period of hospitalization is approximately three weeks. Untoward complications have yet to be encountered, and each of these patients has been able to return to useful work.

A certain asymmetry in the appearance of the head and neck is unavoidable because of unilateral atrophy of the sternomastoid and trapezius muscles as a result of section of one spinal accessory nerve. A fine tremor of the head may persist in some cases after operation, and there is usually some limitation of rotation of the head toward the side opposite that of the divided spinal accessory nerve. In spite of these minor sequelae, the morale and economic usefulness of the patient are greatly improved by relief from the former violent spasmodic jerking movements of the head.

References

1. Patterson, R. M., and Little, S. C.: Spasmodic torticollis. *J. Nerv. and Ment. Dis.* **98**:571-599 (Dec.) 1943.
2. Rugh, J. T.: Spasmodic torticollis; its cause and treatment. *Am. J. Surg.* **49**:490-495 (Sept.) 1940.
3. Kennedy, R. J.: Ocular torticollis. *Cleveland Clin. Quart.* **13**:163-165 (July) 1946.
4. Alpers, B. J., and Drayer, C. S.: Organic background of some cases of spasmodic torticollis. Report of case with autopsy. *Am. J. M. Sc.* **193**:378-384 (March) 1937.

5. Rand, C. W.: *The Neurosurgical Patient: His Problems of Diagnosis and Care* (Springfield: Charles C Thomas, 1944) p. 500.
6. Brissaud, E.: *Lecons sur les Maladies Nerveuses* (Paris: G. Masson, 1895) pp. 512-520.
7. De Morgan, C.: Case of excision of a part of the spinal accessory nerve for spasmodic wry neck. *Brit. and For. M.-Chir. Rev.* **38**:218 (July) 1866.
8. Keen, W. W.: A new operation for spasmodic wry neck: namely, division or exsection of the nerves supplying the posterior rotator muscles of the head. *Ann. Surg.* **13**:44, 1891.
9. Taylor, A. S.: Operations on the peripheral and cranial nerves. In *Unilateral Laminectomy in Operative Therapeutics*, edited by Johnson, A. B. (New York: D. Appleton and Company, 1915) p. 525.
10. Foerster, O.: On indications and results of excision of posterior spinal nerve roots in man. *Surg., Gynec. and Obst.* **16**:463-474, 1913.
11. McKenzie, K. G.: Intrameningeal division of the spinal accessory and roots of the upper cervical nerves for the treatment of spasmodic torticollis. *Surg., Gynec. and Obst.* **39**:5-10 (July) 1924.
12. Finney, J. M. T., and Hughson, W., Spasmodic torticollis. *Ann. Surg.* **81**:255-269 (Jan.) 1925.
13. Dandy, W. E.: Operation for treatment of spasmodic torticollis. *Arch. Surg.* **20**:1021-1032 (June) 1930.
14. Adson, A. W., Young, H. H., and Ghormley, R. K.: Spasmodic torticollis; severe organic type treated by combined operation, rhizotomy and fusion. *J. Bone and Joint Surg.* **28**:299-308 (April) 1946.
15. Putnam, T. J.; and Herz, E.: Treatment of spasmodic torticollis, report of 2 cases. *Arch. Neurol. and Psychiat.* **57**:260 (Feb.) 1947.