

# DERMATITIS MEDICAMENTOSA

## *Report of a Case Probably Caused by Propylthiouracil*

GEORGE H. CURTIS, M.D.

Department of Dermatology

In a relatively small number of cases treated with 6-n-propylthiouracil, few toxic reactions have been reported. Reveno<sup>1</sup> reported 1 case of drug fever. McGavack *et al.*<sup>2</sup> reported, from over 100 cases treated, 1 case in which drug fever and urticaria were reproduced by propylthiouracil five weeks after withdrawal of thiouracil. McCullagh<sup>3</sup> has observed toxic reactions in only 3 of over 250 cases treated; 1 patient had drug fever, another had urticaria, and a third, the subject of this report, has had a severe dermatitis.

### Case Report

A man, a Jewish grocer, aged 34, was admitted to the Clinic on August 8, 1945, for continuation of treatment for hyperthyroidism. He had been under medical observation since June, 1943, and although he had led an active life had presented no evidence of thyrotoxicosis until shortly after rejection for military service. In May, 1945, the basal metabolic rate was plus 56 per cent and the blood cholesterol 123 mg. per 100 cc. Thiouracil controlled the thyrotoxicosis.

The family history and past personal history were negative for allergic, cutaneous, and systemic diseases.

Physical examination revealed a well-developed, well-nourished man weighing 74.5 kg. The thyroid gland was diffusely enlarged, but no bruit was heard. The blood pressure was 112 systolic and 70 diastolic. There was moderate over-activity of movements, a moderate exophthalmos, and slight lid lag. Basal metabolic rate was plus 21 per cent. The hemogram, urinalysis, and blood sugar were within normal limits. The blood Wassermann and Kahn reactions were negative.

**Clinical Course.** From May to December, 1945, the thyrotoxicosis was controlled by thiouracil, which was discontinued in December. In February, 1945, the basal metabolic rate was plus 26 per cent, and it was decided to administer iodine for one month and to perform a thyroidectomy. However, various war-time factors, in addition to decided improvement of the patient, led to postponement of the operation. In March, 1946, the basal metabolic rate was minus 9 per cent, and it was thought that a permanent remission might be obtained by administration of propylthiouracil and iodine. Doses of 50 mg. of propylthiouracil and 10 mg. of iodine as steardine were administered daily. The steardine was discontinued in May, 1946, but propylthiouracil was continued up to December 17, 1946, at which time the basal metabolic rate was plus 27 per cent. An improvement in the exophthalmos and eye muscles was noted.

On December 3, 1946, the patient was referred to the Department of Dermatology because of an itching eruption that had occurred two weeks previously. The eruption consisted of dull red, fairly well-demarcated, thickened and lichenified plaques on the neck and trunk, arms, thighs, and ankles. Moist, red, and scaling discoid lesions involved

the glans penis and scrotum. Numerous pinhead to pea-size papules, the larger ones being infiltrated and nodular, were diffusely distributed over the extremities. Many were flat with a wax-like surface. The color varied from dull red to brownish red. There were slightly raised, ill-defined macular lesions on the face. There were no lesions on the mucous membranes. The eruption was intensely pruritic, and the patient vigorously scratched himself during the dermatologic examination. The itching also interfered with his sleep.

A pea-sized papule from the volar surface of a forearm was excised for microscopic examination. There was acanthosis with slight downgrowth of the rete pegs, and spotty parakeratosis. Edema and a slight lymphocytic infiltration was present in some of the papillae, but there was no liquefaction necrosis. In the upper corium the blood vessels were dilated and surrounded by mild edema and a dense perivascular infiltrate consisting of lymphocytes and a rare polymorphonuclear leukocyte and plasma cell. The intima of the blood vessels appeared swollen, but at no place were there obliterative changes. Except for a slight perivascular lymphocytic infiltrate in the midcorium there were no significant changes in the deeper layers.

During the following two weeks the dermatitis became more severe and extensive, involving the soles and palms, the eyes, producing blepharitis and conjunctivitis, and the scalp, causing scaling and diffuse partial loss of hair. On December 17, 1946, the propylthiouracil was discontinued, and on December 26 the patient was admitted to the hospital. The dermatitis rapidly subsided, and he was discharged in January, 1947. He re-entered the hospital in February, 1947, with a severe exacerbation of symptoms. There were numerous dull red, oval, and well-demarcated macular lesions and plaques varying from lima-bean to fifty-cent-piece size on the trunk and extremities. The macules rapidly enlarged to form elevated discoid lesions. Still larger thickened lesions on the neck, arms, and thighs became moist and oozed, with formation of scaly crusts. The former lesions on the genitalia recurred and oozed. Ill-defined areas of lichenoid follicular lesions were present on the abdomen and dorsolumbar regions. Itching was intense during the night. A shower of urticarial lesions suddenly appeared, then subsided in four or five days. The cause of the urticaria could not be determined. The axillary, epitrochlear, and inguinal lymph nodes became enlarged.

One of the discoid plaques on the abdomen was excised for microscopic examination which showed considerable acanthosis and marked downgrowth of the rete pegs. Just beneath the horny layer were numerous vesicles containing fluid and a few lymphocytes and polymorphonuclear leukocytes. The horny layer over the vesicles showed parakeratosis. The elongated papillae were edematous and mildly infiltrated with lymphocytes and a few plasma cells. Although there was some invasion of the epiderm by a small number of lymphocytes, there was no liquefaction necrosis. The blood vessels in the upper corium were dilated and surrounded by edema and a dense perivascular infiltrate. Lymphocytes predominated the infiltrate, but the number of plasma cells was conspicuous. Plasma cells were scattered in the upper corium but were more numerous in the perivascular infiltrate. Except for a mild perivascular infiltrate that also contained plasma cells in the midcorium, the deeper layers showed no significant changes.

One of the inguinal lymph nodes was excised for histologic examination but showed only chronic and nonspecific inflammatory changes.

The dermatitis continued to be severe and, although a subtotal thyroidectomy was done\* on March 25, 1947, the symptoms did not abate. The pruritus could not be controlled by ordinary sedation, and for five days procaine (0.5 per cent) was administered

\* Operation was performed by Dr. George Crile, Jr.

intravenously, producing temporary relief. About April 1, 1947, the dermatitis began to subside slowly, and by April 26, when the patient was discharged from the hospital, it had receded about 75 per cent.

During May, June, and July, 1947, the dermatosis fluctuated with exacerbations and partial remission. The exacerbations were characterized by the appearance of macules that developed into discoid plaques, some of which oozed, and the lichenoid follicular lesions on the trunk.

Throughout the second hospitalization period and subsequent months the clinical course and appearance of the dermatosis closely paralleled that of the exudative discoid and lichenoid chronic dermatosis described by Sulzberger and Garbe.<sup>4</sup> By June, 1947, the eruption had slowly progressed. Accordingly, sodium arsenate in increasing doses of a daily increment of 0.1 cc. was injected subcutaneously. By July 21 the dermatitis had become so extensive that a series of roentgen irradiation treatments to the cutaneous surfaces was given, and the sodium arsenate was discontinued. On July 21, 28, and August 4, 1947, doses of 75 r of superficial unfiltered irradiation were administered. At the time of the third treatment the dermatosis had vanished.

A third biopsy of one of the discoid lesions showed only quantitative changes compared to the second described above (fig. 1a). There were (1) sparse intra-epidermal vesicles and (2) an increased number of plasma cells in the perivascular infiltrates of the upper and midcorium (fig. 1b). There were no changes detected in the reticulum, elastic

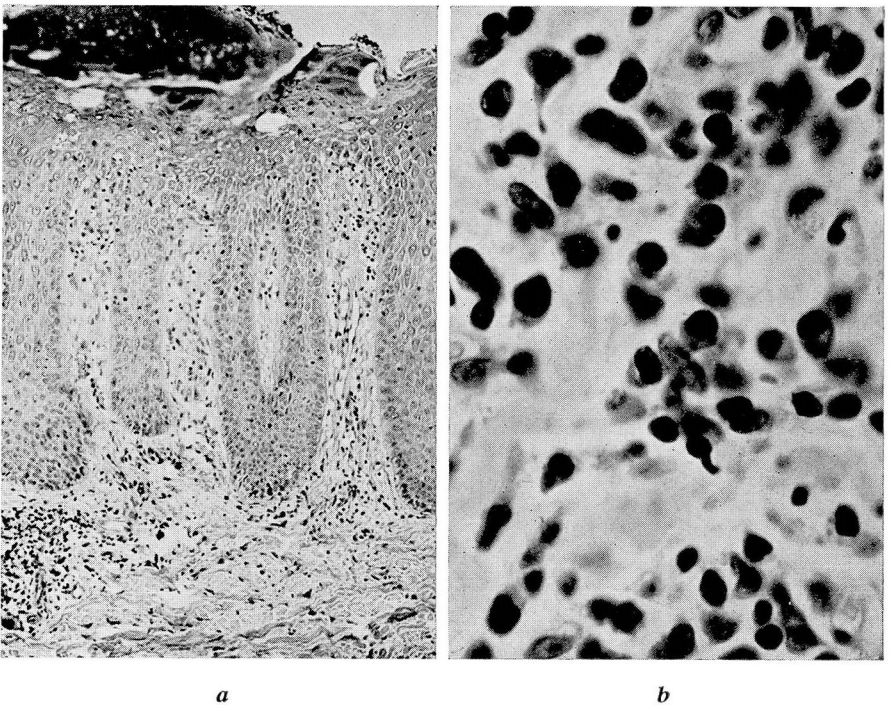


FIG. 1. (a) Low power. Third biopsy of a discoid lesion.  
(b) Note plasma cells in perivascular infiltrate. From lower left hand corner of a. (x800).

fibers, nor collagen in the three specimens. A patch test with propylthiouracil showed no reaction at the end of forty-eight hours, seventy-two hours, and one week.

### Discussion

The factors indicating the probability that the dermatosis in this case was a drug eruption are: (1) The patient had been taking propylthiouracil up to and subsequent to the time of onset, and the drug is now known to produce skin eruptions; (2) The eruption at first was morphologically similar to the lichen planus type of drug eruptions; (3) The progress and subsidence was rapid during the first month of its course; (4) The dermatitis involved the scalp and resulted in considerable loss of hair. A negative patch test does not militate against a drug eruption, since negative patch tests with offending drugs are the usual findings in drug eruptions. However, the ultimate proof lies in the reaction to readministration of propylthiouracil in order to reproduce the dermatitis. This procedure will not be carried out in this case because it is considered unwise in view of the severity and long course of the dermatosis, and the patient is reluctant to submit to a trial of the drug since his recovery from the thyrotoxicosis.

The diagnoses of lichen planus, seborrheic dermatitis, neurodermatitis, atopic dermatitis, and the atypical syndrome due to quina-craine hydrochloride were eliminated by the clinical course and histopathology of the eruption. Other dermatoses, including those of the lymphoblastoma group, are considered unlikely in this case in view of repeated negative results of appropriate laboratory investigations. Repeated examination of the urine for arsenic gave negative results, thus contraindicating an arsenical dermatitis.

The clinical course, morphology, and histopathology of the dermatitis simulates the syndrome of Sulzberger and Garbe.<sup>4</sup>

1. The patient is a Jew in the fourth decade of life.
2. The dermatitis had its onset as a generalized eruption and involved the soles.
3. Practically all of the various types of lesions described by Sulzberger and Garbe have appeared in this case.
  - a. A shower of urticarial lesions
  - b. Lichenoid follicular lesions in ill-defined areas on the trunk and extremities
  - c. Discoid lesions originating as macules that enlarged and became infiltrated, and oozing eczematoid plaques on the genitalia, trunk, and shoulder girdles
  - d. Tendency of the lesions to be remittent



4. Laboratory investigations have shown no abnormal changes except for the white blood cell counts that have varied up to 11,000 with 5 to 18 per cent eosinophilia.

5. Pruritus was intractable and was accompanied by chilly sensations.

6. The dermatitis has been chronic and remittent.

7. The course of the histopathologic development of the dermatitis coincides with that described by Sachs and Kirsch<sup>5</sup> as characteristic of the disease.

8. The eruption proved refractory to all forms of treatment until the combination of sodium arsenate and roentgen irradiation<sup>6</sup> was followed by a rapid subsidence of cutaneous lesions.

There are several points of difference between the two dermatoses. I have not been able to find mention in cases of the Sulzberger-Garbe syndrome of involvement of the conjunctivae, palms, and scalp with alopecia. In a photograph shown in Pascher's article<sup>6</sup> there is a suggestion of blepharitis, which occurred in this case. The cause of the Sulzberger-Garbe syndrome is unknown. Various investigative findings, such as pyogenic infections, contact allergens, and allergic investigations with positive intracutaneous tests have been considered as contributing factors. No conclusions have been reached. Sulzberger and Garbe thoroughly investigated drugs as a possible cause but were unable to draw conclusions. The principal point of difference is the fact that my patient had been taking propylthiouracil when the dermatitis originated. In spite of these differences I believe this case may be included among those of the Sulzberger-Garbe syndrome and that drugs, among other etiologic factors, should be carefully investigated as a possible cause in cases simulating the Sulzberger-Garbe syndrome.

### Summary

A dermatosis which occurred during administration of 6-n-propylthiouracil is described. The morphology of the eruption, its clinical course, and histopathology were observed over a nine-month period, simulating the exudative discoid and lichenoid chronic dermatosis described by Sulzberger and Garbe. It is believed that this case may be included among those having the Sulzberger-Garbe syndrome. Since the origin of the syndrome is unknown and propylthiouracil may have been the cause in this case, it is suggested that drugs or other chemicals be considered in the etiology of cases resembling the Sulzberger-Garbe syndrome.

### References

1. Reveno, W. S.: Propylthiouracil in thyrotoxicosis; observations on 54 patients. *J.A.M.A.* **133**:1190-1192 (April 19) 1947.
2. McGavack, T. H., Gerl, A. J., Vogel, M., and Schutzer, S.: Clinical comparison of effectiveness of 6-n-propylthiouracil and 2-thiouracil as antithyrototoxic agents. *Am. J. Med.* **2**:144-149 (Feb.) 1947.
3. McCullagh, E. P.: Personal communication.
4. Sulzberger, M. B., and Garbe, W.: Nine cases of distinctive exudative discoid and lichenoid chronic dermatosis. *Arch. Dermat. & Syph.* **36**:247-272 (Aug.) 1937.
5. Sachs, W., and Kirsch, N.: Exudative discoid and lichenoid chronic dermatosis (Sulzberger and Garbe). Histopathologic study. *J. Invest. Dermat.* **8**:215-221, 1947.
6. Pascher, F.: Exudative chronic discoid and lichenoid dermatitis. (Sulzberger-Garbe) Treatment of 5 patients. *Arch. Dermat. & Syph.* **42**:322-332 (Aug.) 1940.