

VOLVULUS OF THE STOMACH

Report of 3 Cases

A. H. ROBNETT, M.D., and T. E. JONES, M.D.

Division of Surgery

Gastric obstruction due to volvulus of the stomach is an uncommon condition first described in 1866 by Berti¹ as an autopsy finding. In 1897 the condition was recognized by Berg² at operation. Subsequent individual case reports have been summarized, and a diagnostic clinical picture has evolved.^{3,4}

The cases are classified on the basis of pathology as (1) *idiopathic*, without associated organic lesion, and (2) *complex*, with associated organic lesion. The term total volvulus is applied to those cases in which there exists a minimum of 180 degrees rotation with complete obstruction. Partial volvulus designates those cases with less than 180 degrees rotation and, as a rule, incomplete obstruction.

Kocher⁵ first distinguished the two types of rotation anatomically. The least common of these is the volvulus mesenterio-axial type, in which the axis of rotation is at right angles to the cardiopyloric line. The pylorus rotates anteriorly and to the left of the midline, causing acute kinking of the anterior wall of the stomach on itself and thus obstruction (fig. 1).

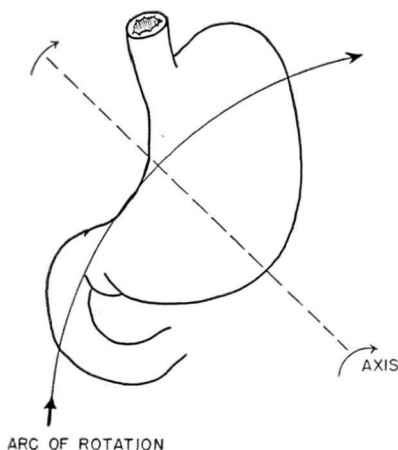


FIG. 1. Volvulus mesenterio-axial type.

More common is the volvulus organo-axial type, in which the axis of rotation passes through the cardiac and the pyloric orifices. The greater curvature may rotate anteriorly or posteriorly, coming to lie superior to the lesser curvature, and, depending on the degree of rotation, resulting in total or partial volvulus (fig. 2). As a result of this rotation the transverse colon may be carried superiorly and become obstructed.⁴ It is interesting to note that the blood vessels have rarely been found strangulated, despite extreme rotation.⁵

The stomach is normally suspended by the esophagus and the gastrophrenic ligament above and by the peritoneum covering the second portion of the duodenum below. Mobility between these two points is controlled by the length of the lesser curvature and by the length and integrity of the gastrohepatic and gastrocolic omenta.⁶

Deficiency or excessive length of the gastrohepatic ligaments associated with ptosis permits an uncontrolled mobility of the stomach between the points of suspension, predisposing to the ideopathic volvulus.

Complex volvulus, designating that type of volvulus associated with other pathology, has been described as a complication of trauma, left phrenicotomy, diaphragmatic hernia, gastric ulcer, tumor of the stomach, hour glass stomach, perigastritis, and perigastric adhesions.^{3,4,7}

DaCosta⁸ estimates that one-third of the cases of volvulus of the stomach are associated with diaphragmatic hernia, and Payer reports⁹ an incidence of 2 per cent in 500 cases of diaphragmatic hernia. Vorhaus

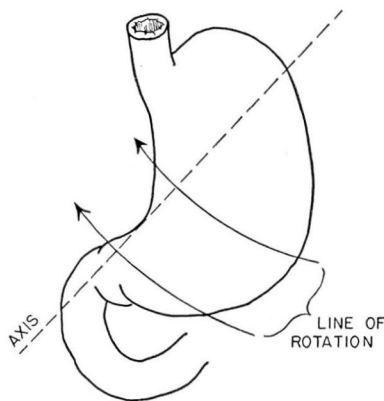


FIG. 2. Volvulus organo-axial type.

and Stetten¹⁰ in 1944 reported a case of volvulus complicating diaphragmatic hernia in a patient whom they believed to be the first to recover after operation.

The clinical picture of total volvulus of the stomach begins most often with acute oppressive pain in the upper abdomen following injury, emotional upset, or a heavy meal. Vomiting occurs, followed soon by nonproductive retching. Distention of the upper region of the abdomen is marked and cannot be relieved by passage of a stomach tube.¹¹

Partial volvulus presents a picture of recurrent epigastric oppression, vomiting, nonproductive retching, and meteorism of the upper abdomen. It may be relieved by passage of a stomach tube with decompression of the proximal portion of the distended stomach. With the influences of sedation and anti-spasmodics, relaxation of the stomach and resolution of the volvulus may also occur. The severity of these attacks is such that the patient, fearing recurrence, eats in small quantities, and weight loss occurs.

The condition is recognized roentgenologically by various combinations of the following findings:⁹ double fluid level in the stomach, inverted stomach, greater curvature above the lesser curvature, twisting of the stomach with narrowing in the region of the twist, alteration in direction of mucosal folds, high transverse gas bubble on both sides of the midline, cascade or hour glass stomach.

At Cleveland Clinic Hospital, 3 patients with volvulus of the stomach have been operated upon by Dr. T. E. Jones.

Case Reports

Case 1. A woman, aged 48, was admitted to the hospital in May, 1936, with a history of severe upper abdominal pain, vomiting of twenty-four hours' duration, and increasing abdominal distention. Narcotics had been given with transitory relief. Physical examination revealed a symmetrically distended tympanitic abdomen with no rigidity and no peristaltic sounds. Flat film of the abdomen obtained at admission revealed marked dilatation of the stomach. Laboratory studies did not contribute to the diagnosis. Gastric suction was successfully instituted, and in four days the patient was asymptomatic and retained a liquid diet. Gastrointestinal series during the asymptomatic period revealed the stomach larger than normal, with 10 per cent retention at the end of four hours and no other apparent abnormality. The patient was discharged seven days later with the diagnosis of pylorospasm.

During the intervening years between 1936 and the last admission in July, 1947, the patient experienced repeated episodes of upper abdominal pain, distention, nausea, and vomiting. Relief was obtained with bed rest, phenobarbital, and tincture of belladonna. She was admitted to the hospital on three occasions with persistent acute distention and vomiting but after gastric suction rapidly returned to normal. On several occasions a GI series revealed an enlarged stomach, degrees of gastric retention up to 10 per cent, and dilatation of the large bowel. However, in 1942, following an acute episode which had been relieved by gastric suction, the following x-ray report was made:

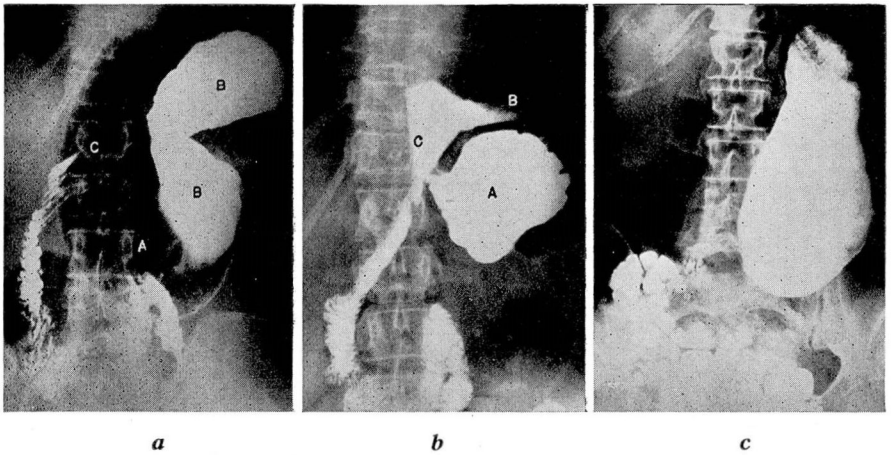


FIG. 3. Case 1. Roentgenograms demonstrating
(a) A. cardia of stomach, B. pars media, C. duodenal bulb.
(b) After manipulation; A. cardia, B. pars media, C. duodenal bulb.
(c) Dilated atonic stomach, no volvulus present.

(fig. 3) "The stomach and duodenum show no definite organic lesion, but the cardiac portion is depressed and the pars media and pars pylorica elevated and apparently rotated in such a way that the greater curvature is above the lesser curvature. The distal pars pylorica and the first portion of the duodenum are therefore somewhat stretched. The stomach empties readily when the patient is turned on her abdomen, and there is about 15% gastric retention in 5 hours, all of the barium being retained in the redundant cardiac portion." Roentgenographic examination two days later showed "dilation of stomach, but normal position with 2% gastric retention in four hours."

In July, 1947, at the age of 59, the patient was hospitalized following another GI series. Torsion of a ptosed stomach was suspected, and she was subjected to exploratory laparotomy. The operative findings are summarized as follows: The stomach was atonic, long, and lay in a normal position with no evidence of torsion. The gastrohepatic omentum was greatly attenuated and elongated, with a large rent extending from the under surface of the liver to the lesser curvature. The middle third of the gastrocolic ligament was also absent. Volvulus of the stomach, as demonstrated by x-ray study in 1942, was reproduced by rotating the greater curvature through the gastrohepatic ligament and then posteriorly, thus rotating and obstructing the first portion of the duodenum. No other pathology was present. The defects in the gastrohepatic and gastrocolic omenta were closed.

Convalescence was uneventful, and the patient was discharged free of symptoms.

Analysis. This case exemplifies idiopathic partial volvulus organo-axialis with gastropnoxis and deficient gastrohepatic and gastrocolic ligaments, resulting in partial obstruction.

Case 2. A man, aged 69, entered Cleveland Clinic Hospital in July, 1947. Fourteen days prior to admission he had developed severe upper transabdominal pain, vomiting, and distention of the abdomen, described by his physician as a "tender, tense left hypochondrial mass disappearing under the costal margin". For ten days prior to admission

VOLVULUS OF THE STOMACH

he was hospitalized elsewhere and treated with continuous gastric suction, affording partial decompression and relief of symptoms. Prompt recurrence followed interruption of gastric suction. Previous x-ray reports described "rotation of stomach on axis so that the greater curvature was above and the lesser curvature below" (fig. 4).

On admission of the patient to Cleveland Clinic Hospital, the following additional pertinent history was obtained. For years the patient had occasionally noted fullness and discomfort in the abdomen when lying down, relief being obtained by belching, walking, or the use of alkalis or paregoric. He stated that routine studies made several years previously had revealed a diaphragmatic hernia, but this condition was unconfirmed on subsequent studies. During the past year there had been increasingly severe and frequent attacks of upper abdominal cramping pain, passing from right to left. The episodes were most frequent after a large meal. The patient had lost 30 pounds in weight in the past year. Pertinent physical findings at the time of admission were confined to the abdomen, which was slightly tympanitic, with active peristalsis. Examination of the chest revealed no abnormal findings. Laboratory studies except for moderate anemia showed no abnormality.

Roentgenograms of the chest revealed a large air bubble behind the apex of the heart and a visible fluid level. Exploratory laparotomy was performed, and the operative findings are summarized: The abdomen was entered through an upper midline incision. The stomach was not visible within the abdominal cavity. Gentle traction at the esophageal hiatus delivered a large, pale, atonic stomach from the thoracic cavity. The middle third of the gastrocolic omentum was absent, and the greater curvature rotated posteriorly and then superiorly, producing a complete torsion. Changes indicative of embarrassed blood supply and early strangulation were noted on the greater curvature

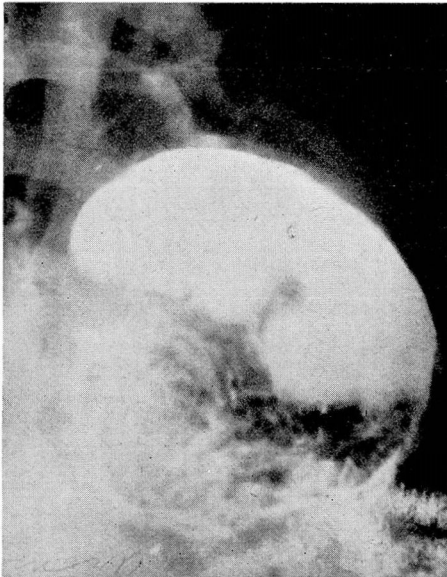


FIG 4. Case 2. Volvulus. Pars pylorica filled with barium and lying superior to stomach. At operation entire stomach with volvulus found within thorax.

at the point of torsion. The rotation was corrected, the defect in the gastrocolic omentum was closed with chromic catgut, and the 2½-inch esophageal hiatus was repaired with interrupted black silk sutures.

Convalescence was uneventful, and the patient was free of symptoms upon discharge.

Analysis. This case is an example of diaphragmatic hernia complicated by total complex organo-axial volvulus of the stomach with obstruction.

Case 3. A white woman, aged 52, was admitted complaining of inability to eat because of a sensation of fullness of the stomach and attacks of abdominal pain accompanied by nausea and vomiting over a five-year period.

Physical examination revealed no significant abnormality other than tenderness over the left upper quadrant.

Roentgenograms taken elsewhere demonstrated the mid-portion of the stomach fixed in a diaphragmatic hernia, with the cardia lower on the left and the pylorus on the right.

The operative findings are summarized as follows: The proximal half of the stomach was greatly dilated and rotated clockwise 180 degrees. A segment measuring approximately 2 inches in diameter on the anterior surface of the stomach at the greater curvature was strangulated within a hiatus hernia to the left of the esophagus. The hernia was reduced and the defect at the hiatus repaired with interrupted black silk sutures. Convalescence was uneventful, and the patient was free of symptoms at the time of discharge.

Analysis. This case exemplifies diaphragmatic hernia complicated by complex partial organo-axial volvulus of the stomach.

Conclusions

1. Three patients with volvulus of the stomach have been operated upon within the past eighteen months. Two of these cases are of the complex organo-axial type complicating diaphragmatic hernia, while the third case is of the idiopathic organo-axial type with gastropnoxis and congenital deficiency of the gastrohepatic omentum and gastrocolic omentum.
2. The findings and symptoms of upper abdominal pain, upper abdominal distention, nausea, and vomiting have been present in all 3 cases. In 2 of the 3 cases symptomatic relief was obtained by gastric suction, and in the third case obstruction was not present.
3. Conclusive preoperative diagnosis was possible in all cases by roentgen study.
4. All patients were discharged symptom-free following operation.

REFERENCES

1. Berti, cited by Bockus, H. L.: *Gastro-Enterology*. 1. The Esophagus and Stomach: Examination of the Patient, and Diagnosis and Treatment of the Disorders of the Esophagus and Stomach, Including Duodenal Ulcer. (Philadelphia: W. B. Saunders Co., 1943) p. 785.
2. Berg, cited by Bockus, H. L. p. 785.
3. Bockus, H. L. p. 785.
4. Babcock, W. W.: *A Textbook of Surgery for Students and Physicians*, ed. 2 (Philadelphia: W. B. Saunders Co., 1935) p. 967.
5. Kocher, cited by Buchanan, J.: Volvulus of stomach. *Brit. J. Surg.* 18:99-112 (July) 1930.
6. Singleton, A. C.: Chronic gastric volvulus. *Radiology* 34:53-61 (Jan.) 1940.
7. Rose, B. T.: Volvulus of stomach. *Brit. J. Surg.* 33:93-94, 1946.
8. DaCosta, J. C.: *Modern Surgery, General and Operative*. Assisted by Benjamin Lipshutz, ed. 10 (Philadelphia: W. B. Saunders Co., 1931) p. 785.
9. Payer, A., cited by Feldman, M.: *Clinical Roentgenology of the Digestive Tract*, ed. 2 (Baltimore: W. Wood & Co., 1938) p. 240.
10. Vorhaus, M. G., and Stetten, DeW.: Volvulus and incarceration of stomach in diaphragmatic hernias with complete acute gastric obstruction, operative recovery with obliteration of hernial sac by the tamponade. *Gastroenterology* 2:307-315 (May) 1944.
11. Thorek, M.: Acute total volvulus of stomach. *J.A.M.A.* 81:636-640 (Aug. 25) 1923.