

SUBDIAPHRAGMATIC VAGOTOMY; INDICATIONS AND TECHNIC

GEORGE CRILE, Jr., M.D.

Division of Surgery

The principle of vagotomy as described by Dragstedt¹ has been widely accepted in the treatment of peptic ulcer, and the results up to the present time have been satisfactory. During the past year 50 vagotomies have been performed at Cleveland Clinic Hospital, 6 of these through the thorax and the remainder through the abdomen. With increasing experience the subdiaphragmatic approach has become the procedure of choice and has been used exclusively in the last 27 cases.

In a few (7) of the earlier cases only the anterior vagus was sectioned, but more recently both vagi have been severed below the diaphragm, either as the sole surgical treatment of peptic ulcer or more often in conjunction with some gastric operation. At first we did not feel justified in relying too much on vagotomy alone, and in many cases, in order to afford added protection against recurrent ulceration, gastric resection was performed along with vagotomy.

In some cases in which resection would have been difficult or dangerous gastroenterostomy was employed. The excellent immediate results obtained by vagotomy and a conservative gastric operation encouraged us to resect fewer stomachs. Recently I have employed pyloroplasty more often than gastroenterostomy in conjunction with vagotomy (table).

Pyloroplasty is the simplest and safest of all the surgical procedures used in the treatment of ulcer. When employed alone its results were not too encouraging, but when pyloroplasty is combined with vagotomy the immediate results in a small group of cases have been excellent. In many instances pyloroplasty is the easiest means of assuring protection against the development of gastric retention following vagotomy for duodenal ulcer.

Subdiaphragmatic vagotomy has supplanted the transthoracic approach because (1) the abdominal approach allows examination of the ulcer and concomitant abdominal pathosis such as gall stones or hiatus hernia; (2) the abdominal approach enables the surgeon simultaneously to perform some type of operation such as gastroenterostomy or pyloroplasty so that the hypomotility resulting from vagotomy will not result in gastric retention; (3) the abdominal approach is probably safer than the transthoracic; (4) the scar left by the abdominal incision

is less troublesome than the intercostal, where neuralgia sometimes follows resection of a rib; (5) anatomic studies have shown that subdiaphragmatic vagotomy usually can be as complete and effective as transthoracic; (6) the results of subdiaphragmatic vagotomy as indicated by the clinical course of the patients are comparable to those following the transthoracic approach.

The relief of pain following vagotomy has been so prompt and complete that it has been suspected that there may be sensory fibers as well as secretory in the vagus nerve. For this reason I have on two occasions treated patients suffering from "biliary dyskinesia" or so-called "post-cholecystectomy pain" by bilateral vagotomy. Both of these patients had had severe and incapacitating biliary colic for a number of years and have been relieved for twelve and three months respectively since

Table
VAGOTOMY—50 CASES
(Total Clinic Series)

Supplementary Operation	Bilateral Subdiaphragmatic Total 37	Unilateral Subdiaphragmatic Total 7	Transthoracic Total 6
Gastroenterostomy	13	4	1
Gastric Resection	5	3	
Pyloroplasty	3		
Take Down Gastro- enterostomy	3		
Gastric Resection with Pyloric Exclusion	2		
T Tube Common Duct	2		
Cholecystectomy	1		
Repair Hiatus Hernia	1		
Cholecystectomy and Excision Ulcer	1		
No other operation	6		5

operation. A third patient who experienced severe colicky pain in the left upper quadrant has had complete relief following vagotomy but still complains of nausea and vomiting despite the fact that there is no gastric retention. There is a strong psychoneurotic element in this case. Another patient with an inoperable lymphosarcoma of the cardiac end of the stomach experienced severe ulcer-like pain after eating but was completely relieved of pain following bilateral vagotomy. Although the relief obtained in the first 3 cases can be explained on a basis of relaxation of spasm, and although it is possible that hypomotility of the stomach was a factor in the relief afforded to the last patient, it is hard to believe that the pain of a malignant tumor could be alleviated by anything but the severance of sensory pathways.

Vagotomy has had its greatest usefulness in the treatment of marginal ulcers and of ulcers in locations which render their resection dangerous or difficult. It is indeed a boon to gastric surgery to have available a safe and simple procedure which can (1) obviate the necessity of performing total or near total gastrectomies for high benign gastric ulcers, (2) avoid the difficulties involved in taking down gastroenterostomies and performing secondary resections in the treatment of marginal ulcer, and (3) dispense with the danger of injury to the pancreas or common duct or of obtaining an unsatisfactory closure of the duodenal stump during resection of large penetrating duodenal ulcers with foreshortening of the duodenum. In these cases vagotomy alone or coupled with pyloroplasty or gastroenterostomy has saved time, trouble, and probably morbidity and mortality. The diminution of mortality and morbidity has widened the scope of surgery for peptic ulcer and has led us to more frequent recommendation of surgical treatment. The mortality and morbidity of subdiaphragmatic vagotomy alone or in conjunction with a conservative gastric operation is almost certain to be lower than that of gastric resection with removal of two-thirds or more of the stomach.

In dealing with gastric ulcers vagotomy should be used only when the possibility of carcinoma has been excluded by excision or biopsy or when the location of the lesion is such that its removal would entail a greater risk than the possibility of its being malignant. Resection is still the treatment of choice for most gastric ulcers of significant size and possible malignancy.

Postoperative Course

In addition to the safety of the procedure the immediate convalescence of the patient is smoother and more comfortable than that of any comparable group of patients with ulcer treated by gastric resection

alone. Such unpleasant complications as vomiting from gastric retention, distress or feeling of fullness after meals (the so-called "dump syndrome"), and recurrent (marginal) ulceration have not yet occurred following bilateral subdiaphragmatic vagotomy. The pain is relieved from the time of operation, and the appetite is good. The patients are out of bed on the first or second postoperative day. Usually by the eighth day they are eating a liberal diet, are free of symptoms, and are able to go home.

Gastric suction is maintained for the first day or two until it is apparent that the stomach is emptying satisfactorily. In this way overdistention of the stomach is avoided. Even if a gastroenterostomy or pyloroplasty has been done there may be gastric retention, although the symptoms associated with the retention are minimal and soon subside. If no provision has been made to increase the emptying power of the stomach, retention is more apt to be observed, but if the cases in which vagotomy alone is performed are carefully selected this complication should be rare. The only patient in this series who vomited due to gastric retention had a marginal ulcer which had perforated and was closed. Subsequently, without realizing that obstruction was also present, a transthoracic vagotomy was performed. Later it was necessary to relieve the obstruction by reoperating from below. No other secondary operations have been necessary, although there have been a few patients who have had moderate prolongations of the emptying time of the stomach without experiencing any untoward symptoms and without requiring any treatment. Disturbances of the functions of the bowel have not been noted except in 1 patient who has had a persistent diarrhea.

One patient who had a huge duodenal ulcer penetrating deeply into the pancreas and who gave a history of repeated gastric hemorrhages was subjected to vagotomy and gastric resection with removal of the pyloric mucosa and closure of the pylorus proximal to the ulcer. On the fifth postoperative day before there had been time for healing to occur this patient began to bleed again and bled intermittently for two weeks, finally necessitating reoperation and suture of the ulcer. A second but mild episode of bleeding again occurred on the eighth day following the second operation. During this time the patient had experienced no pain, and the bleeding eventually stopped. Although sufficient time had not elapsed since vagotomy to expect healing to take place, this experience raises the question of the efficacy of vagotomy in the treatment of recently bleeding ulcers.

There have been no deaths and no significant postoperative complications other than those listed above.

It is much too early to discuss the end-results of vagotomy. All that

can be said at the present time is that the patients subjected to bilateral vagotomy by Drs. T. E. Jones, R. S. Dinsmore, and myself, with or without complementary operations on the stomach are, so far as we know at the present time, entirely free of symptoms of ulcer and are eating regular diets, are taking no antacid medication, and, if sufficient time has elapsed, have resumed their regular occupations. During the past year the results have been better than those following gastric resection in which vagotomy was not performed.

Surgical Anatomy of the Vagus

Anatomic studies of the vagus indicate that in the majority of cases the vagi form two large trunks above the diaphragm and descend through the esophageal hiatus in the form of two large nerves. Sometimes the main trunks are formed at or even below the level of the diaphragm, and sometimes one or two small branches are given off above the diaphragm and descend through the hiatus with the main trunks. The anterior or left vagus is usually the smaller of the two and is about the size of the lead of a lead pencil. The posterior, or right vagus, is often one and one-half to two times as large.

The anterior vagus lies just below the peritoneum near the midline of the esophagus. The posterior vagus has a more variable position but usually lies behind the middle of the esophagus or slightly to the right. Its relationship to the wall of the esophagus is not so intimate as that of the anterior vagus, and it more often lies in the loose areolar tissue of the posterior abdominal wall rather than in or on the musculature of the esophagus. Sometimes there are several small branches of the vagus given off at about the level of the diaphragm, but usually the nerves do not give off significant branches until they fan out on the wall of the stomach.

Technic of Subdiaphragmatic Vagotomy

The technic is still changing as experience increases and is not as yet standardized. The following deductions are based on my experience in performing 24 subdiaphragmatic vagotomies.

Exposure. Since the esophagus lies high and nearly in the midline it is important to carry the midline incision as high as the position of the xiphoid will allow. A midline incision is not only less vascular and easier to open and close than a left rectus incision, but it also affords a higher and hence a better exposure.

Before proceeding with vagotomy the upper abdomen should be explored, and the operator should assure himself as to the status of the

stomach, duodenum, gall bladder, and esophageal hiatus. It is unwise, however, to perform a gastric operation before vagotomy because soiling from the gastric operation results in contamination of the vulnerable mediastinum and subdiaphragmatic space during the vagotomy. Moreover, if for some reason a satisfactory vagotomy cannot be accomplished, it is possible that the surgeon would elect a radical rather than a conservative gastric operation.

The stomach should be emptied by gastric suction and a Levine tube left in place to aid in identifying the esophagus. It is helpful to pack away the spleen and the fundus of the stomach with a large moist tape inserted into the left upper quadrant of the abdomen.

The left lobe of the liver is sometimes quite large and may interfere with exposure of the vagus. In several of the earlier cases it seemed desirable to divide the avascular diaphragmatic attachments of the left lobe of the liver and reflect it to the right to obtain better exposure of the diaphragm. With increasing experience this maneuver rarely has been necessary. A broad Deaver or malleable retractor inserted under the liver to lift it forward affords adequate exposure.

Identification of the Vagus

The anterior vagus is quite constant in its location and usually can be found with little or no difficulty. The operator stands on the right side of the table. The stomach is grasped in the right hand with a moist tape and retracted downward while an assistant retracts the liver anteriorly with a Deaver retractor to expose the lower part of the esophagus. With the left hand the Levine tube in the esophagus is identified by palpation. Firm downward traction is then exerted on the stomach in such a way that the esophagus is placed on a stretch. The musculature of the esophagus, the peritoneum reflecting from the stomach and the esophagus on to the diaphragm, and the blood vessels of the stomach and esophagus are elastic, whereas the vagus nerve is nonelastic and stands out like a violin string, palpable and often visible beneath the peritoneum. As soon as the nerve is identified by palpation with the index finger of the left hand, the traction on the stomach is delegated to an assistant who maintains it while the peritoneum overlying the nerve is incised and the nerve is picked up on a long nerve hook. Its identity is quite unmistakable, and as soon as it is isolated it can be proved to be the vagus by following it upward through the esophageal hiatus in the diaphragm. The blood vessels of the stomach do not course in this direction nor does the esophageal hiatus transmit any other structure from the thorax to the abdomen. (Fig. 1)

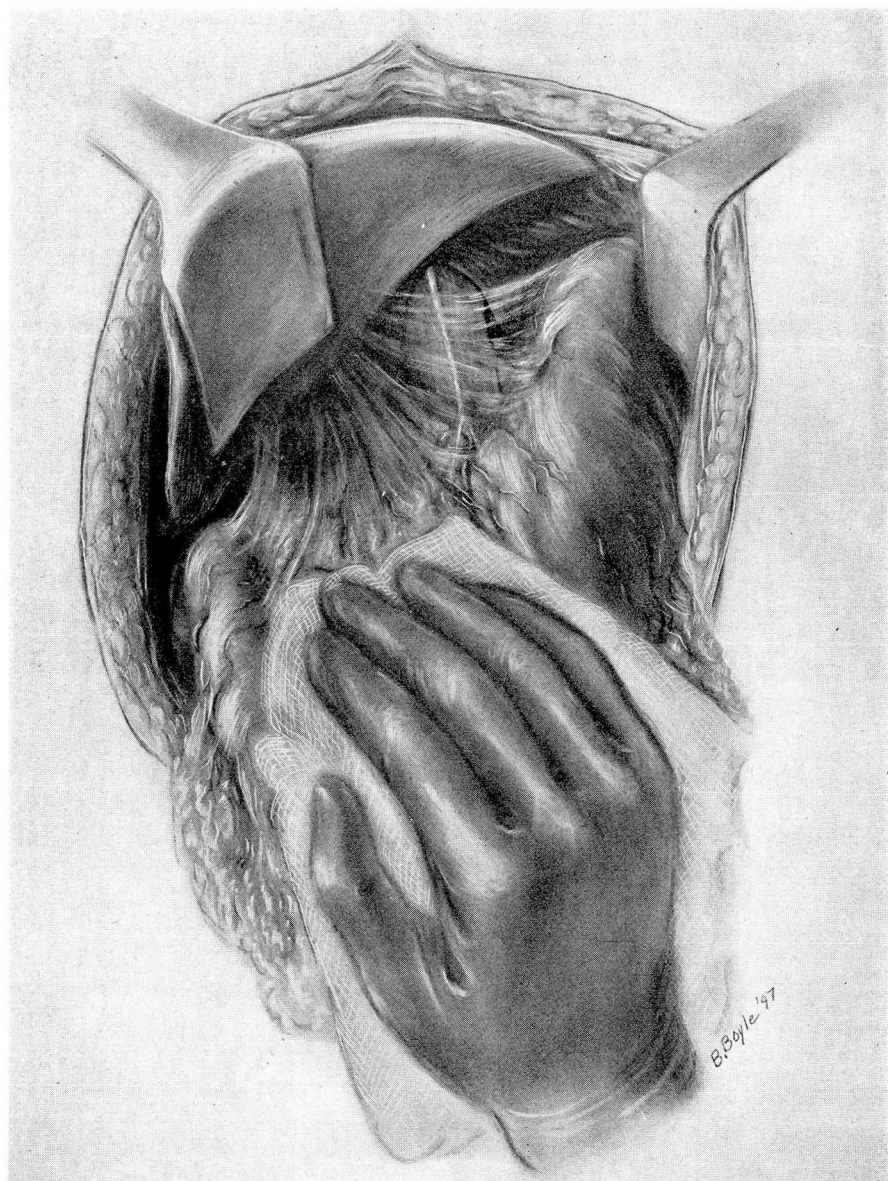


FIG. 1. Anterior vagus seen through peritoneum in its usual position on esophagus.

The nerve is isolated by blunt dissection up to or through the diaphragm and preferably higher so that there will be no question of failure to include all accessible branches. The nerve is then clamped with a Moynihan clamp, divided, and tied with a nonabsorbable ligature to prevent regeneration. The nerve is again divided several centimeters lower and the distal end is disregarded as it does not bleed. The excised segment is examined by the pathologist to prove its identity, but to date the pathologist has not reported anything but nerve tissue.

After completion of the anterior vagotomy the forefinger of the left hand is inserted through the delicate peritoneum of the gastrohepatic omentum above the gastric vessels, as in mobilization of the stomach for total gastrectomy. The stomach is again pulled downward by the right hand, and the posterior vagus is located by palpation as a tense cord lying either on the musculature of the esophagus or more often posterior to the esophagus in the areolar tissue. Occasionally it appears to be more to the right of the esophagus than directly posterior and may be surprisingly far away from it. The nerve is isolated by finger dissection and is then hooked over the finger and withdrawn from its retro-esophageal position, this part of the procedure being carried out mainly by the sense of touch. While an assistant pulls the stomach and esophagus downward and to the left, the nerve which is hooked over the index finger of the left hand is picked up by a nerve hook or in a Moynihan clamp and is dissected out, as in the case of the anterior nerve, by blunt dissection. It is important to make certain that it passes upward through the esophageal hiatus since there are vessels posteriorly that could be confused with the vagus if its course through the hiatus is not checked. A segment of the nerve is removed, as in the anterior vagotomy, and the proximal end tied. A final examination of the esophagus should be made to exclude the presence of additional branches coming down from above the diaphragm. (Fig. 2)

Following the vagotomy it is not necessary to reconstruct the peritoneum. Attention is next directed to whatever operation on the stomach is desirable to prevent gastric retention. Pyloroplasty, gastric resection, gastroenterostomy, and local excision of the ulcer each has its place, and the selection must depend on the nature of the ulcer, its location, and on the preferences of the surgeon. Whenever feasible, pyloroplasty would appear to be the operation of choice not only because of its simplicity but also because, if ulceration should recur, gastric resection could be done with ease and without the difficulty involved in taking down a gastroenterostomy. There may be cases in which the duodenum is fixed and foreshortened in which pyloroplasty is not easily accomplished and gastroenterostomy is preferable, but in many cases a simple

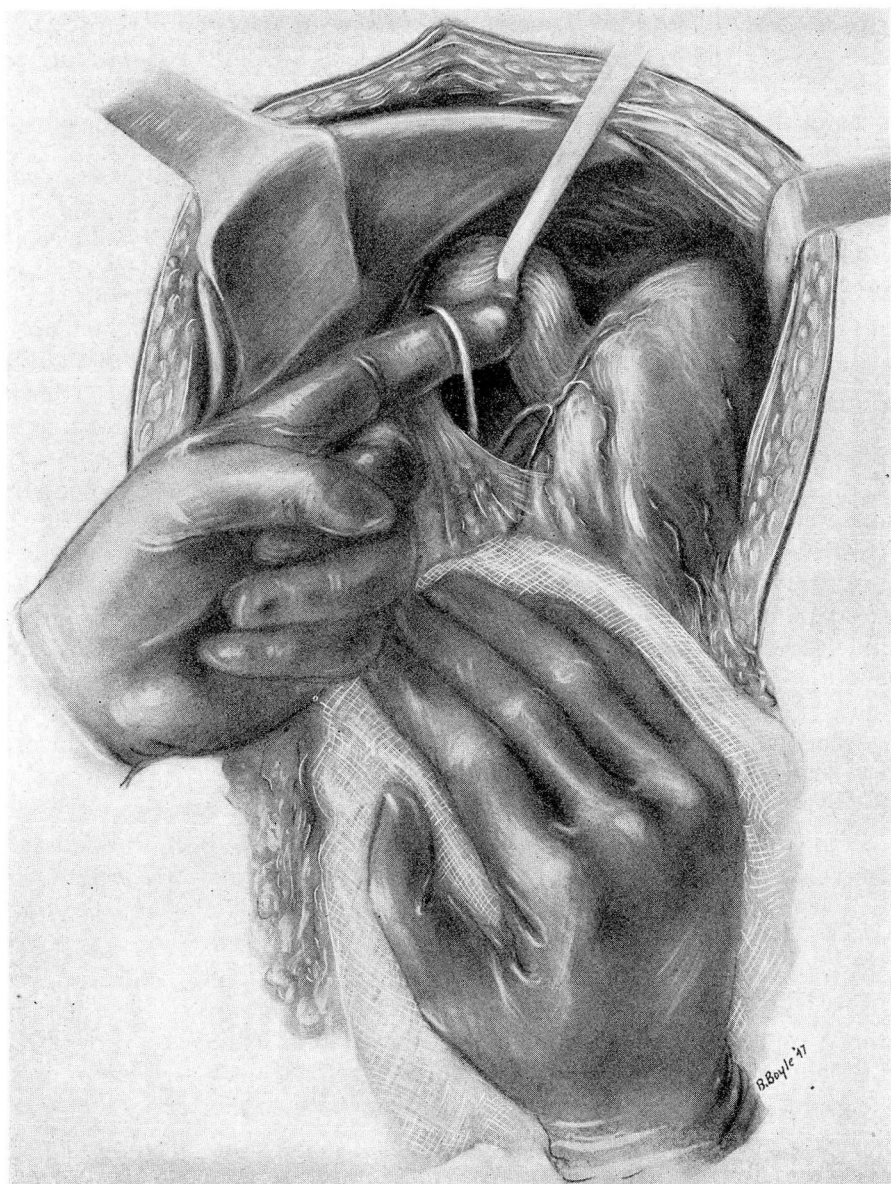

FIG. 2. Posterior vagus hooked over finger and brought forward from its position posterior to esophagus.

longitudinal incision through the pylorus and the narrowest portion of the duodenum can be sutured transversely with correction of any tendency to obstruction. Before the pylorus is closed a finger should be inserted first into the duodenum and then into the stomach to make certain that there is no stenosis not correctable by the pyloroplasty.

Complications

In the majority of cases anterior and posterior vagotomy is easily accomplished and does not unduly prolong the operating time. Occasionally in obese patients or when exposure is poor, identification of the nerves is facilitated by slipping a Penrose drain or tape around the esophagus and drawing it downward. I have rarely found this maneuver necessary, and in 1 patient weighing 232 pounds and having a large left lobe of the liver and a high diaphragm, isolation of the esophagus proved to be dangerous. I had inserted my finger through the gastro-hepatic omentum and was gently finger-dissecting around the totally unexposable esophagus when I suddenly found that I was lower than I had thought and had inserted my finger through the posterior wall of the stomach where I could palpate the Levine tube. The wall of the stomach in this obese individual, held as it was under tension, had proved much more friable than I would have believed possible. The proposed vagotomy was abandoned, and the small hole in the stomach was closed over as well as possible with fat. Two Levine tubes were left in the stomach with constant suction, and a pyloroplasty was done before closing. The patient was kept in Fowler's position with the tubes in place for four days and made a totally uneventful convalescence.

This case, in which a gastric resection would have been difficult and in which the patient was a poor surgical risk, was the only instance in which technical difficulties have arisen during vagotomy and the only one in which a proposed vagotomy was not completed.

In another case no large posterior vagus trunk could be located, but several small nerves were found and divided. Again on one occasion three, and on a second four separate fairly large trunks were resected, and all proved to be nerves. Only once was a blood vessel cut by mistake, and in this case the bleeding was easily controlled.

Insulin tolerance tests have been done following operation in most of the cases in which gastroenterostomies or gastric resections were not performed, but we have had difficulty in reducing the blood sugars to the desired levels. Although the number of satisfactory tests have been too few to be of statistical value, there has been only 1 case in which the blood sugar fell below 50 mg. per cent that there was a significant rise

in acidity. It is probable, therefore, that in most cases the vagotomies have been reasonably complete. The tendency to retention and dilatation of the stomach which occurs in a high percentage of the cases for the first week or two following operation also indicates that the denervation is adequate to accomplish its purpose.

Summary

1. The immediate results and the subsequent progress of 50 patients subjected to vagotomy have been gratifying.

2. Subdiaphragmatic vagotomy has largely supplanted transthoracic vagotomy because it enables the surgeon to explore the abdomen and if necessary simultaneously to perform an operation to prevent gastric retention.

3. In 32 subdiaphragmatic and 6 transthoracic bilateral vagotomies for ulcer there have been no deaths and only one complication (hemorrhage from a duodenal ulcer on the fifth postoperative day). All followed patients are free of symptoms of ulcer.

4. The excellent early results obtained following vagotomy have led to an increasing use of gastroenterostomy or pyloroplasty with vagotomy. If the results continue to be as good as they now appear, gastric resections will be used less frequently in the treatment of peptic ulcer.

5. A technic of subdiaphragmatic vagotomy is described, and emphasis is placed on the identification of the nerves by sense of touch when they are placed under tension by traction on the stomach.

Since this article was prepared, 27 more patients have been subjected to bilateral vagotomy. Most have had an associated gastroenterostomy or pyloroplasty. Temporary or partial retention has been observed in several of these patients, although in only 1 case have symptoms due to the retention occurred. This patient had no obstruction prior to operation, and nothing was done except a subdiaphragmatic vagotomy. He is still troubled five weeks after operation by a sense of fullness and occasional vomiting.

Reference

1. Dragstedt, L. R.: Vagotomy for gastroduodenal ulcer. *Ann. Surg.* **122**:973-989. 1945.