

BRAIN TUMOR WITH LONG SURVIVAL OF PATIENT

Report of a Case

U. V. PORTMANN, M.D.

Department of Therapeutic Radiology

This case report pertains to a retired police officer now 62 years of age. He was first seen twenty years ago in 1926 by the late Dr. T. E. Locke, who diagnosed a cystic tumor of the right parietal lobe of the brain. Some of the records were lost in the Cleveland Clinic disaster of 1929, destroying a few details of the history.

Case Report

On April 8, 1926, a man, aged 42, was referred to Cleveland Clinic. He complained of attacks of bitemporal and occipital headaches of about six months' duration, occasionally accompanied by vomiting. During the past three months a tremor and a paresis developed in the left arm and, to a lesser extent, in the left leg. These symptoms were associated with frequent attacks described by the patient as "drawing sensations". Attacks started with tingling in the finger tips of the left hand and proceeded up the arm, the left arm being drawn toward the head. The left labial commissure then drew to the left, followed by the remainder of the lower facial muscle group. At this point the patient lost consciousness and fell hard enough to injure his face. This coma apparently lasted about an hour. Vomiting occurred. Urethral and rectal sphincter control was maintained. In the last month a transient blurring of vision appeared and headaches became excruciating.

Physical examination at this time disclosed a left homonymous hemianopsia, bilateral papilledema, and retinal hemorrhages (fig. 1). The lower facial muscles, arm, and leg exhibited weakness on the left side. A marked tremor of the left arm was evident.

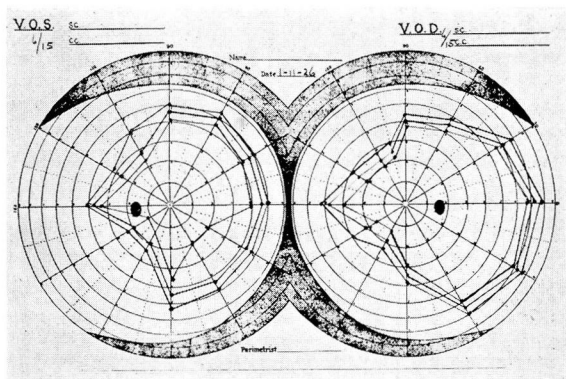


FIG. 1. Visual fields showing left homonymous hemianopsia.

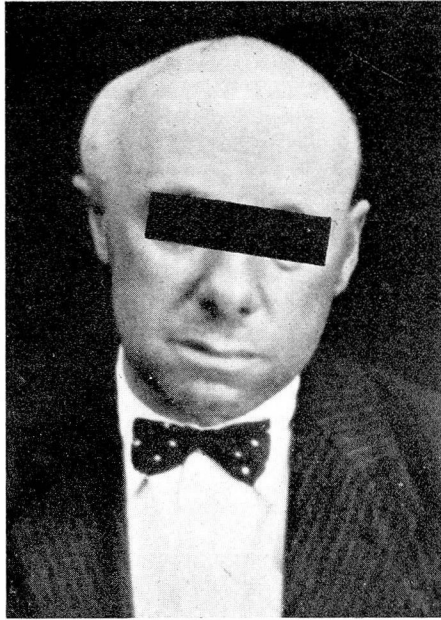


FIG. 2. Photograph of patient showing herniation at site of craniotomy.

Tactile sense was diminished over the left arm and leg. The deep reflexes of the left arm were exaggerated. The left cremasteric and plantar reflexes were diminished.

A diagnosis of right parietal lobe tumor was made. A cranioplasty and drainage of one or two cysts was performed by Dr. Locke on April 14, 1926, relieving the increased intracranial pressure. No further procedures were considered necessary, and the wound was closed without exposing the tumor.

A few months following operation there was considerable herniation of brain tissue through the cranial defect (fig. 2). At this time a course of roentgen therapy was given. The details of technic are not available. The patient was later given another course of roentgen therapy, after which the herniation disappeared.

On two occasions, November 29, 1926, and August 1, 1927, it became necessary to aspirate a cystic area in the tumor, and about 60 cc. of a viscid yellow fluid was removed each time. No biopsy report is available, but the clinical impression was cystic astrocytoma.

Two years later the patient suffered a return of the previous attacks on three occasions within the two months. At examination, serologic examinations were negative, blood cell studies normal, and blood sugar test 78 mg. per cent. There was no evidence of increased intracranial pressure nor herniation. A sedative of the barbitol series was prescribed to control the symptoms.

The patient resumed his work on the police force and in 1940, fourteen years after his initial visit, was doing light work at the age of 56. In June, 1940, however, he experienced two more attacks within three days. Examination revealed the decomposition flat and soft. Gait of the patient appeared normal, and no evidence of disability in the

left arm or leg was noted except for a slight exaggeration of the tendon reflexes. Sedation was again advised.

The patient was last seen on January 29, 1945, over eighteen years after his first visit, at which time he complained of severe sharp pains over the right forehead, upper jaw, and cheek. Pains appeared suddenly and lasted from a few seconds to a minute. The left homonymous hemianopsia remained. In addition the patient noticed blue and red flashes to his left. He had remained free of convulsions for the four and a half years since his last previous visit. The decompression remained soft and flat. The optic disks were normal. The new symptoms were explained on a sensory jacksonian basis. No treatment beyond mild sedation was recommended.

Discussion

This report presents the history of a patient with a cystic tumor, probably an astrocytoma, in the right parietal lobe of the brain. Surgical treatment consisted of decompression followed by aspiration of the cyst on two occasions. Radiation treatment was given at intervals and appeared to account to some extent for the regression of symptoms and for the long survival.

In our experience the usual course of even the slow-growing fibrillary astrocytoma is about ten years. As some of the records have been lost, the microscopic picture and exact diagnosis cannot be given in this case.