

# **SKELETAL CHANGES IN CHRONIC FLUORINE INTOXICATION**

## ***Report of a Case***

**C. J. McGARVEY, M.D., and A. C. ERNSTENE, M.D.**

**Division of Internal Medicine**

Although the bone changes of chronic fluorine intoxication in man have been well described abroad,<sup>1</sup> the American literature contains only a single case report<sup>2</sup> concerning the occurrence of these changes in workers in this country who have been exposed to fluorine compounds over long periods of time. It therefore seemed desirable to record a recent case in which a man who had handled various fluorides regularly throughout a period of thirty years' employment in a chemical plant presented the characteristic roentgenologic features of extensive deposition of fluoride in the skeleton.

## **Report of a Case**

A white man, aged 58 years, had felt well until three months before his first visit to the Clinic when he noted the onset of fatigue and dyspnea on exertion. The symptoms had gradually become more troublesome, and during the three weeks preceding his admission there had been occasional moderately severe frontal headaches. There were no other complaints. Since 1916 the patient had been steadily employed in a chemical plant where his work involved the constant handling of fluorine salts, chiefly sodium fluoride. According to his statement there was considerable chemical dust in the air of the room in which he worked, and although he was supplied with a protective mask he often dispensed with its use for the sake of comfort.

Physical examination revealed a well developed, well nourished man in no respiratory discomfort. The temperature was normal, the pulse rate 52 per minute, and the blood pressure 110/70. There was no cyanosis, and the peripheral venous pressure was not elevated. The few remaining teeth showed a brownish staining, but there was no mottling of the enamel. The anteroposterior diameter of the thorax was increased, and the inspiratory expansion of the chest was greatly limited. The lungs were hyperresonant on percussion, and no rales were heard. The heart was not enlarged, and its rhythm was regular. The heart sounds were somewhat distant but otherwise normal. No murmurs were present. The peripheral arteries showed only early diffuse thickening. Abdominal, rectal, and neurologic examination revealed nothing abnormal.

The urine had a specific gravity of 1.020 and contained no albumin, sugar, or abnormal cellular elements. The red blood cell count was 4,980,000, and the hemoglobin content of the blood 13.5 Gm. (88 per cent). The leukocyte count was 7100 with a normal differential count and no abnormal white cell forms. Platelets appeared to be present in normal numbers. Considerable difficulty was experienced in performing a sternal marrow puncture because of the hardness of the cortex of the bone. Examination of the aspirated marrow, however, revealed no abnormal changes. The calcium content of the blood serum was 10 mg. per 100 cc., and the phosphorus content 3.3 mg. The alkaline

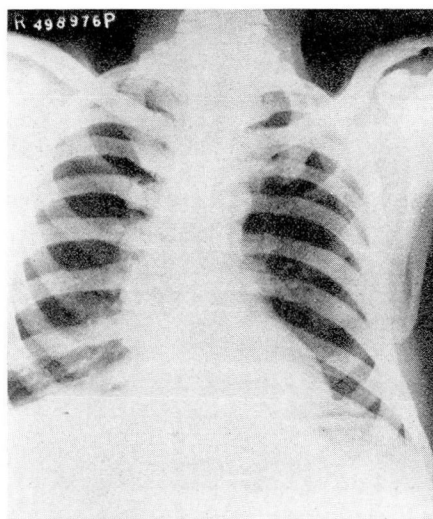


FIG. 1. Roentgenogram of the thorax. Illustrating the changes in the ribs, clavicles, scapula, and cervical region of the spine.

phosphatase activity of the serum was 4.9 units (normal 2 to 5 units), and the acid phosphatase 0.7 units (normal 0.1 to 1.0 units). The Wassermann reaction of the blood was negative. The electrocardiogram showed no diagnostic changes.

Roentgenograms of the thorax (fig. 1) revealed a striking increase in the opacity of the ribs, clavicles, scapulae, and dorsal vertebrae. Because of this finding films of other parts of the skeleton also were made and revealed similar changes involving the basilar bones of the skull, the mandible and maxilla, cervical region of the spine, lumbar region of the spine, pelvic bones, and the bones of the upper and lower extremities (figs. 2, 3, 4). The involvement of the vertebrae, ribs, and pelvic bones was essentially uniform in character and of such marked degree that the details of bone structure were almost completely obscured. The changes in the femurs and bones of the leg were somewhat less advanced, while the bones of the forearm showed still less involvement. Only relatively slight changes were present in the temporal, parietal, and occipital bones. In addition to the increase in density the bones showing the more advanced changes also appeared to be of increased breadth with thickening of the cortex, encroachment on the medullary cavity, and a somewhat irregular and indistinct cortical margin. The normal trabeculations were obliterated in the cancellous portions of these bones. No areas of bone destruction were present. The large joints showed no abnormalities, and the intervertebral cartilages appeared normal. There was no calcification of the costal cartilages.

### Discussion

The two known manifestations of chronic fluorine intoxication in man are brownish discoloration and mottling of the teeth and roentgenologic changes in bone. The dental defects are encountered in individuals who, during the period of enamel formation of the permanent teeth, have lived in areas where the drinking water contains considerable

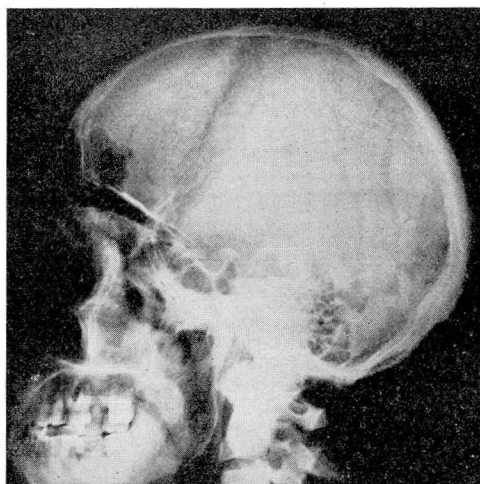


FIG. 2. Roentgenogram of the skull. Extensive changes in the cervical region of the spine mandible, maxilla, and bones of the base of the skull.

amounts of fluorine. The roentgenologic changes in bone were first described by Moller and Gudjonsson<sup>1</sup> in cryolite\* workers in Denmark. These investigators were unable to demonstrate similar changes in individuals exposed to the inhalation of fluorine fumes in glass, enamel, and sulfuric acid industries and therefore concluded that the findings in the cryolite workers were the result of ingestion, not inhalation, of small amounts of fluorides over long periods of time. The case reported by Bishop<sup>2</sup> occurred in a man who had been employed for eighteen years in a fertilizer factory where he handled finely ground rock phosphate containing 4 per cent fluorine. Necropsy studies in this patient revealed increased hardness of the involved bones with thickening of the cortex and encroachment on the marrow cavity. Although only a small amount of marrow tissue remained in the ribs, it appeared to be of normal structure. This is in harmony with the observations on the aspirated bone marrow in the present case.

Wolff and Kerr<sup>3</sup> made chemical analyses of the involved bones in Bishop's case and reported that the fluorine content was increased up to twenty times the normal value, the highest concentration being found in the vertebrae and the lowest in the long bones. They also described the external surfaces of the bones as being covered with chalky white areas, nodular and plate-like exostoses, and osteophytes. The specific gravity of the bones was found to be abnormally low, however, and they

\*Cryolite is a fluoride of aluminum and sodium which contains as much as 54 per cent of fluorine.

therefore concluded that the increased opacity to roentgen rays was due to increased thickness of the bones and not to an increase in actual density. No histologic studies were made. In 1891, however, Brandl and Tappeiner,<sup>4</sup> working on experimental fluoride poisoning in animals, reported that the bone structure was intact but the haversian canals were almost filled with crystals of calcium fluoride. This observation is difficult to reconcile with a reduced rather than an increased specific gravity of bone and indicates a need for further investigation.

Chronic fluoride intoxication in man causes no detectable impairment of general health provided the concentration of fluoride in the ingested dust is not too great. Nausea and vomiting were common complaints, however, in the cryolite workers studied by Moller and Gudjonsson,<sup>1</sup> the symptoms apparently being due to gastric irritation. In the present case there was no evidence that fluoride intoxication was responsible for the patient's symptoms. The dyspnea and fatigue could be explained adequately as due to emphysema of the lungs. Whether the relative immobility of the thoracic cage was the result of the changes in the bones and was in turn responsible for the development of emphysema is strictly conjectural.

### Summary

A case is reported in which a man who had handled various fluorides regularly throughout a period of thirty years' employment in a chemical

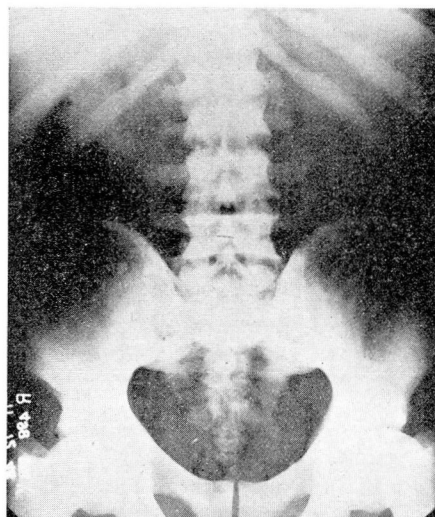


FIG. 3. Roentgenogram of the lumbar region of the spine and pelvis.

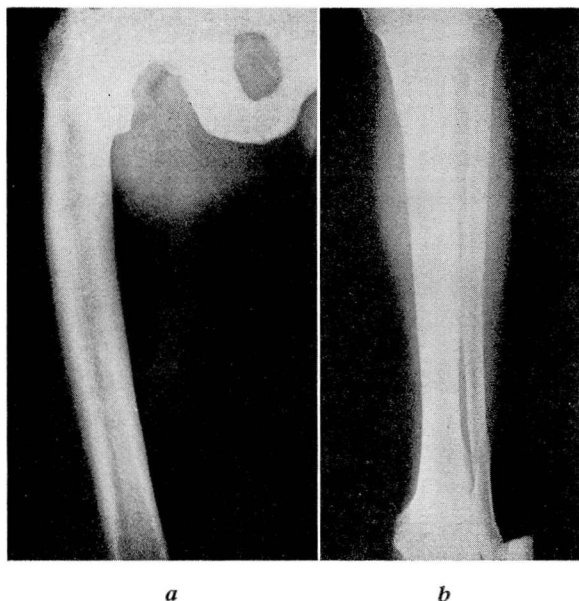


FIG. 4. (a) Roentgenogram of the right femur, ischium, and pubis. (b) Roentgenogram of the right tibia and fibula.

plant presented the characteristic roentgenologic features of deposition of calcium fluoride in practically all of the bones of the skeleton. The principal changes consisted of a striking increase in opacity of the bones together with some increase in their breadth. The most advanced changes were present in the vertebrae, ribs, and pelvic bones. There was no anemia, and examination of the sternal bone marrow revealed no diagnostic changes. The calcium and phosphorus contents of the blood serum were within normal limits, and the phosphatase activity also was normal.

The patient had no symptoms that could be attributed directly to chronic fluorine intoxication, although one might speculate as to whether the changes in the bones of the thorax had favored the development of emphysema of the lungs.

#### References

1. Moller, P. F., and Gudjonsson, S. V.: Massive fluorosis of bones and ligaments. *Acta radiol.* **13**:269-294. 1932.
2. Bishop, P. A.: Bone changes in chronic fluorine intoxication; roentgenographic study. *Am. J. Roentgenol.* **35**:577-585 (May) 1936.
3. Wolff, W. A., and Kerr, E. G.: Composition of human bone in chronic fluoride poisoning. *Am. J. M. Sc.* **195**:493-497 (April) 1938.
4. Brandl, J., and Tappeiner, H.: Über die Ablagerung von Fluorverbindungen im Organismus nach Fütterung mit Fluornatrium. *Ztschr. f. Biol.* **28**:518-539. 1891.