

RADICAL RESECTION OF CARCINOMA OF THE HEAD OF THE PANCREAS

With Report of a Case in a Man of 78

GEORGE CRILE, JR., M.D.

Division of Surgery

It is only in the past ten years that patients with carcinoma of the head of the pancreas have been offered a possibility of cure by surgical excision of the head of the pancreas and duodenum. The high mortality rate that at first attended this extensive procedure has been lowered by the discovery of vitamin K and by technical improvements in anastomosing the pancreatic and biliary ducts to the intestine. Mortality rates for large series of radical resections of the pancreas as low as 20 per cent have been reported,¹ a figure which corresponds favorably with that attending radical resections of gastric or intestinal carcinomas fifteen years ago.

Although the curability rate of carcinoma of the pancreas is still low the palliation afforded by radical resection with implantation of the common bile duct and the pancreatic ducts into the intestinal tract renders the operation well worth-while to those patients whose tumor has not extended beyond the pancreas. Not only do these patients have the nutritional advantage of the draining of both bile and the external secretion of the pancreas into the intestinal tract, but they have the knowledge that the tumor has been removed and that they have a chance for permanent cure. This attitude is to be compared with the hopelessness of the patient who is subjected to an exploratory operation and learns that he has an incurable cancer and can do nothing but await the inevitable end.

Cancer of the head of the pancreas is in general no more malignant, no more invasive, or no more prone to rapid growth or early metastasis than other carcinomas of the gastrointestinal tract. It would probably compare favorably in these respects with carcinoma of the stomach and somewhat unfavorably with carcinoma of the colon. The chief reason for the relative incurability of carcinoma of the pancreas is the failure to establish an early diagnosis.

Carcinoma of the head of the pancreas evades early diagnosis because the only physiologic disturbance incident to the early stages of the disease is obstruction of the pancreatic duct. Unfortunately this obstruction rarely causes symptoms more severe than a vague sense of

abdominal discomfort and loss of weight. These symptoms are so diffuse and poorly localized that the patient may not consult a physician, and when he does the evidence of carcinoma of the pancreas is seldom conclusive enough to justify an exploratory operation. If every patient complaining of slight loss of weight and appetite and vague abdominal distress were subjected to an exploratory laparotomy there would be too many useless operations, and if all patients so explored who were found to have suspicious areas of indurations in the pancreas were subjected to radical pancreatoduodenectomy, a significant number of patients with inflammatory lesions of the pancreas would doubtless be subjected to radical operations. Enough of these would probably die after operation to outnumber the patients with carcinoma who would obtain a permanent cure. Biopsy is not of great value in differentiating benign from malignant lesions because the carcinoma is often deep seated, and the specimen removed from the surface shows only fibrosis. We are therefore forced to concede that the accuracy of diagnosis of early carcinoma of the pancreas, either in the clinic or on the operating table, is unsatisfactory and that there is, at the present time, no accurate means of establishing the diagnosis until the chances of permanent cure of carcinoma of the pancreas are lower than the chances of permanent cure in most other types of carcinoma. Radical surgery must consequently be undertaken only when there are excellent indications that (1) the lesion is truly a carcinoma and that (2) the carcinoma is at least potentially curable.

It is not until a carcinoma of the head of the pancreas extends out of the pancreas itself to involve the common bile duct that the definite and localizing symptom of jaundice occurs. But as in the case of carcinoma elsewhere, when the tumor has extended out of the organ in which it originates to involve another organ, the prognosis is of necessity poor. What is needed is a means of detecting the presence of a carcinoma of the pancreas while it is still confined to the pancreas and is still potentially curable.

Carcinoma of the body and tail of the pancreas does not block the main pancreatic duct, as does carcinoma of the head, and hence is apt to cause no symptoms until metastasis occurs or until direct extension of the tumor involves the nerve roots. Carcinoma of the head of the pancreas often originates in or near the main duct and is liable to cause obstruction relatively early. Unfortunately, however, the only method of ascertaining whether or not the pancreatic duct is occluded is by study of the ferments in the duodenum. Since the pancreatic ferments differ but slightly from those secreted by the intestine our deductions must be based on quantitative changes which may be dependent on a

number of factors, including the position of the drainage tube. Analysis of the fat content of the stools gives little help because some patients who have had complete pancreatectomy show little disturbance in the assimilation of fat.

Since there is no specific laboratory test by which carcinoma of the head of the pancreas can be recognized with accuracy before the onset of jaundice, we are forced to wait in most cases until jaundice occurs before making the diagnosis. But when jaundice has developed there should be a minimum of delay in establishing a diagnosis and initiating treatment.

When a man over 60 years of age develops pruritis and a steadily deepening jaundice with no bile in the stool, the odds are in favor of an obstructing lesion of the bile duct, probably carcinoma. Under these circumstances, unless there is a history of alcoholism, ingestion of a toxic substance, stigmata of cirrhosis, or a striking impairment of liver function tests in the first few weeks of jaundice, there should be no delay in advising exploration or at least peritoneoscopy. The latter procedure gives much information with a minimum of risk, expense, and disability and can be done as an "in and out" procedure without hospitalization. Although little can be determined as to the nature of the obstruction, the liver and gall bladder can be visualized, and obstructive jaundice usually can be differentiated from degenerative or metastatic disease of the liver. If necessary, biopsies of the liver can be taken through the peritoneoscope.

When the common bile duct and the pancreatic duct are completely obstructed the patient's ability to assimilate food is strikingly impaired, weight is lost rapidly, protein metabolism is disturbed, and the function of the liver soon deteriorates. Under these circumstances the risk of operation rises in direct proportion to the duration of the jaundice. After three months irreversible damage has been done, and preoperative preparation cannot be expected to lower the risk very much. Under such circumstances the operation must often be divided into stages, thereby increasing the technical difficulties and subjecting the patient to greater discomfort and expense.

The following case illustrates the advantage of early operation before irreversible damage has taken place.

Case Report

The patient, aged 78, was subjected to radical pancreatoduodenectomy two weeks after the onset of jaundice and left the hospital two weeks after operation. He had been well until four weeks before entry, when he developed upper abdominal pain, belching,

and nausea. His urine had been dark during this time, and a week before entry the stools had become white. Four days before entry he noticed jaundice and itching. He had lost 15 pounds in the past two years and 3 pounds in the past week.

Examination showed a well developed, well preserved, wiry man whose weight was 150 pounds and height 5 ft. 6¼ inches. The skin and sclerae were jaundiced, and the liver edge was palpable 2 fingers' breadth below the costal margin. A rounded mass suggestive of the gall bladder was palpable under the liver edges.

Roentgenograms of the chest and upper abdomen showed no abnormalities.

The icteric index was 120. Stools were acholic and contained excessive amounts of fat. There was bile but no urobilinogen in the urine, and the serum bilirubin was 27.8. The blood amylase and the prothrombin time were normal, as were the blood counts and serology.

Five days later the patient was admitted to the hospital. After three days of preparation which included a high-protein, low-fat diet and the administration of synthetic vitamin K, a radical pancreaticoduodenostomy was performed in one stage. All of the duodenum and the head and part of the body of the pancreas were removed. Continuity of the gastrointestinal, pancreatic, and biliary tracts was re-established in accordance with the technic shown in the figure.

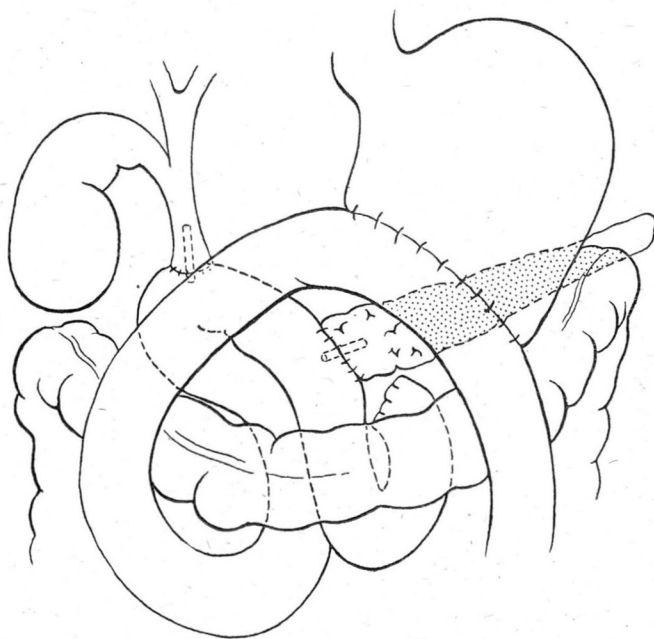


FIGURE. Radical resection of head of pancreas and duodenum, showing gastroenterostomy and implantation of pancreatic and biliary ducts into duodenum.

Convalescence was entirely uneventful, the maximum postoperative temperature never exceeding 100.5°. The patient left the hospital on the thirteenth day after operation with the jaundice subsiding. About ten days later he had an attack of severe epi-

gastric pain simulating biliary colic and a temperature of 101°. A roentgenogram showed that he had passed the catheter in the common duct over which the anastomosis had been made. The catheter was visualized in the colon. Convalescence from this time on was uneventful, and the patient rapidly regained strength. It is now four months since operation and he is free of symptoms and carrying on his work.

The pathologist reported the tumor an adenocarcinoma, fairly well differentiated, of the head of the pancreas. It is significant that two biopsies taken prior to resection showed nothing but fibrosis, further proof that a negative biopsy does not rule out deep seated carcinoma of the pancreas.

Summary

1. The lowered mortality rate following radical pancreatoduodenectomy for carcinoma of the head of the pancreas renders this the treatment of choice for carcinomas which have not metastasized or extended locally beyond the range of potential curability.

2. Even though the curability rate of carcinoma of the head of the pancreas is low, the striking palliation that follows resection and reimplantation of the pancreatic and bile ducts into the intestine and the optimism that arises from the knowledge that there is a chance of cure makes the operation of value in selected cases.

3. Carcinoma of the head of the pancreas is difficult to diagnose in its early stages either in the clinic or at the operating table.

4. The study of pancreatic ferments in the duodenum promises to aid in indicating an early obstructing carcinoma of the pancreatic duct, but this test is as yet somewhat unreliable.

5. When an elderly patient develops jaundice, his ability to survive operation diminishes rapidly, hence there should be no delay in establishing a diagnosis.

6. Radical pancreatoduodenectomy for a carcinoma of the pancreas occurring in a man 78 years of age is reported. The uneventful recovery is attributed to the fact that the operation was performed less than two weeks after the onset of jaundice.

Reference

1. Waugh, J. M., and Clagett, O. T.: Resection of duodenum and head of pancreas for carcinoma; an analysis of thirty cases. *Surgery* 20:224-232 (Aug.) 1946.