

COMMON BILE DUCT

15. Kehr, Quoted by Krueger, J. T.: Cholelithiasis. *Texas State J. Med.* **34**:480-483 (Nov.) 1938.
16. Lahey, F.: Incidence and management of stones in common and hepatic ducts. *Ann. Surg.* **98**:645-649 (Oct.) 1933.
17. Lahey, F., and Swinton, Neil: Stones in common and hepatic bile ducts. *New England J. Med.* **213**:1275-1280 (Dec. 26) 1935.
18. McGowan, J., Butsch, W., and Walters, W.: Pressure in common bile duct of man. *J.A.M.A.* **106**:2227-2230 (June 27) 1936.
19. O'Shea, M. C.: Stones in the ductus choledochus. *Am. J. Surg.* **57**:279-293 (Aug.) 1942.
20. Trueman, K. R.: Symptoms of common duct stone: review of 219 cases. *Proc. Staff Meetings Mayo Clinic* **15**:283-285 (May 1) 1940.
21. Walters, W.: Pathologic physiology of common bile duct and its relation to disease of biliary tract. *Proc. Interstate Post. Grad. M. A. of North America*, 21-25 (Oct. 12-16) 1936.
22. Walters, W.: Removal of stones from common and hepatic bile ducts in jaundiced patients. *Surg., Gynec., and Obst.* **47**:800-806 (Dec.) 1928.
23. Walters, W., and Wesson, H. R.: Fragmentation and expulsion of a common duct stone into duodenum by using ether and amyl nitrate. *Surg., Genec., and Obst.* **65**:695-697 (Nov.) 1936.
24. Weir, J. F., and Snell, A. M.: Symptoms that persist after cholecystectomy, their nature and probable significance. *J.A.M.A.* **105**:1093-1098 (Oct. 5) 1935.
25. Young, E. L.: Possibilities of failure in removal of stones in biliary tract. *New England J. Med.* **200**:1145-1147 (May 30) 1929.
26. Zollinger, R.: Observations following distention of gall bladder and common duct in man. *Proc. Soc. Exp. Biol. and Med.* **30**:1260-1261 (June) 1933.

THE CONTROL OF HEMORRHAGE IN OTOLARYNGOLOGY

PAUL M. MOORE, Jr., M.D.

Department of Otolaryngology

Hemorrhage from any part of the body is distressing and terrifying to the patient. In the field of otolaryngology this is particularly true, for the patient has not only the fear of bleeding to death but also the fear of suffocation from the accumulated blood. This fear arises because the bleeding most often fills the air passages, interfering materially with breathing.

Severe hemorrhage from the ear is rare but can occur. It may follow trauma which has ruptured the ear drum or caused a skull fracture through the temporal bone. These hemorrhages are usually not severe and should be left alone. Ear drops should never be used in such cases unless infection ensues. If there is no infection the use of irrigation or the instillation of drops may set up a serious infection.

Blood may collect in the tympanum behind an intact drum following neurosurgical procedures in which the cranium is opened close to the mastoid and some of the mastoid cells exposed. Blood may also reach

the tympanum during a severe nasal hemorrhage, the blood flowing up the eustachian tube. In both these situations one usually treats the condition expectantly.

In the former an attempt to evacuate the blood by myringotomy and inflation might lead to intracranial infection, and in the latter one can do no intranasal manipulation other than that required to stop the nasal hemorrhage.

Severe hemorrhage can occur in the following instances:

1. After myringotomy in a patient with a high jugular bulb extending into the lower part of the tympanum. Such an anomaly is rare, but when it exists the drum may have a bluish cast. It is safer not to incise this type of drum.

2. Postoperatively following a mastoidectomy when there has been a surgical or pathologic exposure of the lateral sinus. Severe hemorrhage from the canal in this situation may mean rupture of the lateral sinus. The wound should be opened quickly, and the surgeon should be prepared to pack off the lateral sinus if this proves to be the source of the bleeding.

One patient with such symptoms was a child who had had a simple mastoid operation disclosing a large pathologic exposure of the lateral sinus. Since the perforation in the drum had been inadequate, a myringotomy had also been done. That evening a rapidly enlarging spot of blood appeared on the bandage. The child was taken to the operating room immediately and the bandage was removed under ether anesthesia. Active bleeding was coming from the canal, but none from the mastoid wound. No blood was found in the mastoid cavity, and the sinus was intact. The bleeding came from the drum, and a pack in the external canal controlled it easily. Yet, in similar cases the physician should not neglect inspection of the mastoid cavity and the lateral sinus.

3. Another serious type of hemorrhage from the auditory canal is that associated with an infection in the lateral pharyngeal space. This indicates a ruptured internal carotid artery, and ligation of the common carotid artery should be done at once to prevent a fatal outcome.

Nose bleeds are usually thought to be of minor consequence, but a severe nasal hemorrhage can be one of the most harrowing experiences in the practice of otolaryngology. The simple epistaxis usually receives no more attention than the old-fashioned home remedies of cold water and cold cloths, folded paper placed under the upper lip, or a cold metal key hung down the back between the shoulder blades.

When severe nasal hemorrhage occurs the blood may pour out so rapidly that examination of the nasal cavity may be almost impossible. When it stops the source of bleeding may be difficult to locate. A de-

terminated effort should be made to locate the bleeding point and cauterize the ruptured vessel. If the bleeding is brisk it may be slowed by temporarily placing adrenalin packs in the nose. It is well to mix some 10 per cent cocaine with the adrenalin so that some measure of anesthesia is obtained. A suction tip may remove the blood rapidly enough to trace the source of bleeding. A small blood clot in the ruptured vessel wall may extrude as a raised red or white dot on the surface of the mucosa, and if this is displaced during the removal of clots, bleeding may recur slowly or even briskly. The bleeding must be stopped and the area cauterized after reinsertion of an adrenalin and cocaine pack against the bleeding point.

If the vessel is relatively small the application of a 50 per cent solution of trichloroacetic acid may control it. A cotton-tipped probe is dipped into the solution and the adrenalin pack gradually pushed back until the tip of the probe is in contact with the bleeding point. If the vessel is large, electrocoagulation must be done under complete local anesthesia or under general anesthesia with pentothal sodium.

Fortunately most nasal hemorrhages originate in Kiesselbach's or Little's area on the septum. This area is easily accessible for inspection, packing, and cauterization. Figure 1 shows the distribution of the major vessels over the septum. The blood vessels in this area are arranged in the form of a plexus and are more susceptible to trauma than the rest of the nose. The blood vessels of the nasal cavity may dilate and contract quite rapidly and to a marked degree.

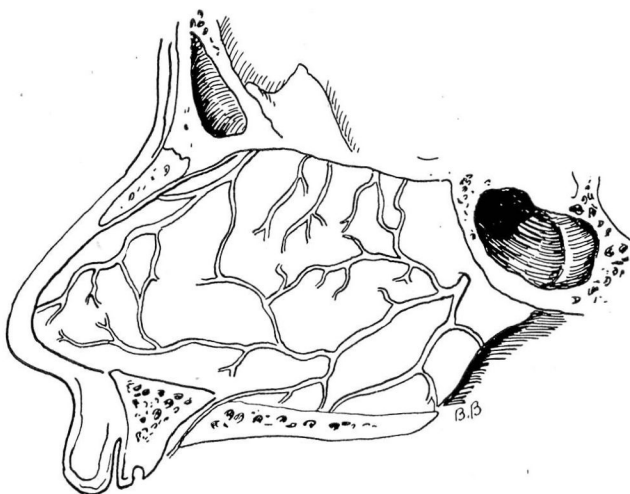


FIG. 1. Blood vessels of septum.

One patient gave the history of severe nose bleeds, but at the time of examination there was nothing to be seen in the nasal cavity. She was told to return while the nose was bleeding, and before she left the building the epistaxis recurred. A ruptured dilated vessel about a millimeter in diameter was seen in Little's area. These vessels may be made to dilate by spraying them forcibly with a 2 to 4 per cent cocaine solution. This procedure may also wash off small blood clots and start slight bleeding from the area being sought.

Nasal hemorrhage, difficult to visualize and difficult to control, may occur from larger vessels high up on the septum or back in the nasal cavity.

Figure 2 shows the distribution on the lateral wall of the nose. Bleeding coming from beneath the turbinates, frequently beneath the posterior end of the inferior turbinate, is also difficult to control even with packing.

When the hemorrhage is severe and the bleeding point cannot be seen, it is best to pack the nose tightly to prevent further loss of blood. For this, softly rolled cotton packs about the size of one's little finger and long enough to reach the entire length of the nasal cavity are preferred. They may be moistened with some preparation like thromboplastin. The first pack is placed on the floor so that one end reaches the posterior naris and the other the vestibule. It is then pressed down on

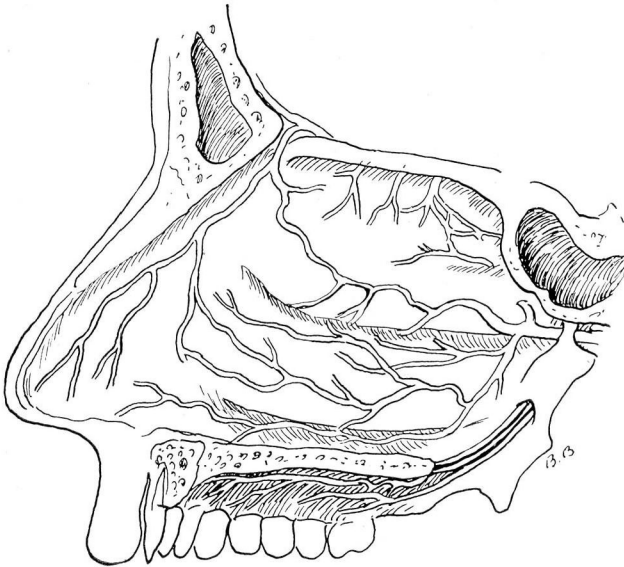


FIG. 2. Blood vessels of lateral wall of nose.

the floor and pushed laterally under the inferior turbinate. The second pack is pressed down on top and medial to the first. In this way packs are placed on top of each other until the entire cavity is tightly packed. If bleeding still continues the forceps may be worked between the central packs and then spread so that the upper packs are forced higher into the cavity. In this way another pack may be inserted. The number of packs must be recorded since they are left in the nose for two or three days. They may be removed one a day if desired. It is seldom necessary to use a postnasal pack when the nasal cavity has been treated in this fashion.

If bleeding recurs upon removal of the packs, the nose can be re-packed. However, if packs are left in the nose too long the membranes become macerated, and new bleeding points occur when they are removed.

A more direct method of permanent control is electrocoagulation. After the severe hemorrhage is controlled or at least slowed by the packs, the patient can be placed under general anesthesia with pentothal. A postnasal tampon is pulled into place through the unpacked side. The nasal packs are then removed from the involved side and search made for the source of bleeding. A metal suction tip is covered with a sheath of rubber tubing, leaving the metal tip and the handle exposed. With this instrument one can remove the blood and follow it to its source. The electrode of a coagulating diathermy machine is then placed against the handle of the suction tip and the bleeding point coagulated until bleeding ceases. The suction keeps the field dry enough for the current to act on the desired point. It may be necessary to use adrenalin packs and pressure first in order to slow the bleeding sufficiently for the above procedure.

Local causes for the nasal hemorrhage must be sought. There may be a malignant neoplasm in the nasal cavity which is easily found and readily recognized. A biopsy will establish the correct diagnosis, and proper treatment can be instituted. A badly deviated septum is sometimes responsible for sufficient distortion of the blood vessels to make them prone to rupture. A badly deviated septum may also prevent proper access to the posterior nasal chamber. In either of these conditions a submucous resection is indicated.

One relatively young hypertensive patient had recurring extremely severe nasal hemorrhages over a period of many years. In one recent attack it was found that a badly deviated septum prevented good access to the posterior portion of the right nasal cavity, the side which produced the hemorrhages.

She was having a very severe hemorrhage, and when the right side was packed blood poured out the left side. The left side was packed and blood ran out the eustachian tube. It also ran up the nasolacrimal ducts and into the eyes. It finally was brought under control, and eventually the packs were completely removed. The nasal cavity could not be searched because of the septal deviation.

Two years later the patient returned with a somewhat less severe hemorrhage which was more easily controlled. This time she would not leave the hospital until the submucous resection was done. After the deviation was removed a small hemangioma was found on the septal membrane high up and just behind the sharp edge of the deviation on the right side. The hemangioma was cauterized.

Hemorrhage has been reported as originating in the antrum without fracture or infection.¹ Only a thickened membrane was found in those cases where a Caldwell-Luc operation had to be done to control the bleeding. Many of these cases were controlled by several irrigations alone and without operative interference.

In severe bleeding following intranasal operations the source of bleeding may be traced and controlled by electrocoagulation. The type of operation often indicates the source of bleeding. After sphe-no-ethmoid evisceration, for example, one should look for bleeding from the sphe-no-palatine artery at or just below the operative opening into the sphe-noid. The anterior or posterior ethmoid arteries may be the source of the bleed-ing. Intranasal packing may be required.

Transantral ligation of the internal maxillary artery in the sphe-no-maxillary fossa has been successfully done in many severe nasal hemor-rhages.²

This provides positive control of bleeding from one of the branches of this artery. It is not a simple procedure but must be seriously con-sidered in those cases of intractable nasal hemorrhage which refuse to yield to more conservative measures.

In all severe nasal hemorrhage cases a complete medical examination should be made. This is particularly necessary when bleeding tends to recur. The great majority of these patients will be found to be hyper-tensives, for which condition they require treatment. Sometimes hemorrhagic disease which needs attention may be found.

One disease in which there may be hemorrhages, not only from the nose but also from other mucous membranes, even the skin, is hereditary hemorrhagic telangiectasia, or Osler's disease. The hemorrhages occur most frequently from the nose. Often several members of the family will have the condition. There are many small telangiectasias scattered through the mucosa of the nasal cavity and mouth and in the skin. The

bleeding lesions can be cauterized, or, if too numerous, can be treated with radium. More than one radium treatment is usually necessary.

Hemorrhage from the nasopharynx may result from the presence of hemangioma, nasopharyngeal fibroma, or malignant disease. It may follow adenoidectomy or result from infection in the lateral pharyngeal space with rupture of the internal carotid. Following adenoidectomy hemorrhage can usually be avoided by careful hemostasis in the operating room. Tabs of adenoid tissue which may continue to bleed should be located and removed. Occasionally a bleeding vessel which requires clamping with a hemostat and tying may be present. If the hemorrhage cannot be controlled in any other way, a postnasal tampon is inserted. Hemorrhage from a nasopharyngeal fibroma can be avoided by recognition of the tumor and treatment with radium, which will cause enough fibrosis of the many blood vessels to simplify excision. Attempts to remove these fibromata without preliminary irradiation can result in serious hemorrhage.

Throat conditions which must be considered are hemangiomata, other neoplasms, and the effects of previous operations. Severe bleeding may occur during the course of a tonsillectomy. Deaths have been reported from the rupture of an anomalous internal carotid artery displaced to the region of the posterior pillar. As a rule severe bleeding in tonsillectomy can be avoided by keeping the dissection close to the surgical capsule, and ligating carefully all bleeders. A search of the fossa may reveal rather large veins that have been severed and the ends sealed off so that they are not bleeding at the time. These should be clamped and tied. It is better to eliminate completely all potential bleeders at operation while the patient is well anesthetized.

Even with great care, a few patients will have postoperative hemorrhages within the first twelve to twenty-four hours. This type of hemorrhage is usually from a vessel that was not ligated or one from which the ligature has slipped. Before leaving the operating room the patient should be warned not to suck on his throat or clear it for several hours. If bleeding does occur the vessel must be located and ligated. The reinjection of novacaine and adrenalin in the bleeding area will help control it and provide anesthesia for the clamping and ligating. Occasionally it is a general ooze which can be controlled by pressure with a gauze sponge or by removal of a poorly formed clot.

Delayed hemorrhage may occur on the fifth to the seventh day after tonsillectomy. These are seldom severe, but they frighten the patient. Removal of the clot and pressure with a sponge are usually sufficient. If the bleeding has stopped and there is a well formed clot, it may be left alone. It is usually best to hospitalize such a patient for observa-

tion. Small doses of morphine will frequently quiet him enough to stop the bleeding. These postoperative hemorrhages are the result of separation of a slough in the tonsillar fossa and are usually seen in patients who have failed to keep the throat clean and in whom there is considerable secondary infection.

The most serious hemorrhage—that with the highest and swiftest mortality—may occur during the course of infection in the lateral pharyngeal space (figure 3). It may follow a tonsillitis, a peritonsillar abscess, or a retropharyngeal abscess with extension into this space. It is most often the result of infection, rupture, and false aneurism of the internal carotid artery. The rush of blood is held in check for a time by

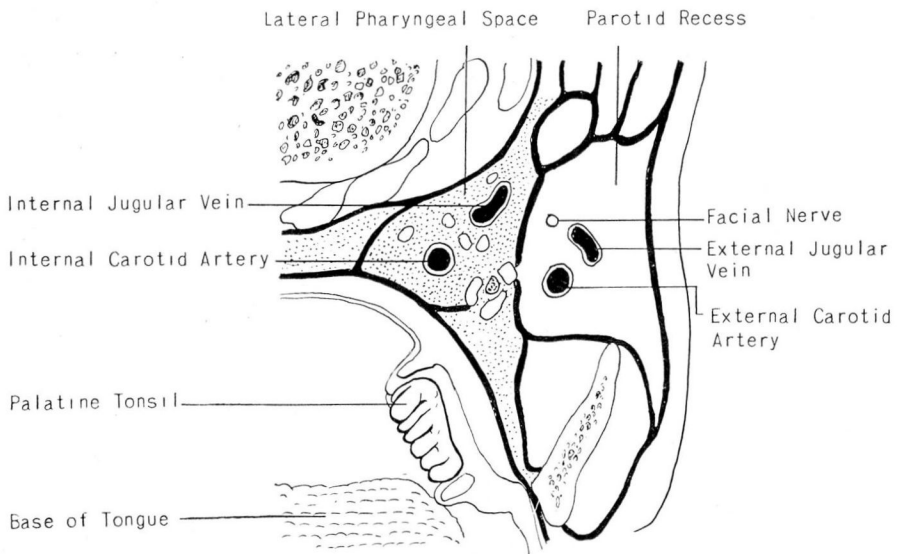


FIG. 3. Lateral pharyngeal spaces.

the walls of the abscess cavity. It may burrow and rupture into the external auditory canal with a severe hemorrhage from that orifice. It may also burrow upward and rupture into the nasopharynx above the soft palate. The peritonsillar or retropharyngeal abscess may be incised, thus weakening the confining walls of the false aneurism. If such an abscess yields no pus but only some dark blood, one should be on guard for severe hemorrhage. A single fulminating hemorrhage has resulted in death before anything could be done.

If there is evidence of infection of the lateral pharyngeal space and severe hemorrhage from the ear, nasopharynx, or pharynx occurs, the patient should be taken to the operating room immediately and the

common carotid artery ligated. Delay may result in a second and possibly fatal hemorrhage.

The external carotid artery has been the site of rupture in a few cases, but the internal carotid is by far the one most frequently affected. Since most of these cases occur in children, serious intracranial complications are relatively infrequent as the result of sudden ligation of the internal carotid artery. But even with the possibility of such an occurrence one must act quickly, for to temporize means death. Fortunately these cases are uncommon, yet Salinger and Perlman collected 231 in their report in 1933.³ Every physician should be familiar with this condition because when suddenly confronted with such a case he does not have time to study the literature. It is to be hoped that present day chemotherapy will halt such infections before they have created such serious damage.

Bleeding from the mouth may have its source in the mouth itself, the posterior portion of the nose, nasopharynx, pharynx, esophagus, or tracheobronchial tree. The patient's account of the occurrence is seldom helpful in tracing the source of the bleeding. When the bleeding arises from the posterior part of the nose or nasopharynx, some blood often comes from the nose; when it arises from the esophagus there is often vomiting and tarry stools, and when from the tracheobronchial tree, there is usually a cough which raises old blood and clots after active bleeding has subsided.

Careful examination with postnasal and laryngeal mirrors and nasopharyngoscope may reveal the lesion responsible or may trace the source of the bleeding. If blood is seen below the vocal cords the search must be continued with the bronchoscope.

When the esophagus is suspected, it is first studied with the fluoroscope, and roentgenograms are taken. This is followed by esophagoscopy. The lesions which may produce bleeding are varicose veins, malignant neoplasm, peptic ulcer of the esophagus, and the presence of a foreign body. The history and the roentgen examination will usually reveal the nature of the lesion.

In esophageal varices there may be no history of dysphagia. The first intimation of such involvement may be a massive hematemesis or massive gastrointestinal bleeding with tarry stools. Treatment consists of repeated injections of a 5 per cent solution of sodium morrhuate through the esophagoscope with an especially designed needle. As much as 9 cc. of the solution has been injected by Moersch at one treatment, but he advises using smaller amounts in most cases.⁴

In carcinoma of the esophagus there is a history of progressive dysphagia over a period of less than a year. At first there is difficulty

with the swallowing of solid foods and later with liquids. When the neoplasm is not too large and involves either the upper or lower end of the esophagus, surgical removal may be successful. If the carcinoma is found in the midesophagus, the problem is greatly complicated. Some successful removals have been reported. Irradiation therapy has been disappointing.

A neglected foreign body may result in fatal massive hemorrhage from perforation into the descending aorta.

One patient, a 14-year-old girl, swallowed a chicken bone which lodged crosswise in the esophagus. She was given bread and mashed potatoes in an attempt to dislodge the bone. The pain abated and nothing more was done until she had a massive hematemesis. She was then sent to the hospital, but the ends of the bone had penetrated the walls of the esophagus, one end working through the wall of the descending aorta as well, and the result was a massive fatal hemorrhage.

A similar fatal hemorrhage has been reported in a patient with primary tuberculous infection of the esophagus. The ulceration had extended into the descending aorta.

Bleeding from the tracheobronchial tree may be due to the presence of tuberculosis, malignant neoplasm, benign adenoma, hemangioma, broncholithiasis, or bronchiectasis. With the exception of hemangioma, the history and roentgenogram will usually establish the diagnosis. The hemangioma can usually be seen through the bronchoscope and destroyed by electrocoagulation. Bronchoscopy and biopsy are necessary to differentiate between a malignant neoplasm and a benign adenoma. Pneumonectomy should be done in those cases of carcinoma of the lung which are operable. Electrocoagulation will usually control the tendency of adenomata to bleed; removal of the calculus whenever possible will relieve broncholithiasis; lobectomy is indicated if bronchiectasis is unilateral, and postural drainage, chemotherapy and management of a possible allergy if the disease is bilateral.

In all cases presenting no definite local cause for the hemorrhage, careful general examination should be made. Cardiorenal disease with hypertension may be the main reason for the bleeding. Complete blood studies, including platelet counts and coagulation time, must be made to rule out the hemorrhagic diseases. A low platelet count is found in thrombocytopenic purpura hemorrhagica of both primary and secondary types. In the primary type splenectomy is the only procedure that has given relatively good results. The secondary type includes many of the blood dyscrasias such as pernicious anemia, myelogenous leukemia, lymphatic leukemia, aleukemic myelosis, and aplastic anemia.

Hemorrhage may occur in many of the infectious diseases. Delayed

coagulation time with a normal platelet count occurs in hemophilia, in obstructive jaundice, and in hemorrhagic disease of the newborn. In hemophilia there is a deficiency of thromboplastin; in obstructive jaundice and hemorrhagic disease of the newborn there is a deficiency of prothrombin. This can be corrected by the administration of vitamin K, but to give vitamin K in all cases of bleeding without first determining a real deficiency of prothrombin is of no value.

In all severe hemorrhages the first and most urgent concern is to control and stop the bleeding. Secondly, the depleting effects of the hemorrhage must be remedied by the use of general supportive measures. These include rest and administration of iron and, if the loss of blood has been sudden and severe, blood transfusion. Appropriate sedation may prevent a recurrence of the bleeding until the ruptured vessel has healed or thrombosed.

References

1. Hall, S. S., and Thomas, H. V.: Spontaneous hemorrhage into maxillary sinus. Arch. Otolaryng. 28:371-375 (Sept.) 1938.
2. Hirsch, C.: Ligation of internal maxillary artery in patients with nasal hemorrhage. Arch. Otolaryng. 24:589-593 (Nov.) 1936.
3. Salinger, S., and Pearlman, S. J.: Hemorrhage from pharyngeal and peritonsillar abscesses; report of cases, resume of literature and discussion of ligation of carotid artery. Arch. Otolaryng. 18:464-509 (Oct.) 1933.
4. Moersch, H. J.: Further studies on treatment of esophageal varices by injection of sclerosing solution. Ann. Otol. Rhin. & Laryng. 50:1233-1244 (Dec.) 1941.

OCULAR TORTICOLLIS

Report of a Case

R. J. KENNEDY, M.D.

Department of Ophthalmology

The term "ocular torticollis" was applied by Cuignet in 1874 to a compensatory tilting of the head in cases of paralysis of one of the muscles controlling the vertical movements of the eye. The patient unconsciously assumes this position to avoid diplopia.

◊ The following case is presented to show the need for eye muscle studies in all cases of torticollis.

Case Report

A 57-year-old woman reported to Cleveland Clinic in October, 1944, with the complaint of "sore neck" and "spasm of neck muscles". She stated that for twelve years she had had a "drawing" of the neck, which had noticeably increased during the past two years. Examination revealed the head (chin) turned to the left, the patient having difficulty straightening her head.

There was decided apparent hypertrophy of the right sternomastoid muscle. X-ray examination of the cervical region of the spine showed a slight cervical dorsal scoliosis of the cervical and dorsal regions of the spine. Considerable osteoarthritis was present in the cervical area, and there was some calcification of the intervertebral discs.