

2. Obstructing concretions of sulfonamides can usually be relieved by ureteral catheterization and lavage of the renal pelves. If the obstruction cannot be passed, pyelostomy should be done without delay.

3. Adequate fluid intake and urinary output are the best safeguards against this complication.

4. Simultaneous administration of sodium bicarbonate when giving sulfonamides is desirable.

#### REFERENCES

1. Finland, M., Strauss, E., and Peterson, O. L.: Sulfadiazine—Therapeutic evaluation and toxic effects on four hundred and forty-six patients. *J.A.M.A.* **116**:2641 (June 7) 1941.
2. Prien, E. L., Crabtree, E. G., and Frondel, C.: Mechanism of urinary tract obstruction in sulfathiazole therapy; identification of crystals in tissue by polarized light. *J. Urol.* **46**:1020-1032 (Nov.) 1941.
3. Jensen, O. J., and Fox, C. L.: Hydrogen ion concentration and the solubility of sulfonamides in urine; the relation to renal precipitation. *J. Urol.* **49**:334 (Feb.) 1943.
4. Schwartz, L., Flippin, H. F., Reinhold, J. G., and Domm, A. H.: The effect of alkali on crystalluria from sulfathiazole and sulfadiazine. *J.A.M.A.* **117**:514 (Aug. 16) 1941.
5. Smiley, L. V.: Suppression of urine complicating sulfadiazine therapy. *U. S. Nav. M. Bull.* **44**:328-332 (Feb.) 1945.

## SURGICAL TREATMENT OF INTRACTABLE PLANTAR WARTS

J. A. DICKSON, M.D.

The majority of plantar warts are successfully eradicated by conservative measures such as escharotic solutions, electro-desiccation, or irradiation in the form of x-ray. Comparable results are obtained by each of the above methods, 60 per cent to 90 per cent cures. Escharotics are reserved for simple cases, and electro-desiccation and irradiation are employed when local application of these substances fails. If a single method is desired, the selection would undoubtedly be x-ray, for this treatment is painless, short, successful, and safe, provided the treatment is administered with due respect to the tolerance dose.

It is recognized, however, that no matter how skillfully used, these methods fail in at least 10 per cent of cases. These intractable problems are not only distressing but often calamitous to the patient. After many years of therapy extremely painful ulceration on the plantar surface of the foot may still persist. This ulcer invariably extends through the deep fascia, and the dermatologist and roentgenologist feel they have run the

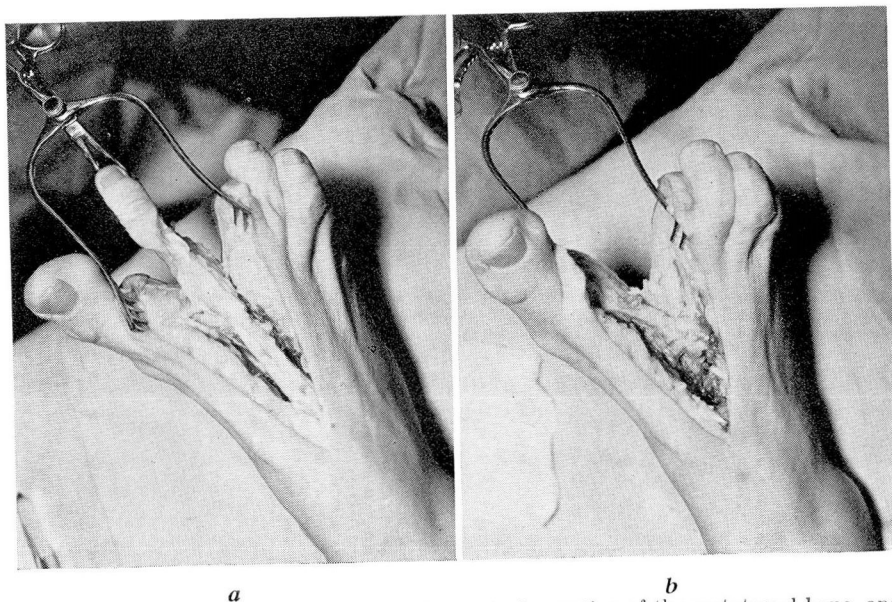


FIG. 1. Showing pie operation, (a) subperiosteal resection of the metatarsal bone, and (b) complete removal of metatarsal bone.

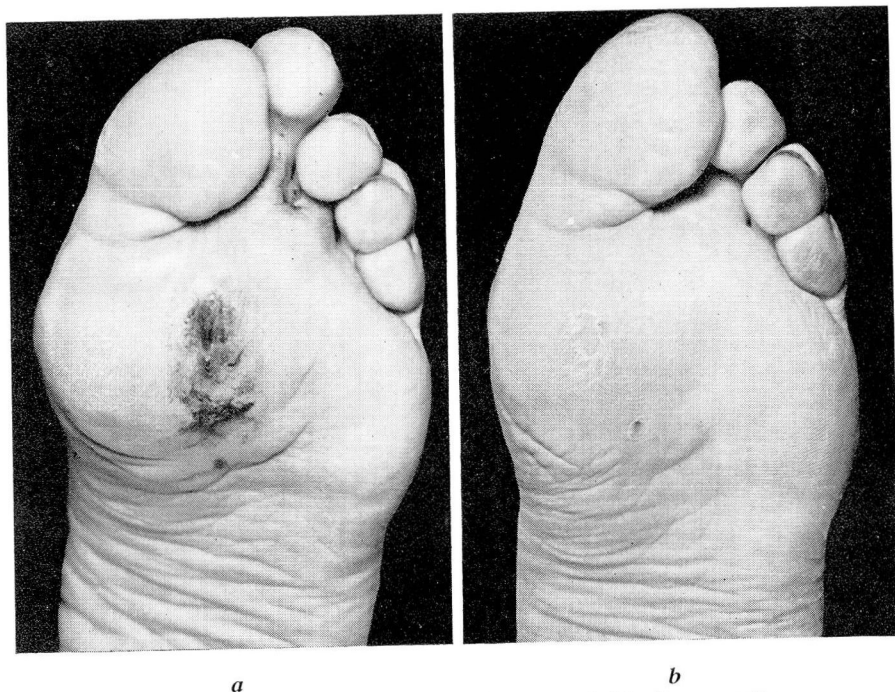


FIG. 2. Case 1. (a) Condition of foot before, and (b) after operation.

gamut and that further cautery, x-ray or radium treatment is contraindicated.

For this type of plantar wart the only recourse is removal of the wart area in its entirety, and while this in itself presents no difficulty, the restoration of the operative site to a painless weight-bearing area involves many surgical problems. The amount of tissue removed may make immediate closure impossible, and even though approximation of the skin edges can be accomplished, it is performed under such tension that the resulting scar becomes thick, unyielding, and painful. Full thickness grafts, pedicle transplants from the involved foot or opposite calf, though successfully transferred, retain the characteristics of the donor site, and the thin skin does not furnish sufficient protection to weight-bearing.

In many instances, even though the defect could be sutured without undue tension, or a full thickness graft could be successfully transferred, the pressure of the overlying metatarsal head gradually transforms the operative scar and adjacent weight-bearing area into a dense, painful cicatrix as productive of symptoms as the original wart.

I thought that the removal of a V section of the foot, including a wide excision of the wart with a toe and the corresponding metatarsal bone,

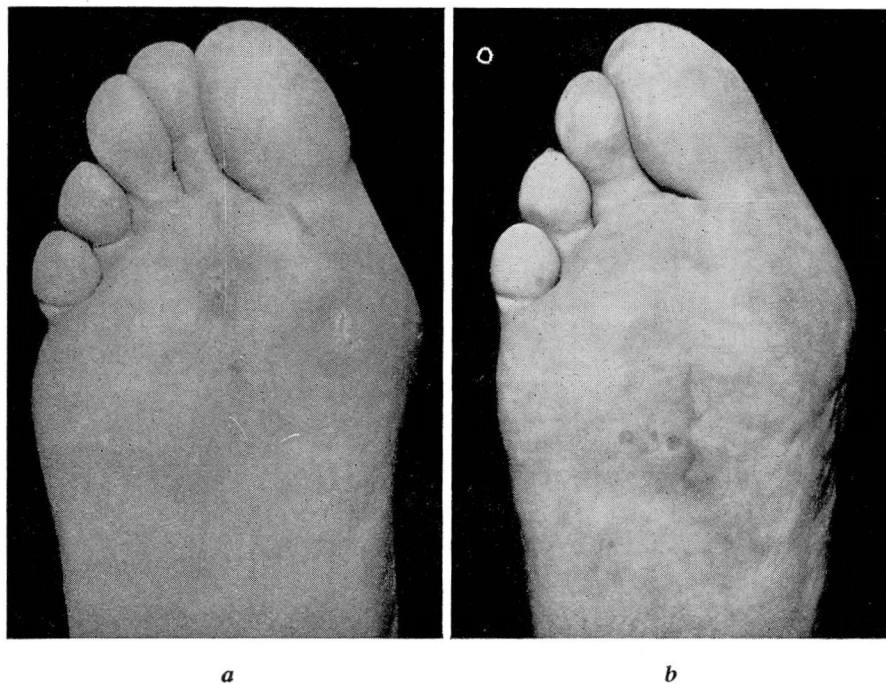


FIG. 3. Case 2. (a) Condition of foot before, and (b) after operation.



would bring about the desired effect. This operation would allow primary closure without tension and eliminate the use of grafted skin. Removal of the metatarsal bone would convert the operative site into a non-weight-bearing area, and healing without a painful scar would be accomplished.

At first it seemed heroic treatment to remove a section of the foot to cure a wart, but these intractable warts are serious problems and require radical treatment.

In 1940 a patient with a large warty ulceration on the plantar surface under the head of the second metatarsal bone, having sought relief for years, begged for an amputation of her foot so that she might walk again without constant pain. Amputation of a toe together with the adjoining metatarsal bone was a conservative procedure in comparison with her request. This afforded an opportunity to try this procedure which I felt had many factors to commend it.

A wedge, or so-called "pie" operation, was carried out (fig. 1), removing the wart in its entirety together with toe and metatarsal bone. Closure was readily accomplished, anchoring together the heads of the first and third metatarsal bones with chromic gut sutures. Such an excellent and satisfactory end result was obtained that I have performed the same operation many times with results so uniformly gratifying that I feel it is the treatment of choice in many of these troublesome conditions.

In this presentation I wish to show 2 cases of the series so treated. Both these cases had the papillomatous growths under the head of the second metatarsal.

**Case 1**—A woman, 40 years of age, had a large, ulcerated, painful area on the ball of her foot for years. She had had many types of treatment, including cautery, trimming, and x-ray. At the time of examination she had a draining sore which had been present for over a year. Further x-ray treatment was felt to be contraindicated. Figure 2 (a) shows condition of foot before and (b) after operation. No tendency to cicatricial formation is evident in the scar.

**Case 2**—A woman, 23 years of age, had been having treatment for a plantar wart for a six-year period. She had had 8 surgical removals in addition to x-ray therapy and radium. Figure 3 (a) shows condition of foot before and (b) after operation. The scar is soft and pliable.

## SUMMARY

The loss of the toe and accompanying metatarsal bone did not appear to interfere in any way with the normal function of the foot. In both cases it will be noted that postoperatively there is a soft, pliable scar. The weight-bearing surface is much more satisfactory than when grafts were used to bridge the defect.