

# SULFADIAZINE ANURIA

## *Report of a Case*

W. J. ENGEL, M.D.

Renal damage and anuria, in patients being treated with the sulfa drugs, may be the result of true toxic injury to the renal tubules or of urinary obstruction. The latter, in turn, may be intrarenal or ureteral. The case presented represents an example of the latter.

### CASE REPORT

A 61-year-old man reported to Cleveland Clinic on January 2, 1946, complaining of a swelling in the neck. This was thought to be a branchial cleft tumor, probably carcinoma, and operation was performed on January 4. The tumor was found to be partially cystic, but the hard, infiltrated wall could not be entirely removed, so the wound was packed open. On January 6 a secondary closure was made, and the patient was put on sulfadiazine, 1 Gm. every four hours, as a prophylactic measure against infection.

On January 9 at 4 a.m. the patient complained of painful distress in the suprapubic region and was unable to void. The administration of prostigmine and other ordinary measures for inducing urination were ineffectual. Catheterization disclosed no urine in the bladder.

Urological consultation was requested. The man was in acute distress with pronounced suprapubic pain and vesical tenesmus. The bladder was not palpable. There was tenderness in the suprapubic region with slight tenderness in the costovertebral angles. With the history of anuria and pain, bilateral ureteral obstruction was suspected and immediate cystoscopy advised.

Cystoscopy was carried out under pentothal anesthesia. There was no urine in the bladder. Inspection revealed an acutely reddened and edematous mucosa with numerous white clusters of crystals lying on the floor of the bladder. Projecting from each ureteral orifice was a bulging white mass of crystals, more pronounced on the right than on the left side (figure). After some manipulation the masses were dislodged, and packed crystals were found to extend up the ureter for a distance of about 1 cm. When these were finally passed, urine was obtained through the ureteral catheters. These were taped in for indwelling catheter drainage and a minimum of 3000 cc. of intravenous fluids ordered for that afternoon and evening.

On the day of cystoscopy the blood sulfadiazine level was 3.5 mg. per cent, the urea was 36 mg. per cent, and the white blood count 9700 with 13.0 Gm. of hemoglobin.

During the succeeding twenty-four hours the patient secreted 1850 cc. of urine and the catheters were removed. Recovery was uneventful, with daily urinary output above normal for the following three days.

### DISCUSSION

Cases of this type have been reported frequently in the literature, and doubtless many others have occurred. I encountered several almost identical cases during my service in the Navy, and all responded to prompt cystoscopy and ureteral catheterization with uneventful re-

covery. Anuria is not limited to the use of sulfadiazine but occurs also when sulfathiazole or sulfapyridine is administered.

The incidence of this complication would seem rather low when one considers the large number of patients treated with the sulfonamides. Finland, Strauss, and Peterson<sup>1</sup> reported only one case of anuria due to ureteral obstruction in 446 patients treated with sulfadiazine.

Obstruction by crystals should be suspected whenever a patient who is on sulfonamide therapy has oliguria or anuria, for typical ureteral colic is not always present. In most cases there will be antecedent hematuria, usually microscopic, and crystals may be found in the urine,

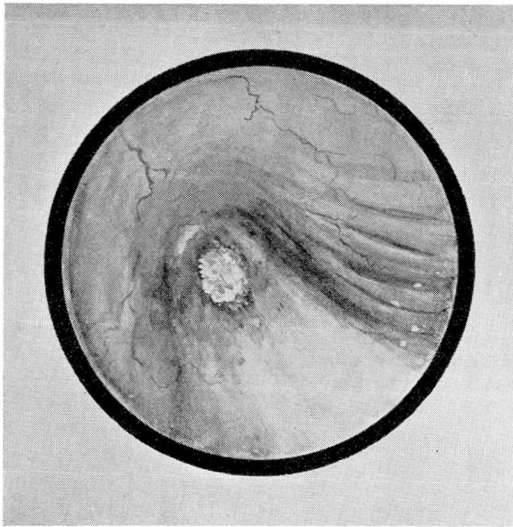


FIG. View of right ureteral orifice showing crystalline impaction.

though failure to find them by no means excludes the condition. Symptoms generally attributed to renal or ureteral colic often will be present with pain and costovertebral tenderness. I have seen vesical tenesmus, so predominant in the case here presented, in one other patient, and in such cases acute urinary retention is usually suspected. The tenesmus is due to trigonal irritation and generally indicates obstruction in the lowermost part of the ureter. However, in any patient who develops anuria while taking sulfonamides, should all signs and symptoms fail to establish the diagnosis, immediate cystoscopy and ureteral catheterization should be performed.

The mechanism by which these obstructing concretions of sulfonamides develop is not completely understood, though certain observations

appear pertinent. It is not directly related to dosage or blood sulfa level, for it has been reported with patients on small dosage and with relatively low blood levels. In our case the blood level was only 3.5 mg. per cent. In a fatal case of sulfathiazole anuria, Prien, Crabtree, and Frondel,<sup>2</sup> by means of the polarizing microscope, identified the crystals in the renal tubules as acetyl-sulfathiazole. It is generally accepted that these obstructing concretions consist largely of the acetyl crystals.

The factors which influence the deposition of these crystals and concretions are:

1. Concentration of the drug in the urine, depending upon
  - a. volume of fluid passing through the kidneys,
  - b. renal function,
  - c. blood level and dosage,
  - d. urinary stasis.
2. Degree of acetylation of drug.
3. The hydrogen ion concentration of the urine.
4. Temperature of urine.

The value of giving alkalis to increase the hydrogen ion concentration of the urine has been shown in several reports, and it has been demonstrated that the crystals are more soluble in an alkaline solution. Jensen and Fox<sup>3</sup> state that the solubility of sulfonamide crystals is minimal at 5.6 pH to 6.6 pH; it is doubled or tripled at 7.5 pH and increased tenfold at 8.0 pH. Schwartz and co-authors<sup>4</sup> studied the urine of patients on sulfathiazole and sulfadiazine with and without the administration of alkali. With sulfadiazine they reported crystals (graded 1 plus to 3 plus) in 25.3 per cent of patients not taking alkali and only 16.7 per cent when soda was given. The respective figures for sulfathiazole were 67.8 per cent and 35.7 per cent. Although the giving of alkalis may be of some value, in my opinion it cannot be relied upon to replace an adequate fluid intake and output. At least two of the patients I saw were taking sodium bicarbonate with the sulfonamides when the ureteral obstruction occurred.

An adequate fluid intake is the single most important preventive of this complication and a necessary corollary is an adequate urinary output, which should never fall below 1500 cc. daily and should be greater if possible. If the concentration in the urine is kept below the level of saturation at any given hydrogen ion concentration, there is little danger of crystalline deposits causing obstruction. Furthermore, it would appear

that the more rapid flow of fluid through the kidneys would reduce the possibility of stasis. It seems reasonable to believe that tubular impaction of crystals may follow in a retrograde manner after urinary stasis has been created by concretions obstructing the ureters or the collecting tubules. This same opinion has been expressed by Prien, Crabtree, and Frondel.<sup>2</sup> They report a case in which sections of the kidney under the polarizing microscope showed acetyl-sulfathiazole crystals in the papillary ducts in the renal papilla but none higher in the collecting or convoluted tubules. Two factors thus appear necessary for crystalline impaction, stasis and reabsorption of water in the convoluted tubules producing a supersaturated solution of a rather insoluble salt. Each of these factors may be controlled by an adequate fluid intake.

The treatment of this type of obstructive anuria, once recognized, is immediate cystoscopy and ureteral catheterization with lavage of the renal pelvis. Even if only one ureter can be catheterized, that will suffice, providing a flow of urine is obtained. Failing in this, pyelostomy or nephrostomy is indicated. The time factor appears to be important, for of 5 cases reported by Smiley,<sup>5</sup> 3 seen within twenty-four hours of the onset of anuria were relieved by ureteral catheterization, while in 2 patients seen thirty-six and seventy-two hours after the onset of symptoms, ureteral catheters could not be passed. Nephrostomy was required in one, and the other finally recovered by forcing fluids and administration of alkalis. This latter patient must have passed his concretion spontaneously. Renal decapsulation has also been reported with success, but in the reported cases pyelostomy was also done.

It is evident that the drug must be discontinued and fluids forced by the intravenous or any other route. There is usually a temporary lag in urinary secretion, but by the end of twenty-four to forty-eight hours there is a polyuria. The ureteral catheters are left indwelling until restoration of urine secretion is assured. This usually occurs in twenty-four to forty-eight hours. To leave them in position too long is inadvisable, for crystals may then obstruct the lumen of the catheter.

This complication is preventable and need not occur if proper attention is paid to the urinary output. This should be accurately measured in all patients receiving sulfonamides, and if it falls below 1500 cc., parenteral fluids should be given in addition to fluids by mouth. Daily urinalyses should be done, for the presence of red blood cells or crystals indicates that fluids must be forced.

### CONCLUSIONS

1. Anuria due to the administration of sulfonamides is an emergency demanding prompt cystoscopy and ureteral catheterization.

2. Obstructing concretions of sulfonamides can usually be relieved by ureteral catheterization and lavage of the renal pelves. If the obstruction cannot be passed, pyelostomy should be done without delay.

3. Adequate fluid intake and urinary output are the best safeguards against this complication.

4. Simultaneous administration of sodium bicarbonate when giving sulfonamides is desirable.

#### REFERENCES

1. Finland, M., Strauss, E., and Peterson, O. L.: Sulfadiazine—Therapeutic evaluation and toxic effects on four hundred and forty-six patients. *J.A.M.A.* **116**:2641 (June 7) 1941.
2. Prien, E. L., Crabtree, E. G., and Frondel, C.: Mechanism of urinary tract obstruction in sulfathiazole therapy; identification of crystals in tissue by polarized light. *J. Urol.* **46**:1020-1032 (Nov.) 1941.
3. Jensen, O. J., and Fox, C. L.: Hydrogen ion concentration and the solubility of sulfonamides in urine; the relation to renal precipitation. *J. Urol.* **49**:334 (Feb.) 1943.
4. Schwartz, L., Flippin, H. F., Reinhold, J. G., and Domm, A. H.: The effect of alkali on crystalluria from sulfathiazole and sulfadiazine. *J.A.M.A.* **117**:514 (Aug. 16) 1941.
5. Smiley, L. V.: Suppression of urine complicating sulfadiazine therapy. *U. S. Nav. M. Bull.* **44**:328-332 (Feb.) 1945.

## SURGICAL TREATMENT OF INTRACTABLE PLANTAR WARTS

J. A. DICKSON, M.D.

The majority of plantar warts are successfully eradicated by conservative measures such as escharotic solutions, electro-desiccation, or irradiation in the form of x-ray. Comparable results are obtained by each of the above methods, 60 per cent to 90 per cent cures. Escharotics are reserved for simple cases, and electro-desiccation and irradiation are employed when local application of these substances fails. If a single method is desired, the selection would undoubtedly be x-ray, for this treatment is painless, short, successful, and safe, provided the treatment is administered with due respect to the tolerance dose.

It is recognized, however, that no matter how skillfully used, these methods fail in at least 10 per cent of cases. These intractable problems are not only distressing but often calamitous to the patient. After many years of therapy extremely painful ulceration on the plantar surface of the foot may still persist. This ulcer invariably extends through the deep fascia, and the dermatologist and roentgenologist feel they have run the