

# RETROPERITONEAL TUMOR

## Fibrosarcoma of the Adrenal

### *Report of a Case*

CHARLES C. HIGGINS, M.D.

In recent years many cases of adrenal tumors originating in the cortex or medullary portion of the gland have been reported. In the presence of an abdominal mass and clinical signs of adrenal hyperactivity a tentative diagnosis of adrenal tumor may be made. Nonrenal retroperitoneal tumors may be (1) parietal retroperitoneal tumors arising from the walls and mesothelial structures of the retroperitoneal space or (2) unattached retroperitoneal tumors usually arising from the mesonephron or the gonad. A case is reported in which a retroperitoneal tumor, probably arising from the adrenal gland, displaced the gallbladder to the left upper abdominal quadrant and the right kidney below the left kidney. The viscera, gallbladder, and right kidney returned to their normal positions after the tumor was removed. The site of origin was difficult to determine from the gross and microscopic study of the tumor.

### CASE REPORT

A woman, aged 74, was admitted to the clinic on December 11, 1944 complaining of a painful mass in the right side of the abdomen. Symptoms began one year previously, when after an attack of pneumonia pain occurred in the right kidney region. She observed the presence of a mass, which progressively enlarged until it occupied the entire right half of the abdomen. During the past year her weight dropped from 173 to 140 pounds. She was forced to go to bed frequently because of weakness. The patient had no other complaints.

Physical examination revealed a fairly well nourished woman. The size and shape of the abdomen immediately attracted attention. Temperature was 98.6 F., pulse rate 80 per minute, respirations 20 per minute, and the blood pressure 185 mm. of mercury systolic and 105 mm. of mercury diastolic. A large firm mass occupied the entire right side of the abdomen and was slightly movable and somewhat tender to deep pressure. The mass extended from under the ribs to below the anterosuperior spine and was smooth with the exception of two large nodules on the anterior surface.

**Roentgenologic studies.** An initial roentgenogram revealed a large laminated calculus in the left upper abdominal quadrant and a homogeneous, fairly dense shadow on the right side of the abdomen. No gas shadows were present in this area.

A retrograde pyelogram showed the left kidney at a level lower than normal, the upper pole being at the second lumbar vertebra (fig. 1). The right ureter crossed the sacrum and entered the right kidney, which lay below the left. A large mass occupying the right side of the abdomen had displaced the bowel to the left and into the pelvis (fig. 2a). It could not be stated with certainty whether the two kidneys on the left were joined with anomalous ureters or whether the right kidney was displaced far to the left by the enormous mass.

## RETROPERITONEAL TUMOR

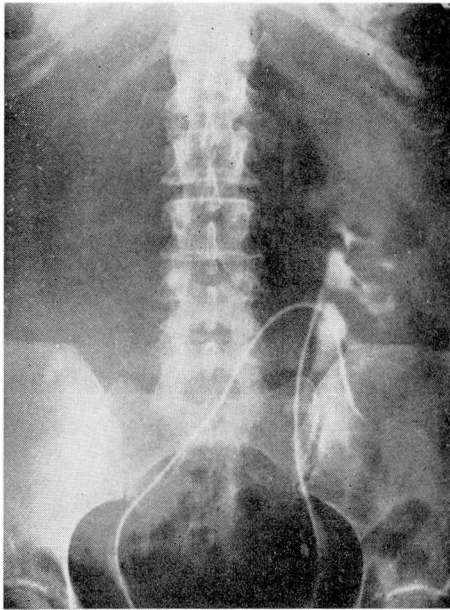


FIG. 1 Retrograde pyelogram showing left kidney at lower than normal level and right ureter crossing sacrum and entering right kidney, which has been displaced below the left.

On roentgenologic examination the transverse and ascending portions of the colon were displaced downward and toward the midline by the large right abdominal mass, and the lower pole of the stomach was three inches below the iliac crest (figs. 2b and c). The mediastinum and aorta were normal, and the heart was normal in size, shape, and position. The left lung was normal, but the right lung showed exudative and calcific infiltration, and a diagnosis was made of probable bronchitis.

The large mass, filling the right side of the abdomen and extending across the spine, had displaced the gallbladder, stomach, and intestine far to the left and probably had displaced the right kidney to its position below the left kidney. It did not seem unreasonable to assume that the lesion was an unusually large retroperitoneal sarcoma.

### Laboratory Data

#### Urine

Specific gravity—1.020  
Alkaline reaction  
Albumin—1 plus  
Sugar—none  
Microscopic examination—  
occasional white blood cell

#### Blood

Hemoglobin—85 per cent  
Red blood cells—4,130,000  
White blood cells—6500  
Urea—24 mg. per 100 cc.  
Sugar—116 mg. per 100 cc.  
Wassermann reaction—negative

**Operation** (December 15, 1944). Through the usual kidney incision a large retroperitoneal tumor was exposed. It was mobilized with considerable difficulty and

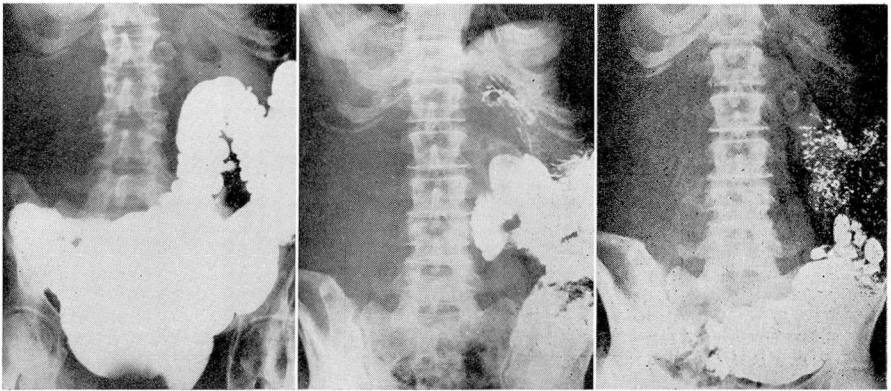


FIG.2(a)Roentgenogram showing transverse and ascending portions of the colon, displaced downward and toward the midline by the large right abdominal mass, and calculus in gallbladder, also displaced to the left.  
(b) Roentgenogram after barium meal. Stomach is three inches below iliac crest. Jejunum and duodenum are filled with barium.  
(c) Roentgenogram after barium meal. Barium fills small bowel. Calculus in displaced gallbladder.

was quite adherent in the region of the aorta and vena cava. By sharp dissection the mass was freed from these structures and removed. Two cigaret drains were inserted, and the wound was closed.

The patient was discharged from the hospital January 4, 1945 in satisfactory condition.

#### Pathologic report\*

**A. Gross.** The specimen is a large ovoid mass weighing 2250 Gm. and measuring 19 by 14 by 12 cm. The exterior is formed by a gray, partially opaque, slightly roughened capsule to which are adherent small masses of adipose tissue and one cordlike strand. The capsule is mottled with areas of red, yellow, and blue-gray. Parallel sections show bulging, moist, and irregularly, coarsely, and indistinctly lobulated cut surfaces formed in variegated tissue, which is mainly pinkish gray. Scattered through it are slightly protruding, indistinctly delimited, nodular masses, which are more gray and opaque than surrounding reddish gray translucent tissue. There are small to large portions which are yellow, opaque, and friable, and other portions which are softer, semitranslucent, and greenish gray. There are also roughly and smoothly lined cysts up to 2.7 cm. in maximum diameter containing clear yellow and greenish yellow fluid. In and immediately beneath the capsule are several elongated patches of orange-yellow opaque tissue suggestive of adrenal cortex. Sections through these portions show a thin subcapsular layer of orange-yellow opaque tissue up to 1 mm. thick.

**B. Microscopic.** Numerous sections show a well encapsulated mass with portions of compressed adrenal cortex in parts of the capsule. The mass is varied in structure but in general shows about equal amounts of cells and intercellular fibrillar material. The cells, moderately large, vary greatly in shape. Some are fusiform, arranged in bundles,

\* This report was made by Dr. C. M. Blumenfeld, Department of Pathology, University Hospitals, Cleveland.



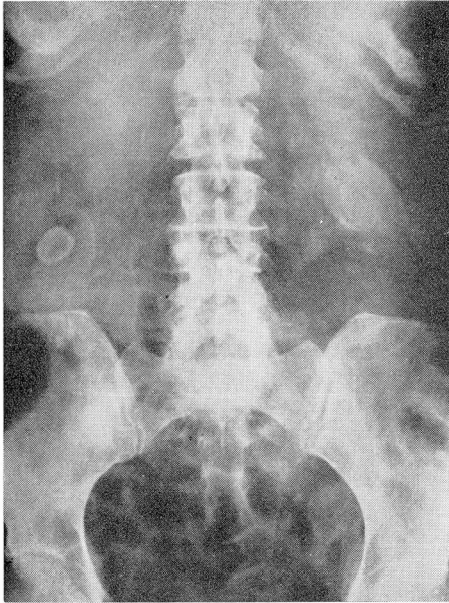


FIG. 3 Postoperative roentgenogram showing gallbladder and right kidney returned to normal position.

but more are arranged in no regular pattern, their shape being obviously pleomorphic, being round, oval, polygonal, stellate, and irregular. Some sections show cells closely packed without visible intercellular substance, forming short, irregular, in part anastomosing trabeculae, which tend to center about small thin-walled vascular spaces, from which they are separated by pale eosinophilic or fibrillar material. In various portions of the mass, but particularly in the more richly cellular part, there are occasional bizarre giant cells, round, oval, or irregular, with multiple nuclei, sometimes centrally clustered, sometimes arranged in a complete or incomplete peripheral ring. In general the nuclei are slightly to severely hyperchromatic and composed of a coarse network of chromatin. Only occasional large nucleoli are seen. The cytoplasm is eosinophilic and varies from homogeneous to commonly irregularly vacuolar and granular. There is a moderate number of normal and abnormal mitotic figures. Vascularization varies from poor to moderate and is principally by vessels of sinusoidal type with large lumens and walls of endothelium only. In some places vascular spaces are formed by tumor cells. Large portions show degeneration and necrosis. Where portions of the periphery of the mass are included, there is a thick capsule of poorly cellular, dense, coarse, collagenous, fibrous tissue, partially hyalinized. Selected parts include portions of adrenal cortex showing the usual vacuolated cells in cordlike arrangement compressed in a pattern tangential to the mass. In most places the cortical spaces are separated from the tumor by capsular tissue, but in a few, isolated nests of cortical cells approximate the neoplastic cells. Van Gieson's preparations show abundant material staining like collagen, in part disposed as coarse bundles between groups of cells and in part as fine fibers intimately related to and placed between individual cells. In general

mucicarmine preparations are not positive, but in some parts, particularly where degeneration and necrosis are seen, fine and irregular fibrils stain moderately deep red.

Bodian preparations of two selected portions show a few, short, isolated, impregnated fibrils, which are not related to the tumor cells but lie free in the intercellular substance. In the regular preparation a selected portion shows bundles having the appearance of smooth muscle cells in cross section; a van Gieson preparation shows these bundles stained yellow. Tumor is located on one side of these bundles and capsular tissue on the other side.

**C. Comment.** Lack of organoid differentiation, pleomorphism of cells, and moderate numbers of normal and abnormal mitotic figures indicate that this is a malignant tumor. Presence of compressed adrenal cortex in portions of the capsule indicates an intimate relation with the adrenal gland. However, the tumor may have arisen from the retroperitoneal tissue and as it expanded may have caused compression atrophy and inclusion of the adrenal gland in its capsule. Thus, although intimate relation of the tumor and adrenal gland strongly suggests adrenal origin, retroperitoneal origin cannot be finally excluded. The abundance of collagen, as demonstrated by van Gieson's preparation, its wide distribution, and its intimate relation to the tumor cells indicate that it is a product of them and not merely stroma. In appearance the cells differ from fibroblasts seen in average fibrosarcoma, and many portions of the tumor show a peritheliomatous arrangement unlike that seen in ordinary fibrosarcoma. The short segments of intercellular fibrils impregnated by Bodian preparation cannot be construed as indicating that the tumor is of neural origin. The fibrils may be nerves of the tumor rather than products of tumor cells. The bundles of smooth muscle are like those seen in the wall and major branches of the adrenal vein. The presence in one section of such smooth muscle bundles on one side and of tumor capsule on the other side suggests that the tumor may have grown into and in a large part obliterated the wall of either the main central adrenal vein or a tributary.

In conclusion it may be stated that morphologic evidence favors adrenal origin but does not exclude the possibility of retroperitoneal origin. Neural origin also cannot be excluded, but demonstrated features are consistent only with a diagnosis of fibrosarcoma, adrenal cortex being derived from mesoderm (mesothelium). It is also impossible to exclude origin from adrenal cortex with assumption by the altered tumor cells of fibroblastic potency.

**Postoperative roentgenograms** demonstrated a large gallbladder calculus on the right side of the abdomen above the crest of the ilium (fig. 3). The intravenous urogram showed prompt function from both kidneys, which lay low with the lower poles at the level of the iliac crests. The right kidney had shifted to the right. The bladder appeared normal.

## SUMMARY

In this case a large retroperitoneal tumor probably arising from the adrenal gland had attained sufficient size to displace the gallbladder to the left side of the abdomen and the right kidney to a position below the left kidney. Great displacement of the other viscera was evident. Exploratory surgery is valuable when such a lesion appears clinically to be inoperable. As is demonstrated in this case classification of non-renal retroperitoneal tumors from the gross and microscopic study of the tumor is difficult.