

brought into position, and the wire threaded 2 or 3 inches into the upper fragment. The end of the wire was cut and turned upwards over the outer surface of the bone. A similar procedure was carried out for the fracture of the ulna, but this time the wire was inserted into the upper fragment of the ulna and passed across the fracture line into the lower fragment. The results of the procedure are readily demonstrated in the x-ray photographs (figure 1).

The tissues were allowed to fall back into position and the wounds closed. A light, rather loosely fitting cast was applied from the palm to the midupper arm. The usual postoperative care was given, and when satisfactory callus formation was obtained, the child was allowed normal function. At the end of the third month a small incision was made over the hooks of the Kirschner wires under local anesthesia and the wires readily removed. The results are shown in figure 2.

Case 2. A boy, aged 13, also had two manipulations under anesthesia before he was referred to me, and further attempts at closed reduction were deemed inadvisable. In this particular case after reduction of the radius the ulna came into such excellent position that insertion of the second wire into the ulna was not thought to be necessary. The position obtained and the excellent callus formation are shown in figure 3.

SUMMARY

Intramedullary fixation by means of Kirschner wires is an excellent procedure for fractures of the forearm which are not satisfactorily reduced by manipulation alone. When open operation is believed necessary, this method is much simpler than the use of metal plates. There is no stripping of the periosteum, and the fracture ends are maintained in the most favorable position for repair. This also affords a certain amount of impaction at the fracture site, which stimulates callus formation. The method is simple in application and should produce a perfect anatomic result with the minimum possibility of any complications. It has the added advantage that the internal fixation can readily be removed when it has served its purpose.

PROTRUSION OF INTERVERTEBRAL DISK

A Common Cause of Sciatica

W. JAMES GARDNER, M.D.

Since the days of *Pithecanthropus erectus*, man has been paying for the privilege of walking on his hind legs. Nature designed the human body for four-legged locomotion, and evolution has not yet accomplished the structural changes required by this relatively new mode of progression. As a result, certain inherent anatomic weaknesses are expressed in the form of peculiarly human maladies. Some of the more common are flat feet, varicose veins, hemorrhoids, cystocele, hernia, backache, and sciatica. The latter condition is usually due to

INTERVERTEBRAL DISK

posterior protrusion or rupture of the intervertebral disk immediately above or below the fifth lumbar vertebra.

A knowledge of the anatomy of the parts is necessary for an understanding of this condition (fig. 1). The mammalian spine consists of bony vertebrae separated by intervertebral disks. These cartilaginous structures are designed to give flexibility to the spine but not to bear weight. Along the anterior surface of the bodies of the vertebrae runs the longitudinal anterior spinal ligament, which is very dense and strong. The posterior spinal ligament is a less dense structure running longitudinally along the posterior surfaces of the vertebral bodies within the spinal canal. The intervertebral disk consists of two cartilaginous plates which

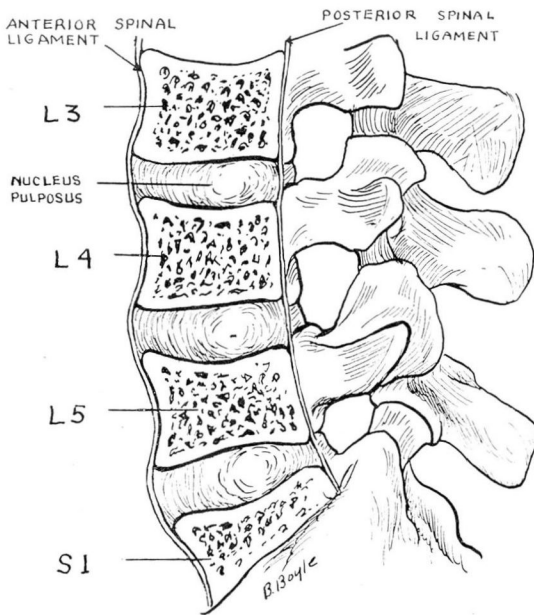


FIG. 1. Anatomy of mammalian spine showing vertebrae separated by intervertebral disks.

are adherent to the flat surfaces of the bodies of the adjoining vertebrae. The nucleus pulposus is an ovoid, semigelatinous cushion in the center of the disk, surrounded by the dense, heavy fibers of the annulus fibrosus. This annulus is thicker in front and at the sides than at the back, where together with the thinner posterior spinal ligament it forms the anterior wall of the spinal canal. The relative thinness of the posterior portion of the intervertebral disk and of the posterior spinal ligament explains the frequency with which the disk bulges posteriorly when it is compressed. These anatomic considerations also explain why protrusion of an intervertebral disk is almost invariably produced by

trauma exerted in the long axis of the spinal column and seldom, if ever, by a direct blow to the back. Since the lower portion of the spine sustains the most weight, the most frequent site of the protrusion is between the fifth lumbar vertebra and the sacrum. The next most frequent site is between the fourth and the fifth lumbar vertebra, and in perhaps 2 or 3 per cent of the cases the protrusion is between the third and the fourth lumbar vertebra (fig. 2).

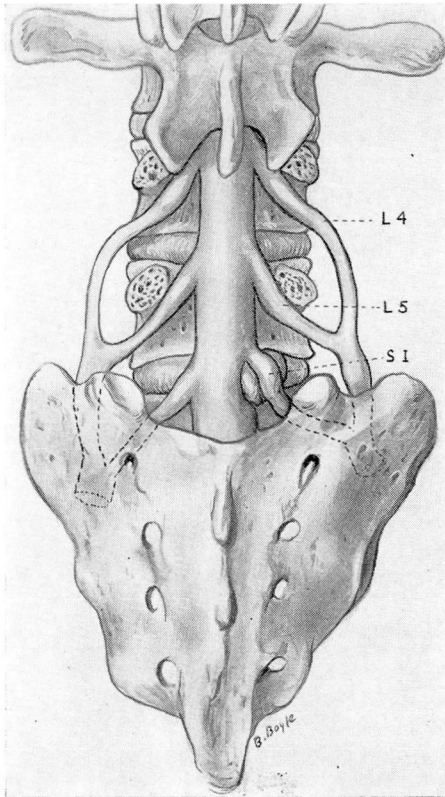


FIG. 2. Protrusion of disk between fifth lumbar vertebra and the sacrum causing pressure on first sacral nerve root.

The protrusion causes pain by compressing the nerve root above its point of exit through the intervertebral foramen. A protrusion of the disk between the fifth lumbar vertebra and the sacrum causes pressure on the first sacral nerve root; between the fourth and the fifth lumbar vertebra, on the fifth lumbar root; and between the third and the fourth lumbar vertebra, on the fourth lumbar root. Since the sciatic nerve is composed of fibers which leave the spinal canal with the third, fourth, and fifth lumbar nerve roots and the first and second

INTERVERTEBRAL DISK

sacral nerve roots, a protrusion at any of these three levels gives rise to pain in the distribution of the sciatic nerve.

Mixter and Barr¹ in 1934 first described the clinical picture of protrusion of the intervertebral disk. Prior to that time many neurologic surgeons operated upon patients with the clinical picture of tumor of the cauda equina and found a mass of cartilaginous tissue attached to the anterior wall of the spinal canal. This was usually considered to be a chondroma rather than an extrusion of the disk. Nowadays it is the rare case of protruded disk which progresses to the stage where it causes paralysis of the cauda equina.

Protrusions of the intervertebral disk are more common in men than in women, undoubtedly because a man does heavier work than a woman. The lesions are most common in the fourth and the fifth decade. In about half the cases there is a definite history of trauma, in the remaining half the patient can attribute the onset of the symptoms to no particular trauma or strain.

HISTORY

A typical case history follows:

A man, aged 45, while lifting a heavy object suddenly feels something snap in his back. He has severe pain in the lower back and is unable to straighten up completely. After several days' rest in bed the pain gradually begins to subside, and in a few weeks he is back at work. Some months or years later he again experiences a pain in his back, with or without trauma, this time associated with a severe, sharp pain down the back of the thigh and calf on one side. Similar attacks recur at intervals of several months and may become progressively more severe and persistent. The patient states that the pain is increased by coughing, sneezing, and straining at stool. It is aggravated by bending over, and the patient does not attempt to carry any weight or to do heavy lifting. After he has been on his feet for a time, he may become aware of a numbness and tingling in the foot on the painful side. Lying down produces some relief, but even turning over in bed may be exquisitely painful.

FINDINGS

On examination the patient walks in a guarded fashion and with a limp of the affected leg. He lies down upon and arises from the examining table with great caution. When he stands the trunk is inclined to one side. The normal lumbar lordosis is lost so that the lumbar spine is flat. There is spasm of the lumbar muscles, and the patient bends forward from the hips with very little flexion of the lumbar spine. Extension and

lateral bending of the lumbar spine are usually less restricted than forward bending. There is tenderness on deep pressure over the fourth or the fifth lumbar spinous process or beside them on the same side as the sciatica. The sciatic pain is aggravated by straight leg raising, and Lasègue's sign is positive on the affected side. The affected calf is slightly smaller in circumference, and the achilles tendon reflex is absent. There is slight weakness in flexion and extension of the great toe. On careful testing with a pin slight impairment of pain perception on the outer side of the foot is revealed. When a blood pressure cuff is placed about the patient's neck and inflated to a pressure of 40 mm. of mercury with the patient standing, the sciatic pain and tingling are usually increased. Given this sort of history and these clinical findings, the diagnosis is almost unquestionably a protruded intervertebral disk.

I have found the following chart of decided help in determining which cases of low back ache and sciatic pain are caused by protrusion of the intervertebral disk.

HISTORY	FINDINGS
Type of injury	Lumbar spine
Number of previous attacks	Contour normal
Duration of present attack	Increased lordosis
Aggravating factors	Diminished lordosis
Coughing	List to one side
Sneezing	Limitation of flexion
Straining	Location of tender points
Stooping	Atrophy
Sitting	Calf
Lifting	Thigh
Standing	Gluteus
Walking	Weakness of big toe (flexion, extension)
Relieving factors	Patellar reflex
Location of pain	Achilles tendon reflex
Location of numbness	Pain on straight leg raising
	Jugular compression test
	Location of hypalgic area

X-ray usually shows little abnormality of the lumbar spine except flattening of the normal lumbar curve. Evidence of narrowing of one of the intervertebral disks is of little significance in indicating the site of the protrusion. The dynamics of the spinal fluid are normal except in the rare case of a large protrusion completely obstructing the lower end of the lumbar sac.

If a diagnostic lumbar puncture is done, the needle should be introduced between the fifth lumbar spinous process and the sacrum;

INTERVERTEBRAL DISK

at this level the protein content is most likely to be increased. Two cc. of spinal fluid should be removed as soon as the needle is inserted and before the pressure manometer is connected in order to obtain a specimen unmixed with fluid from a higher level. This specimen is sent to the laboratory for total protein estimation. The manometer is then connected. The Queckenstedt test usually demonstrates no evidence of block. Another specimen of spinal fluid is then withdrawn for complete study. The protein content may be a little lower in the second specimen than in the first because it is diluted with fluid from above the lesion. In about half the cases of protruded disk the total protein content of the spinal fluid is increased to between 40 and 100 mg. per 100 cc.

In the early years of surgery of the intervertebral disk most operators preferred to verify the presence and location of the protrusion by means of lipiodol or air myelograms. Nosik² found that thorotrast is a more accurate contrast medium than lipiodol or air. His method gives excellent delineation of the lower portion of the spinal canal. However, after using thorotrast for several years without ill effect, early in 1943 some sharp reactions occurred in patients immediately following its injection. The use of the material has therefore been discontinued.

With the discontinuance of myelography diagnostic accuracy as judged by the operative findings has not suffered. However, there is no doubt that many patients with protruded intervertebral disks in whom the clinical picture is not quite definite are denied the relief which an operation could give them if an entirely dependable method of myelography were available.

TECHNIC OF OPERATION

The operation for protrusion of the intervertebral disk is carried out in the Neurosurgical Division as follows:

The patient is placed in the prone position on the operating table with a firm bolster extending from shoulder to iliac crest on each side. This provides a shallow trough for the chest and abdomen so that respiration is free and venous pressure is low. Intravenous pentothal anesthesia is administered. A linear incision is made from the third lumbar to the second sacral spinous process. The muscles are dissected from the lumbosacral spine on the side of the sciatica. The fifth lumbar spinous process and the lamina on the side of the pain are removed. The ligamenta flava above and below the fifth lumbar lamina are dissected out. By palpating the dura the operator can readily detect the firm swelling produced by the protrusion at either the fourth or the fifth interspace. The dural sac is retracted toward the midline,

and the dural sleeve containing the nerve root is exposed. The nerve is found to be stretched and flattened by a mass bulging beneath it (fig. 3-a). The nerve is retracted toward the midline from the dome of the swelling, and the firm, pale, elastic protrusion covered by the posterior spinal ligament is exposed (fig. 3-b). It is placed laterally but extends almost to the midline. With a sharp pointed scalpel the posterior spinal ligament is incised over the dome of the swelling, and a ragged fringe or mass of white fibrocartilaginous material protrudes through the incision. This is seized with grasping forceps and extricated. After the protruding portion of the disk has been removed in this fashion, a sinus leading into the interior of the disk is disclosed. The grasping forceps are introduced into this sinus, and additional loose fragments of cartilage are removed. A bone curette is then introduced into the sinus, and the cartilaginous plates above and below are curetted (fig. 3-c). Bleeding points in the extradural venous plexus are controlled by electrocautery

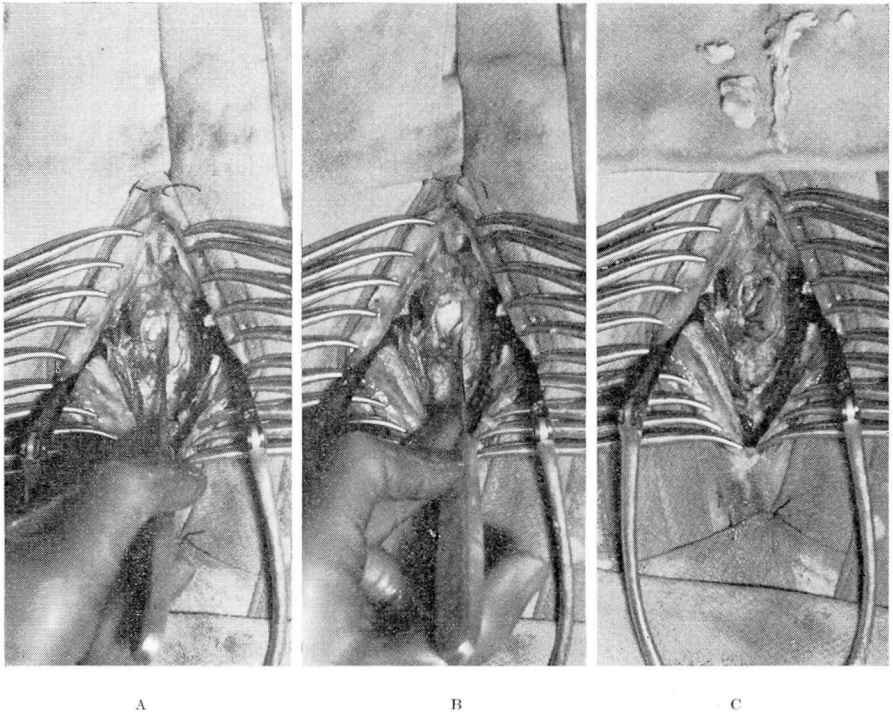


FIG. 3. Operative exposure of protruded intervertebral disk on the left side at the lumbosacral level. (a) Dural sac retracted to show the nerve sleeve flattened by the bulging mass beneath it. (b) The nerve sleeve retracted showing the dome-shaped swelling covered by the posterior spinal ligament. (c) The pressure on the nerve has been relieved by the removal of the cartilaginous material shown above the operative field.

or by the application of small muscle grafts. The wound is then closed with several tiers of interrupted black silk sutures without drainage. The patient is allowed out of bed on the twelfth day and is discharged on the fourteenth.

COMMENT

In the early days of the operation for protruded intervertebral disk it was customary to do a wide bilateral laminectomy. As surgeons became better acquainted with the lesion they found that it was possible to remove the protruded portion of the disk by simply enlarging the space between the laminae with a rongeur, or even in some instances without removing any bone at all. As is frequently the case, some surgeons went to the extreme and began to pride themselves on the fact that they could treat this condition with the removal of very little or no bone at all. This, to my mind, is a mistake.

I believe that an attempt to treat the condition without adequate exposure is certain to result in some cases in incomplete removal of the protruded portion of the cartilage. I therefore believe that it is better to remove the lamina of the fifth lumbar vertebra on the side on which the patient has pain; if in addition the spinous process of the fifth lumbar vertebra is removed, the exposure will be even better. This approach does not appreciably weaken the spine, it permits adequate exposure of the fourth as well as the fifth interspace, and it largely eliminates the danger of overlooking a second protrusion.

A protruded disk between the third and the fourth lumbar vertebra is rare and can usually be suspected from the clinical picture. In these cases the pain is referred to the shin, and the patellar rather than the achilles tendon reflex is diminished or absent.

The results of operation for a protruded intervertebral disk are usually very gratifying. However, in some cases the pain is incompletely relieved. This is more commonly the case with the backache than with the sciatica. Also, in perhaps 5 per cent of the cases a protrusion may recur, or another protrusion may occur at a different site requiring reoperation.

In some instances, where there is spondylolisthesis or other evidence of an unstable back, a spinal fusion may be performed after the disk has been removed. The adoption of spinal fusions after the removal of protruded disks as a routine measure is still a controversial subject. It must be borne in mind that spinal fusion lengthens the operation, prolongs the convalescence, and should be reserved for those cases in which it is definitely indicated.

In my opinion, the percentage of cases of sciatica ascribed to hypertrophy of the ligamentum flavum or to so-called "concealed disks" is

far too high. More careful selection of cases for operation and more adequate surgical exposure will serve to reduce greatly the percentage of these nebulous causes of sciatic pain.

Operation should not be advised for all patients with the diagnosis of protrusion of the intervertebral disk. It is not advisable to operate unless the patient is in a severe attack which shows no signs of subsiding spontaneously. The surgeon should remember that for thousands of years patients have been recovering from attacks of sciatica without the benefit of surgery and that they will continue to do so. Operation should be reserved for those whose pain is incapacitating and does not respond to conservative measures, or in whom attacks recur at frequent intervals.

REFERENCES

1. Mixer, W. J., and Barr, J. S.: Rupture of intervertebral disc with involvement of spinal canal. *New England J. Med.* 211:210-215 (Aug. 2) 1934.
2. Nosik, W. A.: Intraspinal thorotrast. *Am. J. Roentgenol.* 49:214-218 (February) 1943.

PAGET'S DISEASE OF SKULL COMPLICATED BY MUCOCELE OF FRONTAL SINUSES

Report of a Case

HAROLD E. HARRIS, M.D.

More than sixty years ago Sir James Paget described the bone disease which bears his name. His term, osteitis deformans, which is widely used today seems to me a misnomer; the existence of infection is doubtful and frequently there is no deformity.

In the advanced stages of the disease skeletal changes are striking, with the classic signs of massive head, reduced stature, anteriorly bowed legs, and marked kyphosis. However, advanced cases are uncommon. Less advanced cases in which the disease is localized, often limited to one bone, are seen more frequently. Although the skull has long been considered the site of greatest predilection, the spine and pelvis are frequently involved, as has been demonstrated in recent years by routine x-rays of the gastrointestinal and genitourinary tracts.

Complications. Of the many complications of Paget's disease the occurrence of fractures from minor trauma is the most common