

THE STOMACH AFTER OPERATION

Radiologic Consideration of Types of Operation, Peptic Ulcer, and Neoplasm

FREDERIC E. TEMPLETON, M.D.

Examination of the stomach after operation is one of the most difficult and often most puzzling procedures in roentgenology. In post-operative examinations the roentgenologist deals with an inconstant situation. The types of operation are many and varied, and the results of the same operation, especially if it is performed by different surgeons, may be different in appearance. The purpose of this article is to present the normal appearance after some of the more common operations on the stomach and to describe some lesions, particularly peptic ulcer and gastric neoplasm.

Most gastric operations are performed to remove diseased tissue, to decrease gastric acidity, and to reestablish continuity of the lumen. The many and varied operations devised to obtain these effects are usually performed for peptic ulceration and neoplasm. Since these two lesions are likely to recur, most roentgenologic examinations after operation are made to detect recurrent ulcers and neoplasm. Of the two processes recurrent benign ulceration is the more common. As these recurrent ulcers usually develop about the stoma of a gastro-enterostomy, it is imperative that the roentgenologist be familiar with the different surgical procedures.

It is not my purpose to describe every operation for treatment of benign ulceration or neoplasm, for many operations are rarely used. The discussion is confined to a few popular types employed in the United States.

Many types of operation performed on the stomach may present similar appearances at roentgenologic examination. For instance, it is not always possible to tell whether at the time of a partial gastric resection the continuity of the lumen was reestablished by inserting the cut end of the stomach into the side of the jejunum or by closing the cut end and making an anastomosis between the jejunum and the nearby greater curvature of the stomach.

A. TECHNIC OF EXAMINATION

Even though the examiner is familiar with the type of operation performed, he must begin the roentgenologic examination cautiously. If the patient drinks all the barium mixture quickly, the field becomes flooded, and the examiner has trouble locating the various structures,

particularly the stoma and the loops of intestine which lead to and away from the site of anastomosis.

The examination is best carried out on a standard filming fluoroscope (spot machine), an instrument so designed that fluoroscopic images can be recorded on films as the examination progresses.

The patient is placed in a right, slightly oblique position behind the fluoroscopic screen. He is handed a glass containing about 100 cc. of a barium cream (one-half barium and one-half water by volume) and is requested to fill his mouth with the mixture and then to swallow. If the amount of contrast medium is insufficient to coat the gastric mucosa and to enter the stoma, the patient repeats the dose until the stomach and the stoma are outlined. The flow of medium into the intestine is observed. At the beginning of the examination the barium usually passes through the efferent loop. After this loop has been identified, the patient is requested to take more of the mixture in order to increase the flow. The first few centimeters of this loop are carefully examined; for most recurrent ulcers are found in this area. As the flow of barium increases, the afferent loop fills and also must be identified; for occasionally this may be the site of an ulcer. If the two loops overlap, the patient is turned until the loops are clear of each other. Palpation helps to separate the loops. If the stomach overlaps the stoma and obscures it, the stoma may be seen by pushing the stomach upward or by rotating the patient, usually into a left oblique position.

If the two loops fill simultaneously, it is difficult to distinguish the afferent loop from the efferent. The position of the loops does not aid; for in one patient the afferent loop is medially placed, and in another the efferent. The flow of barium should be followed along the intestine in order to observe the direction of the peristaltic waves. Barium seldom moves in a retrograde manner along the afferent loop beyond the ligament of Treitz; when it does, peristalsis usually carries it back toward the stoma. Barium in the efferent loop is carried by peristalsis into the deeper portions of the intestinal tract.

After the loops are examined with the patient in the right oblique position, the patient is turned to the extreme left oblique or the left lateral position, so that the stoma is seen in profile either along the anterior or along the posterior wall of the stomach. After the stoma and the two loops of the intestine are examined, attention is directed to the stomach. If the barium passes rapidly from the stomach through the stoma, the flow may be blocked by exerting pressure over it with the left hand. The right hand is used to palpate the stomach.

If resection has not been performed and if the jejunum has been anastomosed to the stomach, an attempt is made to force barium

STOMACH AFTER OPERATION

through the pylorus into the duodenal bulb. When the duodenal bulb fills, it is examined for deformity and crater.

The stomach is studied with the patient standing and facing the examiner. The table is then tilted so that he lies in the supine position. The barium in the stomach flows into the fundus. If all the contrast mixture has passed from the stomach, additional barium is given through a drinking tube. After the fundus is studied, the patient is turned to the prone position, and the stomach and intestinal loops are again observed. Unless some shadow suggesting a lesion appears while the patient is still in the horizontal position, the examination is complete. Should there be such a finding, the table is tilted up, the patient given more barium, and the region examined.

As the examination proceeds, with the patient standing first in the left and then in the right anterior oblique positions, films are exposed of the stoma and of the intestine adjacent to the stoma, as well as films of any shadow suggesting a lesion. When fluoroscopy is completed, the patient is placed upon a regular grid table in the prone position with the left side slightly elevated. A 10 by 12 inch film is centered over the stomach and exposure made. A 14 by 17 inch film is also made of the entire abdomen, with the patient lying flat on his abdomen. The latter view provides excellent visualization of the intestine.

B. NORMAL APPEARANCE

The operations described are confined to three general types: (1) those without an anastomosis, but with a closed incision, such as local resection of a lesion or closure of a gastrostomy; (2) those with an anastomosis to the intestine, either with or without resection; and (3) those with an anastomosis to the esophagus.

1. Local repair. In most instances the scar from a local excision or from perforation of a lesion cannot be detected at roentgenologic examination. Much of the deformity observed after repair of a perforated ulcer in the duodenum existed before the ulcer perforated.

In some instances, however, a puckering of the mucosa of the wall of the stomach, resulting from the operation, is seen. As the scar gradually contracts, the puckering is increased. This deformity in itself is not significant. It must be recognized, however, so that it will not be mistaken for another type of lesion, particularly the scar of an ulcer. Here the history of operation is valuable in arriving at the correct interpretation.

Prevot¹ described the appearance of invaginated walls produced by repair of a perforated ulcer of the duodenal bulb. His description of the condition is that which might be expected from study of the surgical

technic. He interpreted a roentgenogram as showing apposing walls of the repaired region protruding into the lumen of the duodenum. I have not encountered such a picture and believe that it is unlikely to occur unless the patient is examined shortly after the anastomosis is made. Specimens studied several weeks or months after local excision or repair of a perforation show that the apposing walls gradually fuse and straighten out. This leaves only a flat linear scar, sometimes with puckering of the surrounding mucosa.

In my experience the defect from repair in the stomach has rarely been demonstrable at roentgenologic examination. When demonstrated, the appearance of the defect is that of shallow indentation or of slightly irregular folds. If the defect is along the greater curvature of the stomach, as is usual after closure of a gastroenterostomy stoma, puckering cannot be distinguished because of the complicated pattern of the normal folds.

2. Gastroenterostomy. a. Simple gastroenterostomy. Operations performed to treat lesions in the duodenum and lower portion of the stomach often require anastomosis between the intestine and stomach. When only anastomosis is made, the term simple gastroenterostomy is applied. Two types of operation are used. In one the second portion of the duodenum is anastomosed to the anterior wall of the gastric antrum (gastroduodenostomy); in the other the jejunum is anastomosed to the lower portion of the gastric body (gastrojejunostomy). The latter type of anastomosis is accomplished in two ways. In one the loop of jejunum close to the ligament of Treitz is brought up through the colonic mesentery and anastomosed to the lower portion of the posterior wall of the stomach (posterior gastrojejunostomy). In the other a long loop of jejunum is brought up in front of the colon and anastomosed to the lowest portion of the anterior wall of the stomach (anterior gastrojejunostomy). The loop that runs from the duodenum to the anastomosis is called the afferent loop, and the one that runs from the anastomosis toward the ileocecal valve is called the efferent loop. In an anterior gastrojejunostomy an anastomosis is often made between the dependent portion of a long afferent loop and the efferent loop (enteroenterostomy).

b. Partial resection. If the lower portion of the stomach is resected, continuity of the lumen must be reestablished by an anastomosis between the stump of the stomach and the intestine. This is done (1) by anastomosing the open end of the stomach to the open end of the duodenum (Billroth I), or to the lateral wall of the jejunum (Polya); (2) by partially closing the upper portion of the open end and anastomosing the lower end to the lateral wall of the jejunum (Hofmeister); or

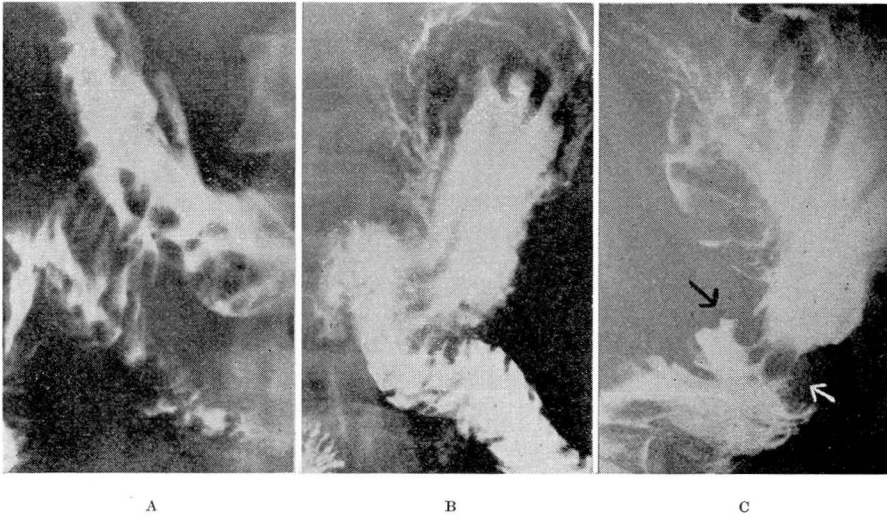


FIG. 1. Gastroenterostomies. (a) Simple gastroenterostomy. Parallel folds extending from the greater curvature of the stomach to the jejunum give the stoma a corrugated appearance. The film was made with the patient in a prone position. The right side of the patient is to the reader's left. (b) Posterior Polya anastomosis. After partial resection the lower end of the stomach was anastomosed to the side of the jejunum. (c) Hofmeister anastomosis. The lower half of the stomach was resected. The upper pole at the open end of the stomach was closed, and the lower portion anastomosed to the jejunum. The stoma is designated by arrows. Above the stoma the abrupt cessation of rugae at the site of closure of the open end of the stomach can be identified.

(3) by closing the entire open end of the stomach and anastomosing the jejunum to the lower portion of the stomach (Billroth II) (fig. 1). As in a simple gastrojejunostomy the loops of the jejunum may be brought up behind the colon to form an antecolic anastomosis. The retrocolic operation, however, is more frequently employed.

c. Roentgenologic identification of operations. The Polya, Hofmeister, and Billroth II types of anastomosis are not always distinguishable from one another at roentgenologic examination, but simple gastroenterostomy, gastroduodenostomy, and the Billroth I may be easily distinguished from other types of anastomoses. The retrocolic anastomosis is distinguished from the antecolic by the length of the afferent loop and the position of the stoma on the stomach. In the retrocolic anastomosis the afferent loop of jejunum is short and protrudes from the posterior wall. In the antecolic anastomosis the efferent loop is long and protrudes from the anterior wall of the stomach. The relationship of the intestine to the stomach is best seen when the patient stands with his left side against the screen.

d. The stoma. The examination of the anastomosis is the most important aspect of the roentgenologic examination; for it is in this

region that ulcers usually recur. The stoma may be elongated and can be seen both in profile and in frontal projection. In profile projection with the patient in the extreme left oblique or lateral position, the canal of the stoma is about one centimeter in width and is formed by the combined thicknesses of the gastric and intestinal walls. The margins near the lumen are convex and smooth. Prevot¹ describes small funnel-like outpouchings in the center of the stoma, which he interprets as recesses between the opposed gastric and intestinal walls.

In frontal projection with the patient in a right anterior, slightly oblique position, the width of the walls of the stoma varies from one to several centimeters. The stoma is seen either in axial projection (looking directly into the opening) or in cross section. In axial projection the stoma forms an irregular round opening, which may or may not contain barium. This view is not always clearly seen because the shadows of the intestine and the opposite wall of the stomach overlap. Folds radiate from the stoma, are arranged in an irregular polypoid manner about it, or are absent. When the stoma is viewed in cross section, parallel folds are sometimes seen proceeding from the stomach to the intestines. These folds are about the size of the rugae and give the stoma a corrugated appearance (fig. 1a).

In some patients the stoma is rigid and remains open, so that the barium passes rapidly from the stomach into the small intestine. In other patients the action of the stoma is rhythmic and is similar to that of the pylorus. This rhythmic action causes the barium to pass from the stomach in intermittent spurts. Schindler² believes that if the stoma possesses rhythmic activity the stomach is less apt to develop chronic inflammation than if the stoma remains open.

c. Intestinal loops adjacent to the stoma. The loops of intestine adjacent to the stoma contain the normal fine pattern of folds seen in the duodenum and jejunum in patients who have not been operated upon. Prevot¹ describes the presence of a pouch opposite the stoma, which he believes is produced by puckering of the wall. He states that the stomach is flaccid during operation, but that the walls contract and shorten the stoma as the stomach recovers tone after the operation. It is this shortening of the stoma which produces the pouch in the intestinal wall opposite the stoma.

3. Total gastrectomy (esophagojejunostomy). Total gastrectomy is usually performed for carcinoma of the upper portion of the stomach or of the entire stomach. The entire stomach is removed, the open end of the duodenum is closed, and the jejunum is anastomosed to the lower end of the esophagus.

C. PATHOLOGIC CONDITIONS

1. Peptic ulcer. After gastroenterostomies, particularly those done for peptic ulcer, the ulcer often recurs. These ulcers usually appear within the stoma or within the loops of small intestine adjacent to the stoma. Occasionally an ulcer is found in the first portion of the duodenum after simple gastroenterostomy, or along the lesser curvature of the stomach in patients having patent gastroenterostomy stomas. Recurrent ulcers are also seen along the lesser curvature of the stomach after gastric resection as well as after simple gastroenterostomy.

Ulcers occurring in the stomach or about the stoma after operation have the same general appearance as those seen in the stomach or duodenum without operation. Ulcers which lie about a gastroenterostomy stoma are often difficult to identify. Finding these ulcers is simplified by identifying the stoma and the loops of intestine adjacent to the stoma. If this is not done and if the examiner floods the field at the beginning of the examination, he finds himself pressing here and there in an attempt to locate a collection of barium, which he terms a crater because it cannot be wiped away by palpation. Berg³ believes that, since these craters have sites of predilection, craters about an enterostomy can be identified with the same accuracy as those in the duodenal bulb, if the examiner orients himself early in the examination. After gastroduodenostomy ulcers tend to recur either within the stoma or in the wall of the intestine immediately opposite the stoma. After gastrojejunostomies most craters lie in the wall of the jejunum opposite the stoma or in the efferent loop within 3 centimeters of the stoma (fig. 2).

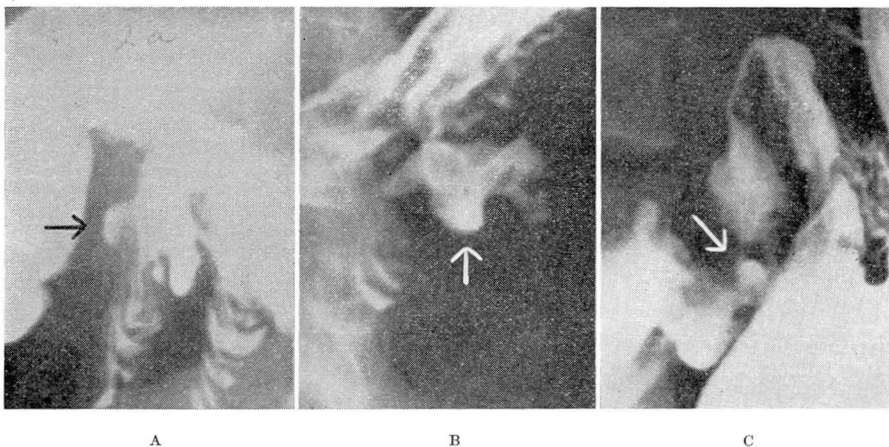


FIG. 2. Jejunal Ulcers. (a) The arrow designates an ulcer located in the efferent loop of the jejunum below the stoma of a gastroenterostomy. (b) A crater is present in the jejunal wall directly opposite the stoma of a simple gastroenterostomy. (c) The arrow indicates a crater lying adjacent to the stoma of a gastroduodenostomy in the jejunum.

When filled with barium, the craters are rounded, and neither their size nor shape is changed with palpation. They vary in diameter from a few millimeters to 2 or 3 centimeters. When viewed in profile, the base of the crater is identified by rolled margins; when seen in frontal projection, the crater is often set off from the rest of the barium by a clear halo. Radiating folds occur, and sometimes an incisura is produced by a scar in the wall opposite the crater. The stenosis caused by this scar may be great enough to produce obstruction. Sometimes the narrowing of the canal is increased by inflammatory edema.

The crater must be distinguished from loose collections of barium on the mucosa or in pockets. These spurious craters are easily distorted or obliterated by pressure; ordinarily they do not have the round indented bases suggesting a rolled-up margin. Also, they are not associated with radiating folds. Decrease in the size of recurring ulcers, as they heal during medical management, can be followed by serial roentgenologic examinations.

On rare occasions a crater may perforate the colon by burrowing through adhesions formed between the gastroenterostomy and the colon. This gives rise to a gastroenterocolic fistula. Existence of this fistula is best confirmed by administering a barium enema. When the barium from the enema reaches the distal half of the transverse colon, which is the usual site of the perforation, it enters the small intestine and stomach and then progresses through the remaining portion of the colon to the cecum. The gastroenterocolic fistula is difficult to detect if the barium is administered by mouth. Either a ball valvelike arrangement exists, which interferes with passage of contents from the stomach to the colon but allows passage of contents from the colon to the stomach, or the colon fills and is not distinguishable from the loops of small intestine.

2. Inflammations. Some inflammation accompanies most recurrent ulcers, particularly those in the jejunum. The inflammation is non-specific and according to the gastroscopist, Schindler,² is extremely common in the stomach anastomosed to the intestine. The criterion for identification of these postoperative inflammatory lesions of the stomach is the same as for inflammations in the stomach before operation.^{4, 5}

The appearance of the jejunum after operation is similar to that of other portions of the small intestine which are chronically inflamed. The folds are large and are usually arranged so that their long axis is at right angles to the long axis of the jejunum. This gives a corrugated appearance. Also, the folds are stiff and difficult to obliterate with palpation. Erosions, frequently present in the inflamed jejunum, are not seen at roentgenologic examination. The lumen of the intestine may be narrowed by edema. After gastroenterostomy changes are often

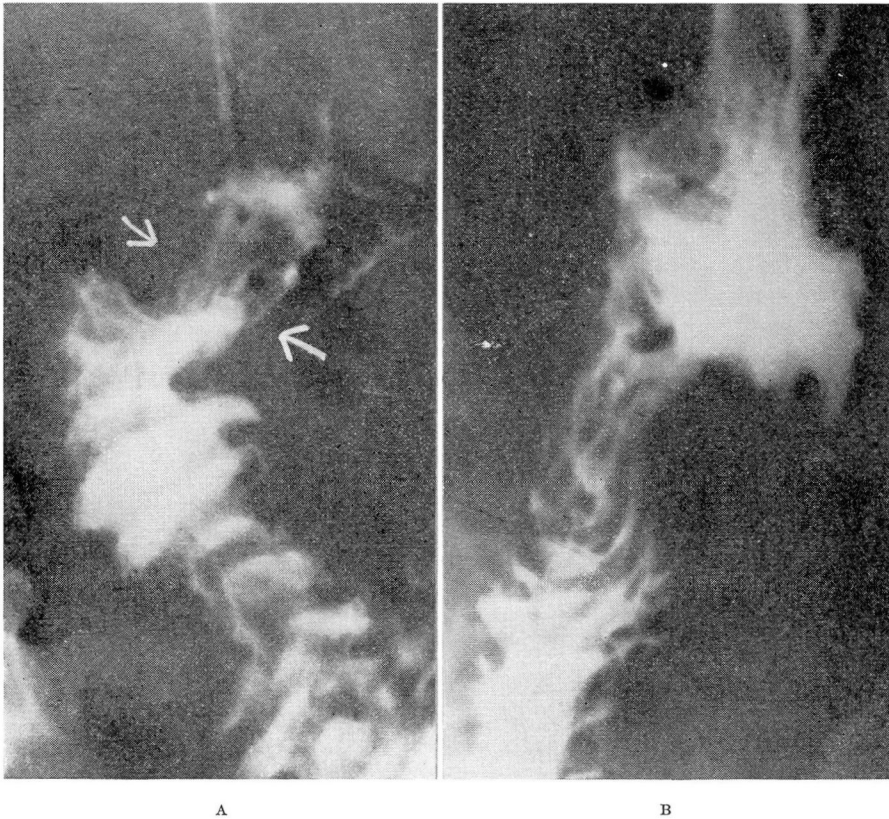


FIG. 3. Jejunitis. (a) Very little barium remains in the stomach. The gastroenterostomy is designated by arrows. The folds of the jejunum are thickened and have produced a coarse, cross-hatched appearance. Edema, reddening of the mucosa, and erosions were revealed at gastroscopic examination. (b) Five years after the patient had been on rigid medical management, the folds of the jejunum appeared normal.

most pronounced in the efferent loop close to the stoma. Under a medical regimen similar to that used in the treatment of ulcer, the appearance reverts to normal (fig. 3).

3. Carcinoma. Recurrent carcinoma is not seen so frequently as recurrent ulcer of the stomach after partial resection. It is assumed that patients operated upon for gastric carcinoma either die of metastases before a recurrence produces symptoms or are not subjected to follow-up roentgenologic examination. Many clinicians believe that if recurrence is present, nothing further can be done for the patient. There is reason to believe that carcinoma appearing in a stomach several years after operation for gastric carcinoma is not always recurrent. The

occurrence of carcinoma in stomachs operated upon for duodenal ulcer suggests that some of the so-called recurrent carcinomas are new lesions.

Carcinoma seen in the stomach after operation may spread through the walls, especially along the lesser curvature, or may remain localized at the stoma. The two types encountered are (1) the infiltrating form, in which irregular polypoid tissue with poorly defined edges replaces the normal mucosa about the stoma (fig. 4), and (2) the polypoid form, characterized by a large smooth polypoid lesion in the stomach immediately distal to the stoma. In the latter type of lesion the surface of the tumor is covered with smooth mucosa and may not be definitely recognized as malignant either by the gastroscopist or by the roentgenologist. It is possible that the polypoid arrangement of tissue may give rise to the pattern. The large size of the mass should be more suggestive of neoplasm, for surgical technic has progressed to a stage where large amounts of redundant tissue are rarely, if ever, left in situ.

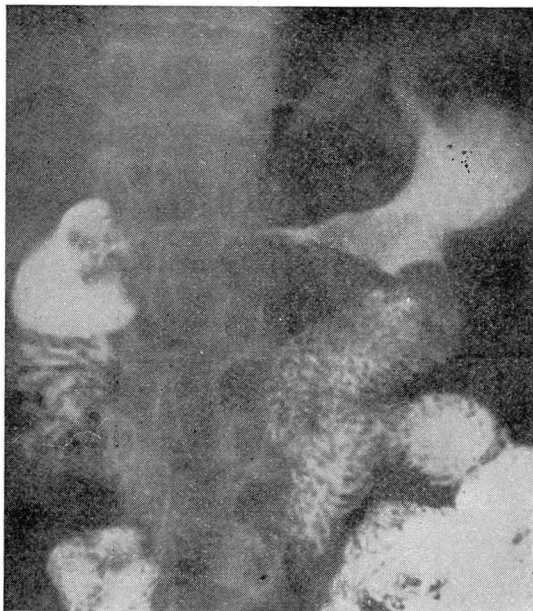

FIG. 4. Carcinoma and Gastroenterostomies. Scirrhous carcinoma involves all of the stomach and has markedly involved the antrum. The carcinoma does not extend across the stoma of a gastroenterostomy to involve the jejunum.

Prevot¹ reported the occurrence of an annular carcinoma localized at the stoma. In this instance the carcinoma surrounded the stoma and appeared to lengthen the canal. The mucosal pattern within the stoma was obliterated, and the region was rigid.

4. Disturbed physiology. No attempt has been made to describe the various manifestations of malfunction observed in the stomach and intestine after operation. There is abundant literature which describes reasons for performing either the colic anastomosis, in which the peristaltic action of the stomach and intestine proceeds in the same direction, or the isocolic anastomosis, in which the peristaltic action of the two organs proceeds in opposite directions. I have observed both types of anastomosis and have found that the barium mixture flows equally well through each type. Occasionally in a simple gastroenterostomy barium which passes through the pylorus and duodenum splits into two streams when it reaches the stoma. One stream enters the stomach, and the other passes through the efferent loop to reach the lower portion of the intestine. In a gastric resection I have seen barium fill a dilated afferent loop and remain there for a short time. In no case has barium remained in the loop for more than twelve hours. Whether the apparently abnormal directions of flow that the food may take in the stomach after operation can give symptoms has not yet been proved satisfactorily. When barium flows in these unusual directions, however, two facts are clear. The examiner must search the efferent loop carefully for evidence of a lesion. Obstructing lesions in the efferent loop may give rise to unusual pathways for the gastric contents. The duodenal bulb in a patient with a gastroenterostomy must be carefully searched when recurrent ulcer is suspected, since acid gastric juice washes the duodenal mucosa.

SUMMARY

The roentgenologic examination of the stomach after operation is admittedly difficult. A successful examination depends largely upon a good fluoroscopic technic and a familiarity with the different types of operation used in the treatment of gastric ulcer and carcinoma.

REFERENCES

1. Prevot, R.: Ergebnisse neuzeitlicher Röntgenuntersuchungen am operierten Magen. Fortschr.a.d.Geb.d.Röntgenstrahlen 56:369-386 (September) and 56:499-520 (October) 1937.
2. Schindler, R.: Gastroscopy: The Endoscopic Study of Gastric Pathology. (Chicago: University of Chicago Press, 1937).
3. Berg, H. H.: Die direkten Röntgensymptome des Ulcus duodeni und ihre klinische Bedeutung. Ergebn.d.med.Strahlenforsch. 2:249-250 1926.
4. Berg, H. H.: Röntgenuntersuchungen am Innenrelief des Verdauungskanal. (Leipzig: Thieme, 1930).
5. Templeton, F. E., and Boyer, R. C.: Diagnosis of gastric cancer; analysis of gastroscopic and roentgenologic findings. Am.J. Roentgenol. 47:262-274 (February) 1942.