

INFANTILISM, CONGENITAL WEBBED NECK AND CUBITUS VALGUS (TURNER'S SYNDROME)

R. W. SCHNEIDER, M.D. and E. PERRY McCULLAGH, M.D.

In 1938 Turner¹ described a syndrome in women characterized by shortness of stature, sexual infantilism, congenital webbing of the neck, and cubitus valgus. None of the patients had menstruated. All had attained a height ranging from 50 inches to 56 inches. Other congenital defects were commonly associated; 2 of the original 7 cases had ocular muscle palsies. All showed evidence of severe prepubertal hypovarianism, which the author implied was entirely congenital. No hormone assays were obtained in his original cases. In 1942 Varney, Kenyon and Koch² reported the association of short stature and primary ovarian insufficiency with an excess of urinary gonadotropins; webbed neck and cubitus valgus were not related findings. They suggested that this be called "ovarian dwarfism." In addition, Albright, Smith and Fraser³ demonstrated excess urinary gonadotropins in cases having the features originally described by Turner. In the light of these reports, it is now recognized that certain women of short stature with sexual infantilism differ from pituitary dwarfs in a number of ways, although in the past most of them were improperly classified as having pituitary infantilism. It is the purpose of this paper to report 6 additional cases having the anatomic features of Turner's syndrome and to distinguish between this syndrome and pituitary infantilism.

We believe that the ovarian dwarfism of Varney, Kenyon and Koch is fundamentally the same abnormality as Turner's syndrome. The cases here reported are only those showing pronounced congenital anatomic defects, similar to those reported by Turner. In one case a congenital defect is described which has not been reported previously.

Case 7 is not a case of Turner's syndrome. However, the height and congenital webbed neck presented by this patient are characteristic of Turner's syndrome. The case is therefore reported for the sake of comparison and comment.

CASE REPORTS

Case 1—A woman, aged 39, was seen on July 6, 1943, complaining of gastrointestinal distress. Her facial expression showed mental deficiency. She had never menstruated; her breasts were infantile, the nipples small and unpigmented. Axillary and pubic hair approximated $\frac{1}{4}$ of the normal amounts. An increased carrying angle of the arms, or cubitus valgus, was noted. Webbing of the neck, as judged by a short, thick neck

TURNER'S SYNDROME

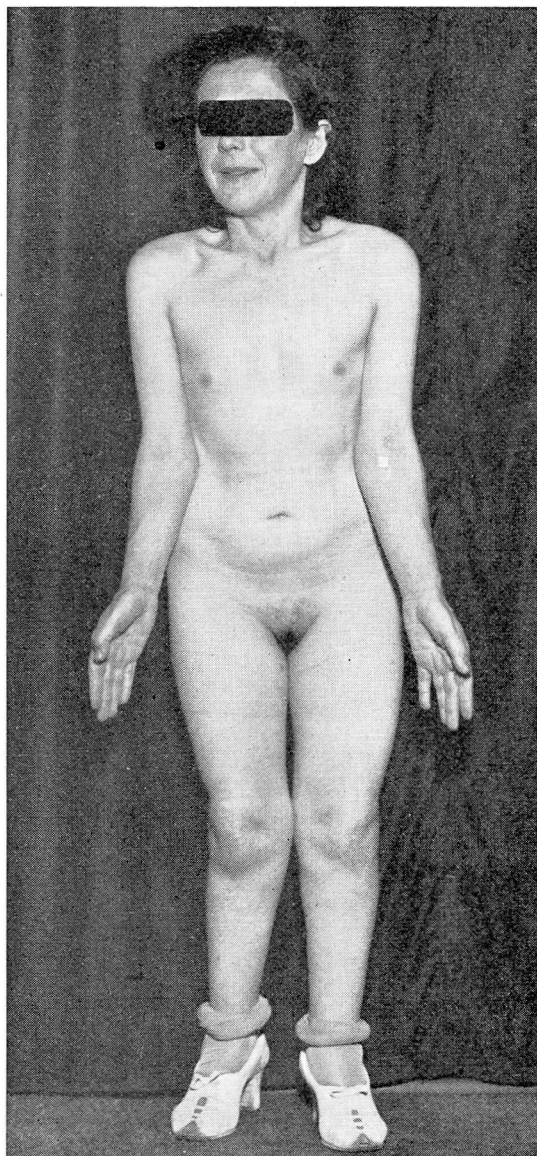


FIGURE 1—Case 1. Illustrates short neck, increased carrying angle, and infantilism.

and a low hairline, was also present. Roentgen ray examination of the cervical spine showed no developmental defect of the cervical vertebrae as seen in Klippel-Feil syndrome. Her height was 54 inches and span $55\frac{1}{2}$ inches. The uterus was infantile, and a vaginal smear showed many deep cells and leukocytes comparable to those seen after castration.

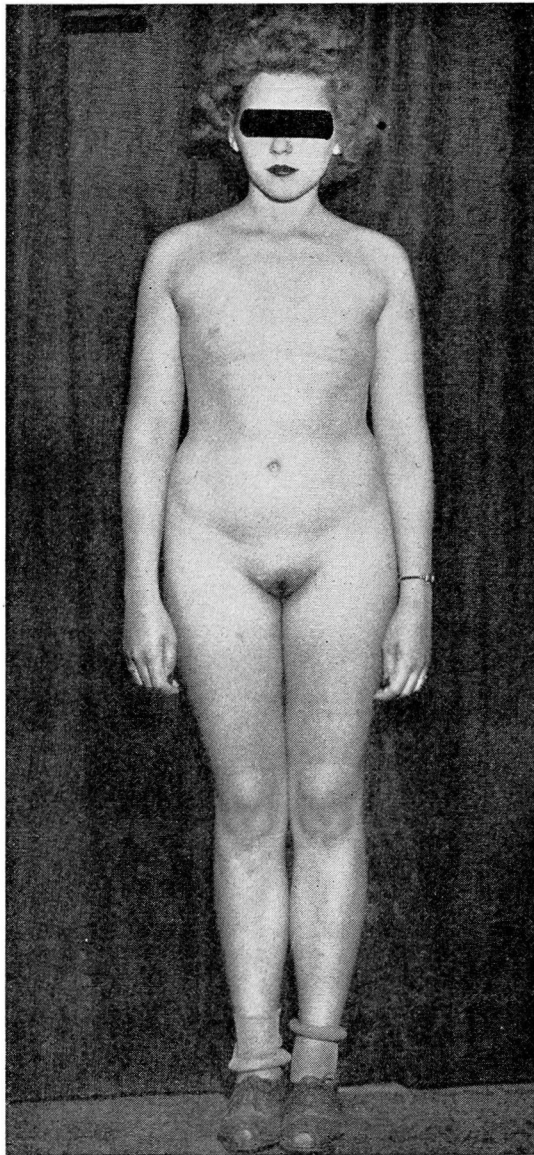


FIGURE 2—Case 2. Illustrates short neck and infantilism.

Roentgen ray examination of the skull revealed a normal sella turcica. A ketonic fraction showed an excretion of 2.1 mg. of 17-ketosteroids in a 24 hour urine specimen. Gonadotropins were definitely in excess of normal. The average ovarian weight of the test

TURNER'S SYNDROME

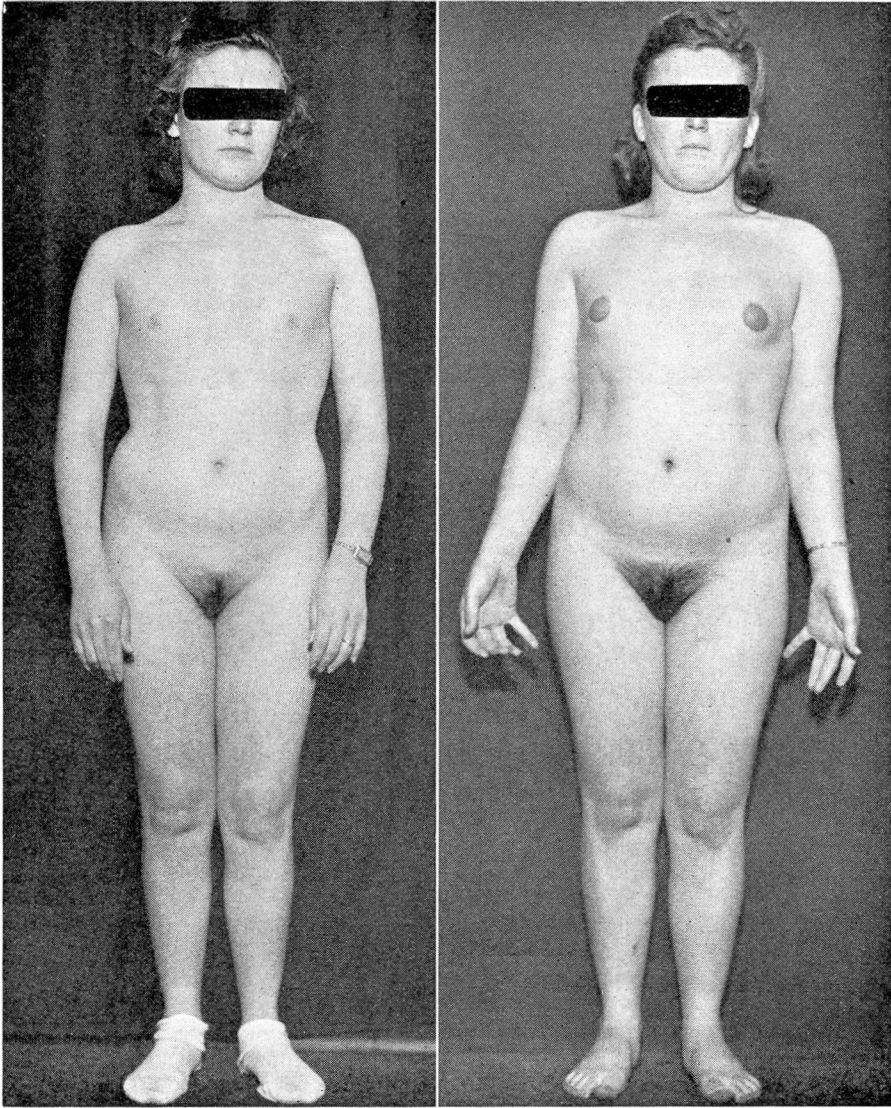


FIGURE 3—Case 3. Before and after 10 months of estrogen therapy. Shows breast development and increase in pubic hair growth.

animals was 45 mg. as compared with 19 mg. in the controls; the average uterine weight was 70 mg. as compared with 19 mg. in the controls.

Case 2—A woman, aged 22, was initially examined on July 26, 1943. She had never menstruated, and breast development had not occurred. Poor vision in both eyes had previously been attributed to lack of retinal pigment.

Her height was 62 inches and span $63\frac{3}{4}$ inches. She had a short neck but no cubitus valgus. No breast tissue was palpable. Axillary hair was about $\frac{1}{3}$ normal and pubic hair $\frac{1}{4}$ normal. The entire genital tract was infantile, and a vaginal smear was of the cast-rate type.

Other congenital defects were also observed. The fundi showed an extensive lack of retinal pigment, permitting visualization of the underlying choroidal vessels and sclera. Two rhomboidal areas of normal retinal pigment were present, but the irides were normally pigmented. There was no history of albinism in the family. The retinal defect was classified as albinismus posterior, implying that the albinism was limited to the posterior segments of the eyes.

The gum margins of the upper teeth showed considerable asymmetry between the right and left sides. The fifth finger on each hand exhibited a slight flexion contracture at the middle phalangeal joint, and a similar contracture was present on all toes of both feet.

Roentgen ray examination of the skull revealed a normal sella turcica. Bone age was estimated between 15 and 18 years. A ketonic fraction showed an excretion of 1.8 mg. of 17-ketosteroids in a 24 hour urine specimen, and gonadotropins were in excess of normal.

The patient's brother has since been seen and found to be eunuchoid as well.

Case 3—A woman, aged 21, was first observed on October 17, 1942. She had never menstruated and had not grown normally since the time of expected puberty. She had been partially deaf for years. Mental retardation was evident, and she had an obvious impediment in speech. Twelve siblings were considered normal.

Her height was 54 inches and span $55\frac{1}{2}$ inches. The facies was immature, and the upper teeth were crowded. No breast tissue was palpable. Webbing of the neck and cubitus valgus, as previously defined, were present. Axillary hair was scant, and pubic hair was approximately $\frac{1}{3}$ normal. The vagina was the length of an index finger. The walls were smooth and atrophic. The cervix was minute, and the fundus of the uterus could not be palpated. A vaginal smear consisted principally of deep cells.

Roentgen ray examination of the sella turcica was normal. Roentgen rays of the long bones indicated an epiphyseal age between 16 and 17 years.

An insulin tolerance test revealed the following findings: Fasting blood sugar was 80 mg. per cent. After an intravenous injection of $\frac{1}{10}$ unit of insulin per kilogram of ideal weight, blood sugars determined 20, 30, 45, 60, 90, and 120 minutes later were 49, 43, 62, 71, and 71 mg. per cent respectively. After the last blood specimen had been obtained, $\frac{1}{100}$ cc. of 1:1000 solution of adrenalin per kilogram of body weight was administered subcutaneously. Blood sugar determinations 45 and 60 minutes later were 141 mg. per cent.

If pituitary function is normal, blood sugar levels should return to the fasting level within 2 hours, and the response to adrenalin should be prompt and decisive. These results do not, strictly speaking, satisfy all the requirements of a normal test, but are not sufficiently abnormal to suggest pituitary insufficiency.

A ketonic fraction showed an excretion of 2.4 mg. of 17-ketosteroids in a 24 hour urine specimen. Gonadotropins measured after estrogen therapy were not in excess of normal. Ovarian weights in the test animals averaged 21 mg. as compared with 18 mg. in the controls; uterine weights averaged 25 mg. as compared with 21 mg. in the controls. The significance of the estrogen therapy in this respect is not clear, but may be important in view of observations made in case 5.

Menses have appeared regularly during continuation of estrogen and progesterone therapy, and signs of maturity are beginning to appear.

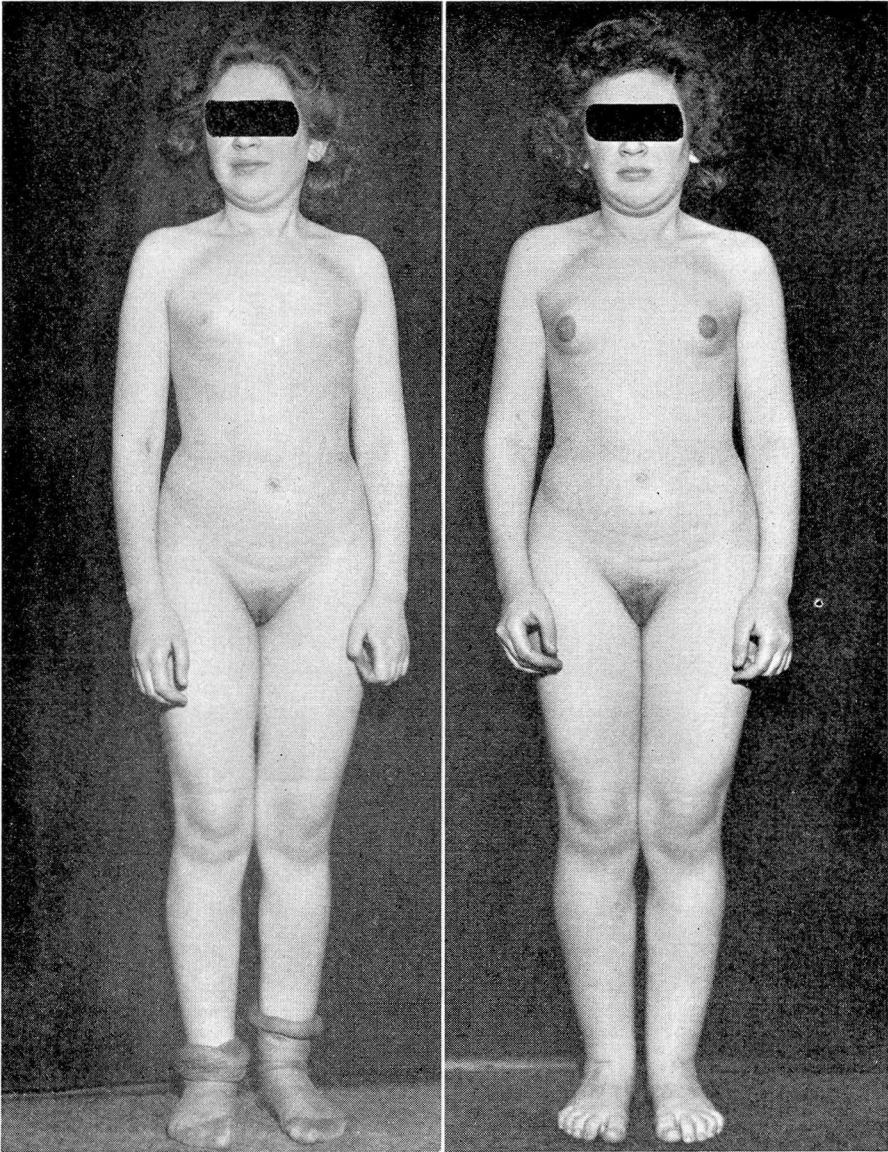


FIGURE 4—Case 4. Shows increase in maturity after 5 months of estrogen therapy.

Case 4—A woman, aged 22, was first examined on March 23, 1942. Her height was 54 inches and span 55½ inches. Menstruation had never occurred. She had had a slight amount of pubic and axillary hair since the age of 12, which at the time of examination approximated ⅓ normal in amount. The breasts and genitalia were infantile.

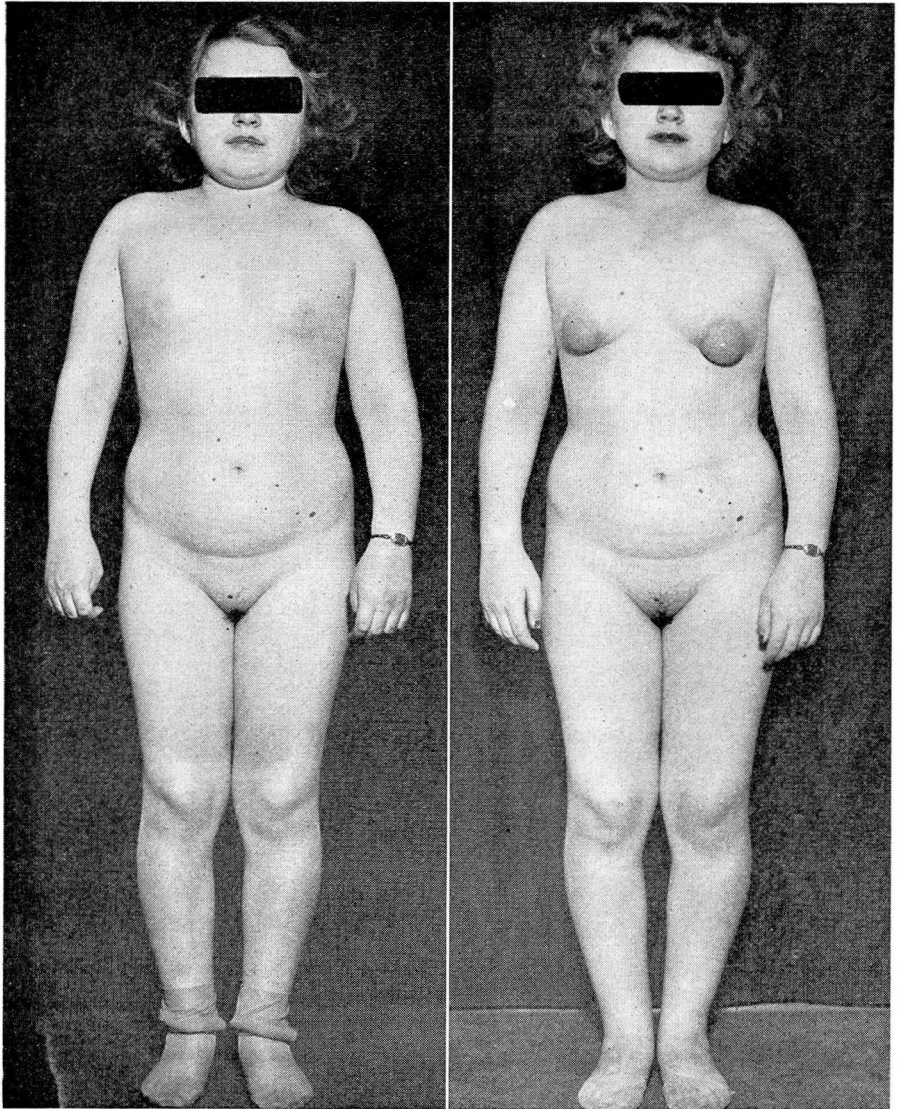


FIGURE 5—Case 5. Before and after estrogen therapy. Interval of 17 months.

The uterus could not be palpated. Webbed neck and cubitus valgus were present. A vaginal smear consisted principally of deep cells and leukocytes. Bone age was retarded about 4 years. A ketonic fraction showed an excretion of 4.2 mg. of 17-ketosteroids in a 24 hour urine specimen. Gonadotropins were definitely in excess of normal. The average ovarian weight of the test animals was 58 mg. and that of the controls .19 mg. Uterine weights of the test animals averaged 68 mg. as compared with 23 mg. in the controls.

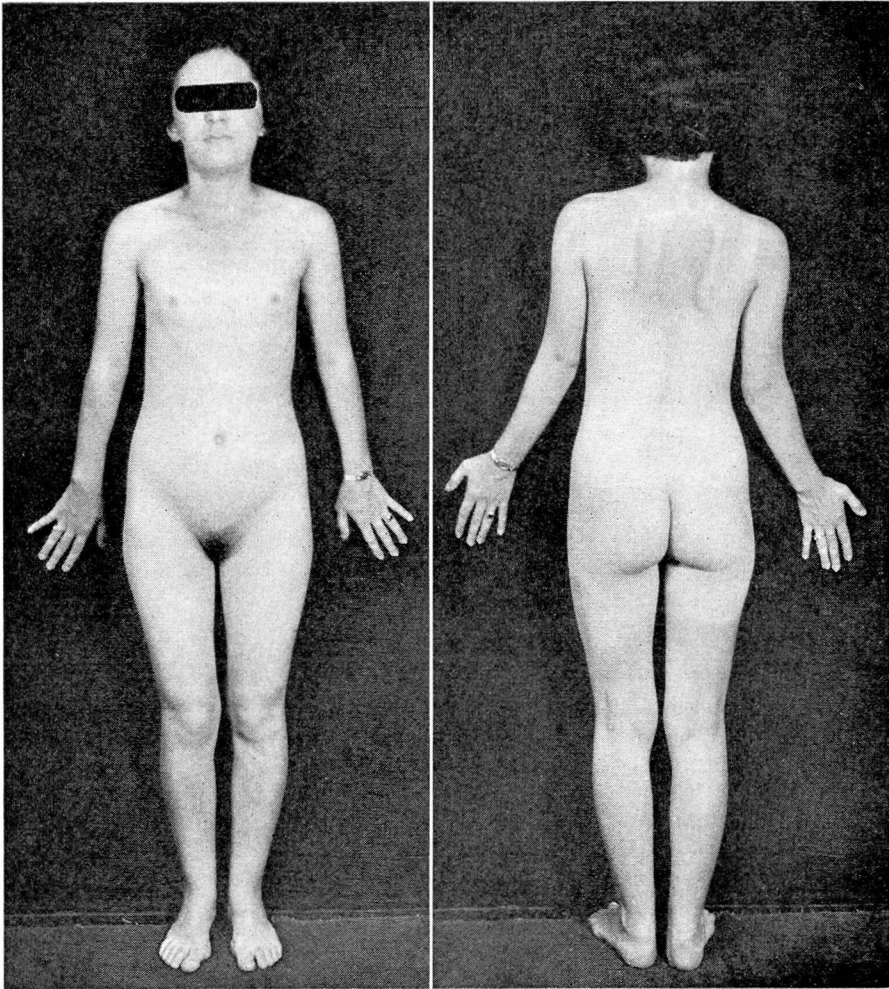


FIGURE 6—Case 6. Shows increased carrying angle, short neck, and sexual infantilism.

The patient has responded satisfactorily to estrogen therapy; bleeding has appeared regularly, and breast development has progressed steadily. Height has not increased after 15 months of continuous therapy, but axillary and pubic hair has increased to approximately $\frac{2}{3}$ of normal.

Case 5—A girl, aged 18, was first examined on December 22, 1941 because of primary amenorrhea and lack of continued growth. Her height was 55 inches and span 55½ inches. Three siblings were of normal stature. She presented immature facies, a short neck, and a wide carrying angle. No breast tissue was palpable. Axillary and pubic hair was $\frac{1}{2}$ normal in amount. The vagina, cervix, and uterus were infantile.

Roentgen rays of the sella turcica were normal. Epiphyseal age was estimated at 16

years. A ketonic fraction showed an excretion of 1.3 mg. of 17-ketosteroids in a 24 hour urine specimen; gonadotropins were in excess of normal. Ovarian weights averaged 35 mg. in the test animals and 16 mg. in the controls; uterine weights in the test animals averaged 62 mg. and 18 mg. in the controls. Gonadotropic hormone assay made after institution of estrogen therapy showed no evidence of stimulation, the uterine and ovarian weights of the test animals being the same as those of the controls. This suggests that reduction in excretion of gonadotropins here is comparable with that following estrogen therapy in the postmenopausal period.

Case 6—A girl, aged 16, was first seen on November 4, 1936, complaining of small stature and amenorrhea. There had been no growth in the previous 3 years. Her general health was good. There had been no breast development, and axillary and pubic hair was scant. There had been slight spotting for 3 or 4 days monthly from the age of 13 until the age of 15.

Her height was 57½ inches. The vagina was very small with smooth walls, the cervix was infantile, and the uterus could not be palpated. Basal metabolic rate determinations averaged plus 3 per cent. An oral glucose tolerance test after a single administration of 100 Gm. glucose gave a normal curve as follows:

Hours	Fasting	½	1	2	3	4
mg. per 100 cc. blood	90	155	127	111	80	88

No glycosuria was evident during the test period. Two Friedman tests showed measurable gonadotropic hormone with development of 3 plus mature follicles and a few small hemorrhagic follicles.

Roentgen rays of the left hand and wrist, left elbow, left foot and ankle, left knee, left hip and shoulder at the age of 22 revealed all epiphyses to be closed. Figure 6 reveals the increased carrying angle and low hairline characteristic of this syndrome.

Case 7—A woman, aged 31, complained of pain in the hip joints. Rheumatic fever had appeared at the age of 13 and again at the age of 16 and had been followed by mild aching limited to the hips and knees. Her height was 55 inches, span 58 inches, and distance from top of pubis to sole 28 inches. The weight was 100 pounds, temperature 98 F, pulse 70, blood pressure 158 systolic and 78 diastolic. Menarche had occurred at the age of 15. Menses had appeared regularly about every 28 days, with a flow of 3 or 4 days' duration. Both of two normal pregnancies had been terminated by cesarean section, one in 1936 and the other in 1939.

The patient had a typical webbed neck. The breasts were rather large and full. The pulse was regular in rate, force, and rhythm. There was no precordial shock or thrill. A coarse mitral diastolic murmur was present. Axillary and pubic hair was normal. Vagina and uterus were apparently normal. There was a waddling gait and limitation of motion in both hip joints.

Roentgen rays of the sella turcica were normal, and no abnormality was seen by roentgen ray in the cervical vertebrae. Roentgen rays of the pelvis and hips showed narrowing of both hip joint spaces. There was a slight irregularity of the head of each femur, and fibrocystic changes were present in the adjacent bone. The changes were uniform on both sides. The roentgen diagnosis of the hip-joint disease was osteochondritis.

A ketonic fraction showed 2.6 mg. of 17-ketosteroids in a 24 hour urine specimen.

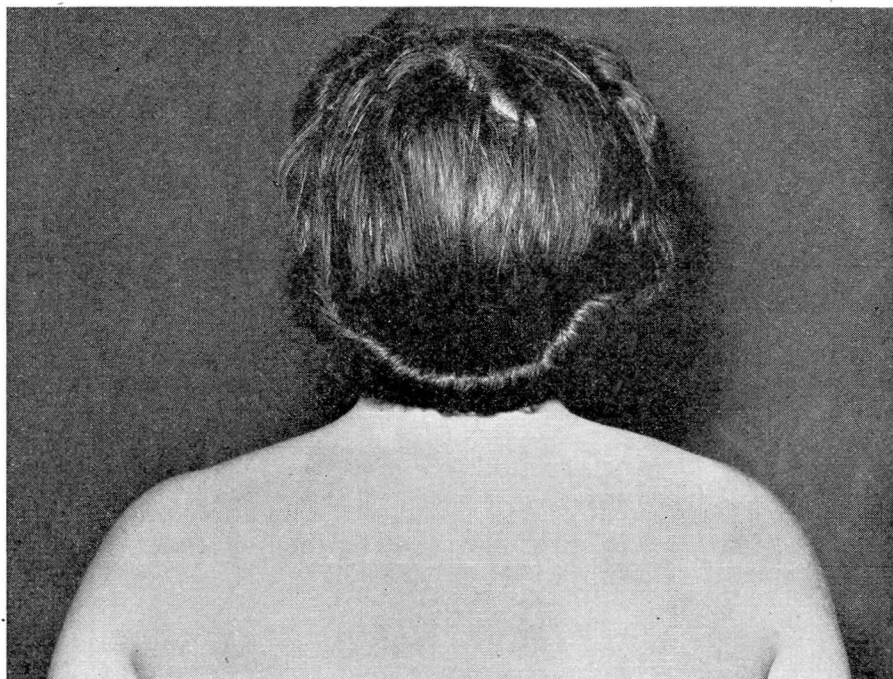


FIGURE 7

The average ovarian weight of the test animals was 16.2 mg. as compared with 14.2 mg. in the controls. The average uterine weight of the test animals was 28.3 mg. as compared with 21.9 in the controls.

The major diagnoses in this case were osteochondritis of the hip and rheumatic heart disease. The short stature associated with the webbed neck probably represented a partial Turner's syndrome.

METHODS

Special methods used in this study were assays for excretion of 17-ketosteroids and gonadotropic hormone. In determining 17-ketosteroid excretion, androgens were first extracted by butyl ether by the technic of McCullagh and McLin.⁴ Fractionation of 17-ketosteroids was done by the magnesium oxide adsorption method of Baumann and Metzger,⁵ and spectrophotometric determination by the method of Holtorff and Koch.⁶ Gonadotropic hormone assays were done by the method of McCullagh and Bowman.⁷ Normal values for 17-ketosteroid excretion in women by this method have not been definitely established, but preliminary observations suggest that the lower limit of normal will approximate 4 or 5 mg. in 24 hours.

COMMENT

The association of primary amenorrhea, genital hypoplasia, delayed development of secondary sexual characteristics, and short stature has, until recently, been assumed to be of pituitary origin and has been called pituitary infantilism. This implies that both the growth defect and the genital hypoplasia result from pituitary deficiency. Varney et al and Albright et al, however, have presented evidence that in certain instances where short stature and amenorrhea occur together, there is an abundance of urinary gonadotropins implying that the hypovarianism is not due to pituitary deficiency. The implication seems justified since pituitary dwarfs have no measurable urinary gonadotropins as judged by present methods of assay.

Differentiation of Turner's syndrome from pituitary dwarfism is of considerable clinical interest. In Turner's syndrome axillary and pubic hair begins to appear at puberty and eventually approximates $\frac{1}{3}$ to $\frac{1}{2}$ of normal in amount. Conversely, pituitary dwarfs have virtually no axillary nor pubic hair. Response to the administration of estrogens in Turner's syndrome is consistently favorable. Breast development is prompt, cyclic bleeding occurs, and axillary and pubic hair growth increases. This is clearly demonstrated in the cases presented. According to Albright, such a response is absent following estrogen therapy in pituitary dwarfism. In our cases of pituitary dwarfism lack of response to the administration of estrogens has not been conclusive, although the response does not compare with that seen in cases having the features of Turner's syndrome. The proper classification of these cases prior to the administration of estrogen therapy offers some advantage.

Although shortness of stature is common to both conditions, certain features in the growth rate are dissimilar. In hypopituitarism retardation of growth is evident at a very early age, while in Turner's syndrome growth usually progresses normally until the time of expected puberty. Since puberty does not appear, acceleration of growth rate which normally follows puberty does not occur. Consequently, dwarfism is more extreme in hypopituitarism because of earlier retardation of growth rate. In Turner's syndrome height usually reaches 50 to 58 inches, which is decidedly greater stature than is usual in pituitary dwarfism. In Turner's syndrome the women are strong and well nourished; pituitary dwarfs are frail and malnourished.

Congenital defects in addition to webbed neck and cubitus valgus commonly occur in Turner's syndrome, but not in hypopituitarism. Webbed neck occurs without roentgen ray evidence of anomalies in the cervical vertebrae and, as Turner pointed out in his original presenta-

TURNER'S SYNDROME

tion, is thus different from the webbed neck of Klippel-Feil syndrome. Turner observed ocular muscle palsies in 2 of his original cases. Albright described coarctation of the aorta and mental deficiency. In the present series 2 patients were mentally deficient, and one of these had nerve deafness. Another patient presented albinismus posterior, failure of development of retinal pigment in both eyes, without a comparable defect in the iris. Coarctation of the aorta was not observed in any of this series.

Precocious senility, amenorrhea, and mammary and genital hypoplasia occur in both syndromes. In each the bone age is delayed, but more so in hypopituitarism than in Turner's syndrome. In the former the epiphyses may never unite, while in the latter they apparently always unite.

These two conditions are further differentiated by assays of urinary 17-ketosteroids and gonadotropins. In pituitary dwarfism urinary gonadotropins are not measurable, and 17-ketosteroid excretion varies from 0 to 1.5 mg. in 24 hours (Albright). However, in Turner's syndrome there is an excess of gonadotropins in the urine; 17-ketosteroid excretion is low, but higher than in hypopituitarism (table 1).

TABLE 1

	Turner's syndrome	Pituitary dwarfism
Height	52 to 58 inches.....	Less than 48 inches
Endurance	Good	Poor
Nutrition	Good	Poor
Axillary and pubic hair	$\frac{1}{4}$ to $\frac{1}{2}$ normal	Little or none
<i>Response to estrogens</i>	Slow growth	(?)
Genital hypoplasia.....	Marked	Marked
Amenorrhea	Present	Present
<i>Response to estrogens</i>	Prompt.....	(?)
Breast development	None	None
<i>Response to estrogens</i>	Growth	(?)
Other congenital defects	Common.....	None
Precocious senility.....	May occur	Commonly occurs
Bone age.....	Usually retarded.....	Severely retarded
Urinary gonadotropins.....	Excessive.....	None by present assays
17-ketosteroids.....	Less than normal.....	Little or none

If stunting of growth observed in the syndrome described by Turner is not a pituitary phenomenon, speculation about its possible origin is interesting. Albright et al suggest an adrenal origin since 17-ketosteroid excretion is low. This is consistent with the fact that growth rate is retarded after puberty is expected, at which time 17-ketosteroid excre-

tion normally is observed to rise. Moreover, it has been established that these steroids are capable of stimulating growth. This might explain the retardation of growth rate occurring after puberty in Turner's syndrome. However, the tallest individual in the present series did not have the highest 17-ketosteroid excretion, which might be expected if this were the complete explanation for the growth defect. Albright et al further suggested that normally estrogens stimulate the production of a pituitary hormone, which in turn stimulates the adrenal cortex to liberate androgens and cause growth. If this interpretation is correct, it is easily understood why estrogens have never successfully caused growth in pituitary dwarfs, since the pituitary is incapable of accepting this stimulation. It does not explain, however, the lack of growth in Turner's syndrome following estrogen therapy, unless we assume a lack of responsiveness on the part of the adrenals. We have not observed any change in height in any cases of Turner's syndrome treated with estrogens for as long as 17 months. A rise in 17-ketosteroid excretion following estrogen therapy apparently has not been reported. The common occurrence of congenital anomalies in this syndrome suggests to us that, whatever the mechanism involved may eventually be found to be, the condition including the growth defect is fundamentally congenital.

High urinary gonadotropin excretion is found rather consistently and is comparable with the increase following castration or at the menopause. Excretion of gonadotropins apparently falls following estrogen therapy here as after treatment of the menopause, as has been demonstrated in case 5. One should not assume, however, that ovarian hypoplasia is invariable present in women with short stature and high urinary gonadotropins. Neither is it implied that high urinary gonadotropin titers in women with primary amenorrhea are limited to those with short stature.

It appears to us that case 7 might be termed "partial Turner's syndrome." The congenital webbed neck is typical of the disorder. The height of the patient was definitely within the range seen in this syndrome, even though 1 or 2 inches in height might presumably have been lost through the abnormality of the hip joints. Obviously, there was no ovarian failure of consequence since the patient was the mother of 2 children. The breasts were well developed, and the patient had lactated following parturition. If our supposition is correct, this case is closely related to Turner's syndrome. The short stature presented here may well be related to the low 17-ketosteroid production, but this in turn cannot be the result of ovarian deficiency, since this obviously does not exist.

TURNER'S SYNDROME

SUMMARY

Six cases of Turner's syndrome are presented. Their differentiation from pituitary dwarfism and their similarity to ovarian dwarfism are discussed.

Albinismus posterior, an associated congenital defect not previously described, was present in one case.

Case 6 demonstrates our previous recognition of moderate quantities of urinary gonadotropins in dwarfism associated with infantilism.

Urinary gonadotropins returned to low levels after estrogen therapy in one case.

Case 7, which we have termed "partial Turner's syndrome," is presented here because of the essentially normal function of the ovaries. This case offers presumptive evidence that the short stature in this condition is associated with inadequate 17-ketosteroid production.

Note: Since this paper has been written, we have seen an additional case having all the classical clinical features of Turner's syndrome and in addition the association of abnormal hips, which have x-ray features identical with those of Case 7.

REFERENCES

1. Turner, H. H.: A syndrome of infantilism, congenital webbed neck and cubitus valgus. *Endocrinology* 23:566, 1938.
2. Varney, R. F., Kenyon, A. T., and Koch, F. C.: An association of short stature, retarded sexual development and high urinary gonadotropin titers in women. *J. Clin. Endocrinol.* 2:137, 1942.
3. Albright, F., Smith, P. H., and Fraser, R.: A syndrome characterized by primary ovarian insufficiency and decreased stature; report of 11 cases with digression on hormonal control of axillary and pubic hair. *Am. J. Med. Sci.* 204:625, 1942.
4. McCullagh, D. R., and McLin, T. R.: The extraction of androgens from urine. *Endocrinology* 22:120, 1938.
5. Baumann, E. J., and Metzger, N.: Colorimetric estimation and fractionation of urinary androgens. *Endocrinology* 27:664, 1940.
6. Holtorff, A. F., and Koch, F. C.: The colorimetric estimation of 17-ketosteroids and their application to urine extracts. *J. Biol. Chem.* 135:377, 1940.
7. McCullagh, D. R., and Bowman, W. E.: The extraction and assay of gonadotropic hormones from human male urine. *Endocrinology* 27:525, 1940.