

# HAND-SCHÜLLER-CHRISTIAN DISEASE (Idiopathic Xanthomatosis)

## *Report of a Case*

JOHN TUCKER, M.D.

Hand-Schüller-Christian disease occurs most frequently in children under 2 years of age. The principal manifestations of the syndrome are osseous xanthoma producing defects in the membranous bones of the skull, exophthalmos, and diabetes insipidus. The etiology is unknown, although it is generally recognized that the disturbance is related to the metabolism of lipid material in the body. This substance accumulates in the reticulo-endothelial cells of the body either by infiltration or by some intracellular chemical change so that the affected cells are loaded with lipid material. When this fatty substance is dissolved out and histologic study is made, the tissue cells have a vacuolated or foamy appearance (foam cells).

The clinical picture of any particular case of xanthomatosis depends upon the regions of the body invaded by these foam cells. Rowland<sup>1</sup> contends that many other conditions such as Niemann-Pick disease, Gaucher's disease, xanthoma multiplex, and xanthomas of the skin and tendons, with or without diabetes insipidus, are all manifestations of defective metabolism of lipoids.

The tendency for these abnormal cells to accumulate in larger or smaller tissue masses produces secondary effects in various tissues of the body. In Hand-Schüller-Christian disease the localization is chiefly in the skull. When the xanthomata involve the dura mater, infiltration and lysis of the membranous bones of the skull cause circular defects of irregular contour and replacement by a fibrous, rubbery material usually containing granulation tissue, foam cells, giant cells, and scar tissue. If these abnormal reticulo-endothelial cells accumulate about the pituitary stalk, such pathologic states as diabetes insipidus, dwarfism, pituitary cachexia, or genital hypoplasia may be observed.

Trauma or tissue inflammation may determine to some extent the localization of the xanthomatous tumors, although this is not an important predisposing factor. While the parents of the affected child often attribute the disease to a previous injury to the skull, there was no such history in our case. In many reports in the literature, hyperlipemia is an associated but not an essential finding. As in other metabolic disturbances, such as gout, the blood may show no abnormal chemical changes.

In xanthomatosis the pathologic physiology in reticulo-endothelial cells is more complex than a simple storage of excess lipid from the fluid tissues of the body. Therefore, this disease is very probably not analogous to gout. Excellent monographs dealing with the problem of lipid metabolism and xanthomatosis have appeared in the literature in recent years.<sup>1, 2</sup>

In our case, 2 of the 3 criteria for a diagnosis of Hand-Schüller-Christian disease are met: defects in the membranous bones of the skull and diabetes insipidus. Clinical and pathologic study ruled out non-specific osteomyelitis, sarcoma, Tay-Sachs disease, Niemann-Pick disease, and Gaucher's disease. Likewise, the gratifying response to deep x-ray therapy and injections of pituitrin corresponds to the experience of many others who have treated this condition.

Obviously, the operation performed upon the left mastoid when the patient was 2 years of age was the result of a mistake in diagnosis. Cases of Hand-Schüller-Christian disease associated with discharging ears have been reported by Rowland, Schüller, Hand, and Gross and Stiffel. The possibility of xanthomatosis should be considered in atypical cases of apparent otitis media and mastoiditis even though it is an uncommon disease.

#### CASE REPORT

A girl, aged 2½ years and an only child, was admitted to the Clinic on January 10, 1942 with the chief complaints of marked thirst and polyuria. A foul discharge from behind the left ear and in the left parietal area caused considerable concern.

Her birth had been normal. She had been breast-fed for 2 months and then had been given evaporated milk feedings with adequate vitamins and minerals. When 3 months old she had developed discharging ears. This had continued until 2 years of age when a left mastoid operation had been performed which had failed to heal. A continuous, foul-smelling discharge had persisted in spite of local treatments. At this time a similar sinus had appeared in the left parietal area, and a softened area of bone had been noted in this region.

Marked thirst and polyuria had developed suddenly and simultaneously. The child was almost constantly at the water spigot demanding a drink, and the mother estimated that she consumed well in excess of 2 gallons of fluid a day. She was able to sleep from 8 in the evening to 6 in the morning without fluids, although she always awakened with extreme thirst. A corresponding polyuria caused her to soak the bed thoroughly each night.

The child's disposition suffered considerably with general restlessness, irritability, and an unwillingness to play with other children. Her appetite was poor, she lost weight, and her skin became dry. There was no pain and no complaint save thirst and polyuria. The patient had escaped all of the usual diseases of childhood except an occasional mild head cold.

## HAND-SCHULLER-CHRISTIAN DISEASE

### Physical Examination

The patient was of normal height for her age, but her general nutrition was poor. The skin was rather pale and quite dry. The abdomen was protuberant, but there were no signs of rickets. There were no generalized skin eruptions. The scalp showed seborrheic dermatitis, and discharging sinuses were found in the left parietal and left mastoid regions. These areas were crusted, and a foul odor was present. A soft pulsating defect could be seen in the left parietal bone. The edges were firm and sharp. Similar defects could be felt in the occipital and left mastoid areas.

The face was round and pale; the tongue and throat dry; and teeth normal. There was no sponginess nor bleeding of the gums. The eyes showed no exophthalmos; the pupils reacted to light; and the optic discs were flat. The scleras were clear. The heart, lungs, and extremities were normal. While the abdomen was protuberant, there was no clinical evidence of ascites, tumor masses, nor any enlargement of the liver or spleen.

### Laboratory Findings

Urine: specific gravity—1.000; Ph—6.5; albumin—0; sugar—0; microscopic examination—normal

Blood sugar—99 mg. per cent (fasting)

Blood chlorides—561 mg. per cent

Blood cholesterol—176 mg. per cent

Blood Wassermann—0-0-0; Kahn—negative

Blood counts: red blood cells—4,890,000 per. cu. mm.; white blood cells—6500; hemoglobin—68 per cent (Haden-Hauser)

### X-ray of Skull

A biopsy of the skull in parietal area showed complete lysis of bone. Underneath this softened area the dura was exposed, and was thick and covered with a mass of granulation tissue.

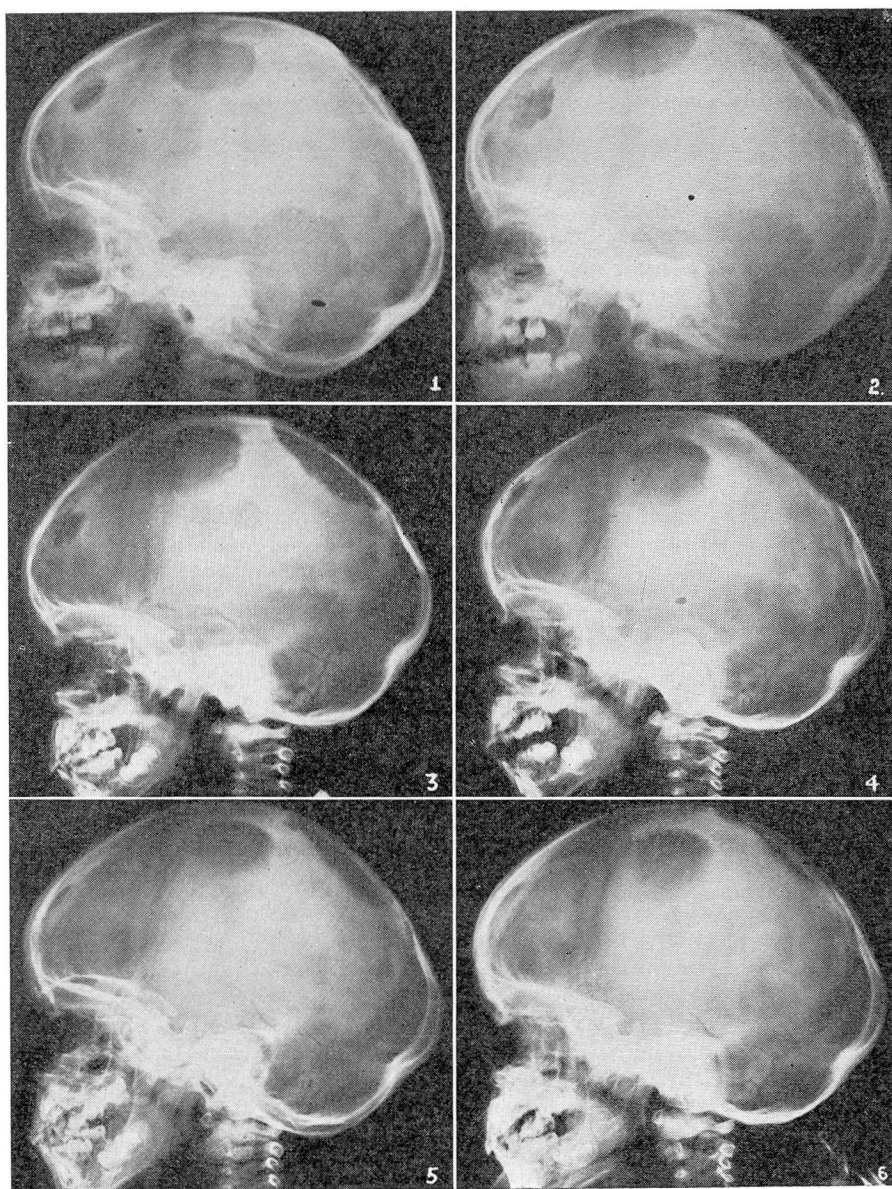
The histologic appearance showed much fibrous and granulation tissue. The marrow spaces in the bits of bone showed pink-staining, intercellular substance. Numerous giant cells were observed, but no stainable lipoid material could be seen.

### Treatment

Adequate amounts of fluid were placed at the disposal of the patient. The diet was well balanced and simple without restriction of fat.

Pituitary extract was administered hypodermically beginning with 3 min. 3 times daily and increased gradually to 1 cc. 3 times daily. This drug was well tolerated, and the fluid intake fell to 1 quart in 24 hours when the full dose of pituitrin was given. The medication was then changed to pitressin tannate beginning with  $\frac{1}{2}$  cc. daily, followed by 1 cc. every 2 days. This drug, which is absorbed slowly, prevented the excessive thirst fully as well as the previous medication.

After the diabetes insipidus was under control, x-ray therapy was given to the involved areas of the skull. The first course was administered daily except Sunday from



## HAND-SCHÜLLER-CHRISTIAN DISEASE

### X-ray Studies

The x-rays of the skull shown in Figures 1 and 2 were taken prior to the patient's admission to the Clinic.

**Figure 1.** Multiple bony defects involve the temporal, occipital, parietal, and frontal areas.

**Figure 2.** Taken 4 months later shows an increase in size of all of the lesions. The borders are moth-eaten in appearance.

**Figure 3.** Represents the first x-ray film taken at the Clinic. There is further advance in the lysis of bone with a new defect of small size appearing in the parietal region.

At this time x-ray therapy to the skull was begun.

**Figure 4.** This picture shows considerable bony repair in all of the affected areas with the possible exception of the occipital defect.

**Figure 5.** There appears to be complete healing of the areas behind the left ear as well as the smaller lesions in the left parietal bone and the frontal bone.

**Figure 6.** Further improvement in bone deposit is shown in all the remaining defects.



## JOHN TUCKER

July 25 to August 8, 1942. A second series of radiation treatments was given from April 7 to April 14, 1943.

### Results of Treatment

The most striking effects were shown not only in the satisfactory control of thirst but also in the marked physical and mental improvement. The patient has been able to eat and sleep well. She is cheerful and now plays normally with other children.

An examination on June 4, 1943 showed no physical abnormality except for a visible pulsation in the parietal area of the skull. The scalp, while hairless over the calvarium, showed no eczema, and the sinuses had healed. The skin was of normal texture and showed a normal quantity of subcutaneous fat.

At the present time she drinks about 2 pints of fluid in 24 hours and requires the injection of 1 cc. of pitressin tannate only twice a week. Evidently the diabetes insipidus has not been cured since her thirst increases somewhat as the time for her semi-weekly injection approaches. To date, fat in her diet has not been restricted, nor has she been given thyroid extract or any other type of medication.

The diagnosis of this case meets the requirements of Hand-Schüller-Christian syndrome. With the use of x-ray therapy, the correction of the bony defects has been satisfactory. The parents are delighted with the results to date, but they understand that further x-ray therapy and a longer use of pitressin tannate will be required. If the disease cannot be cured by x-ray therapy, we hope to arrest its progress until puberty, since the prospects of recovery are much better after that age has been reached.

### SUMMARY

1. A case of Hand-Schüller-Christian syndrome is presented.
2. X-ray therapy has caused extensive healing of the bony defects.
3. The use of pitressin tannate has simplified the treatment of the diabetes insipidus by requiring the use of only 1 cc. twice a week.
4. The patient appears to be normal in her growth, nutrition, and mental reaction.

### REFERENCES

1. Rowland, R. S.: Xanthomatosis and reticulo-endothelial system; correlation of unidentified group of cases described as defects in membranous bones, exophthalmos and diabetes insipidus (Christian's syndrome). *Arch. Int. Med.* 42:611-674 (Nov.) 1928.
2. Thannhauser, S. J.: Lipidoses: diseases of the cellular lipid metabolism. *Oxford Medicine* Vol. 4 Part 1 pp. 214(3)-214(365).
3. Kellogg, D.: Xanthomatosis (lipoidosis, Schüller-Christian type); report of case. *Am. J. Roentgenol.* 44:396-400 (Sept.) 1940.
4. Cohen, J. T. and Fisk, C.: Chronic idiopathic xanthomatosis of Hand-Schüller-Christian type, with special reference to oral manifestations; report of 3 cases. *Journal-Lancet* 59:192-197 (May) 1939.