

URETHRAL DISEASE IN WOMEN

WM. E. LOWER, M.D. and PHILIP R. ROEN, M.D.

Despite its apparent unimportance, the urethra in women is the site of many distressing ailments and is overlooked by many physicians and not infrequently by the specialist in urology as the possible site of pathologic change productive of urinary symptoms in women. It remained for such workers as Folsom¹ to call attention to the prevalence of urethral disease in women; as one speaker (Stark²) has stated, "I would say that the modern urologist had rediscovered the female urethra about 1930."

The diagnosis, understanding of clinical manifestations, and application of accurate therapy depend upon a knowledge of the gross and histologic anatomy and the pathologic changes involved.

The female urethra is a comparatively short tubular structure extending approximately 4 cm. from the internal urethral orifice at the bladder to the external urethral orifice in the roof of the vestibule. A cross section presents (1) a mucosal lining of squamous epithelium in its outer two-thirds and of transitional epithelium which merges with that of the trigone in its inner third; (2) this lining is thrown into longitudinal folds by a thick muscular coat which is continuous with that of the bladder. There are numerous minute urethral glands and pitlike urethral ducts which open into the lumen of the urethra. One group of these glands on each side possesses a minute common duct known as the paraurethral, or Skene's, duct, opening on either side of the external urethral orifice. The vascular layer between the muscular coat and the mucous membrane contains elastic fibers and resembles erectile tissue. Striped muscle fibers in the proximal portion of the canal form a complete ring-like sphincter, but in the middle and distal thirds, pass backwards on the outer aspect of the vagina forming a urogenital sphincter.

At the meatus and in the anterior two-thirds of the urethra, the following definite pathologic changes occur:

(1) **Congenital stenosis of the meatus.** The following case history is illustrative of this condition.

Case 1—A 2 year old child was seen at the Clinic in September, 1942 with the complaint of straining and difficulty on urination which had been noted soon after birth. Examination revealed the presence of a urethral meatal stenosis. Dilatation of the urethra up to 20 F with bougies overcame the difficulty, and the child was able to void with ease.

(2) **Urethritis.** In the acute form this is due in most instances to gonorrheal infection, though occasionally an acute inflammation may result from invasion by other cocci or the colon bacillus. Although

urethritis in men is predominantly gonorrheal, the opposite is true in women. Gonorrhea may be the cause of chronic urethral disease and stricture in women, but the relative number of cases due to this disease is very small. Chronic urethritis of nonspecific origin, on the other hand, is rather frequent. No conclusive studies of the bacteriology of female urethritis have been made; urine obtained by catheter from the bladder is often sterile; contamination from the meatus often vitiates swab or loop cultures; and, furthermore, organisms from the surface of the mucosa might not represent the true infecting agents in the deeper structures. Discharges from vaginitis, cervicitis, and puerperal infection, carelessness about vulvar hygiene and menstrual napkins, and contamination other than gonorrheal by coitus and by feces afford a varied and fertile source of urethral infection.

The symptom complex includes frequency and urgency with a stinging or burning sensation on voiding, and a constant dull pain which may be referred to the suprapubic region or the vagina. This tendency for pain resulting from chronic urethritis to be referred to other regions has often led to mistakes in diagnosis and unnecessary gynecologic operations and treatment. Terminal hematuria may also be present.

When infection occurs, particularly in the periurethral glands, drainage is retarded by swelling, and the gland structures and sub-mucosa are invaded. The terminal picture is that of a proliferative granular urethritis. The urethra, palpated through the anterior vaginal wall, shows dense thickening, and occasionally a suburethral gland abscess may be detected.

The diagnosis of urethritis, however, should be made only by ruling out pathology of the bladder and upper urinary tract by complete urologic study. The urethroscopic findings belong in the realm of the urologist. It will suffice to say that redundant granular mucosa may be observed in the anterior two-thirds of the urethra (Fig. 1).

The majority of cases have infiltration and early contracture as their basis and respond dramatically to simple dilatation with sounds. It is a common observation that the first instrumentation, usually at cystoscopy, gives signal relief. To avoid recurrence, gradual, gentle, progressive, intermittent dilatation should be carried out. Only after dilatation up to 30 or 40 F in adults is attained, is a reasonable permanency of cure assured.

If the urethritis is permitted to continue, stricture and caruncle, or both, may supervene.

(3) **Stricture.** There is a wide divergence of opinion existing with regard to the incidence of stricture of the female urethra. This condition

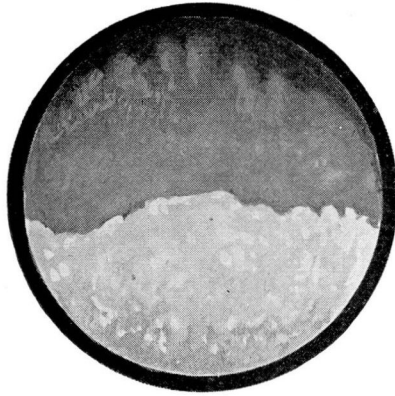


FIGURE 1

is not quite the analogue of the annular stricture in the male, the result of chronic gonorrheal cicatrization, but is a diffuse thickening and narrowing throughout the entire length of the urethra. However, even in such diffusely infiltrated urethras more frequently there is greater stenosis at the meatus than further along the urethral canal. The symptoms of stricture are urgency, difficulty in voiding, partial incontinence, and dribbling. Treatment in this condition is again that of gradual and repeated dilatation. Rarely, incision of the stricture may be necessary.

(4) **Caruncle.** These tumors occur frequently and appear as small, red, soft masses attached to the mucous membrane of the posterior aspect of the urethral meatus. Caruncle is peculiar to the lower portion of the female urethra and does not occur in the proximal third. Caruncle manifests itself in symptoms of urgency, frequency, dysuria; often there is an exquisite tenderness to touch.

The granulomatous type of caruncle will frequently extrude and be more amenable to treatment after several dilatations. If small in amount, it may be coagulated at several points. Complete destruction is not necessary. The surface will slough, and small remaining points may be coagulated at a subsequent date. Excessive scar tissue with ensuing contracture should be avoided. Large growths are better removed by sharp dissection and the bleeding points coagulated after removal. Radium should not be used as therapy for this condition; urethral stenosis may be the aftermath of such radium treatment. Since this type of caruncle is a product of chronic inflammation, one should never be content with its removal without thorough treatment of the underlying chronic urethritis.

URETHRAL DISEASE IN WOMEN

(5) **Suburethral abscess and diverticulum.** These conditions, while generally considered to occur but rarely, have been the subjects of numerous reports. Infection occurs in one of the suburethral glands, and with closure of the duct a small abscess results which may later rupture into the urethra and empty itself in this fashion; rupture through the vaginal wall, on the other hand, may produce a urethro-vaginal urinary fistula. Repeated episodes of this abscess formation and rupture into the urethral lumen may produce a large sac communicating with the urethra, thus forming a diverticulum of the urethra. Stasis of urine in such a sac may later occasion calculus formation. Recognition

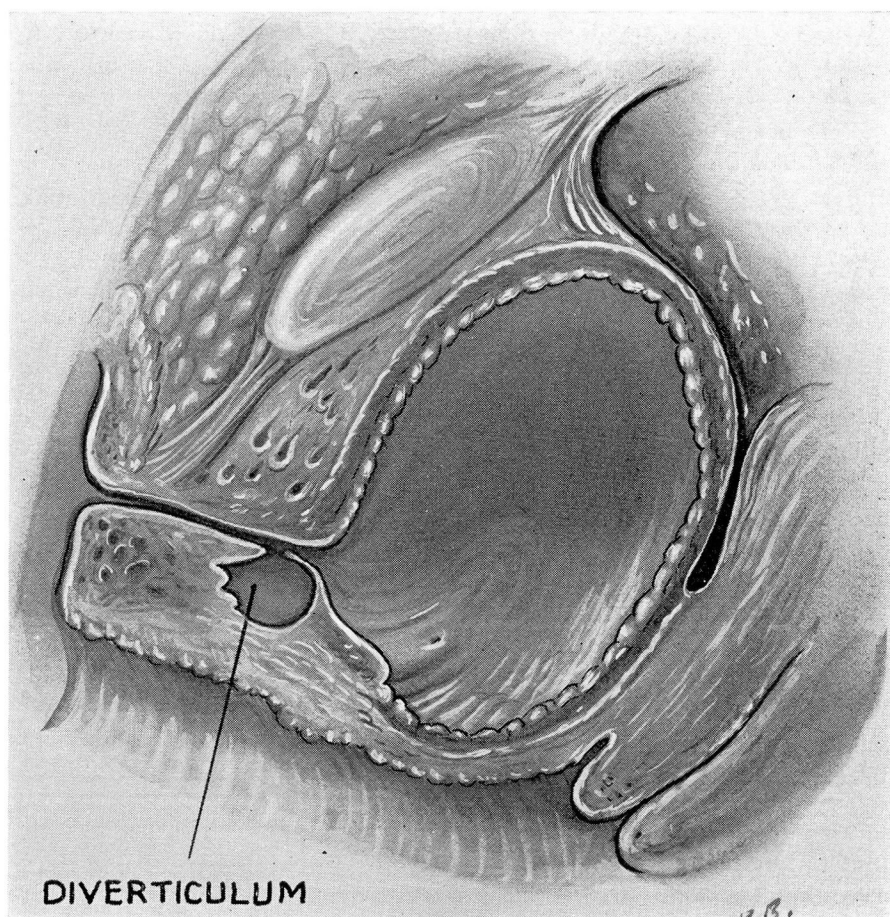


FIGURE 2

of this condition is not difficult if only it is kept in mind. A cystourethrogram with a radio-opaque solution, films being taken in the AP and oblique positions, will be diagnostic. Surgical excision of the sac is the only measure for cure. If detected in the acute abscess stage, incision will bring prompt relief (Fig. 2).

The trauma incident to childbirth with consequent weakening of the urethral wall may in certain instances also be the precursor of diverticulum of the urethra.

(6) **Neoplasm of the urethra.** Except for caruncles, true new growths of the urethra occur very rarely. Carcinoma has, however, been reported in a number of instances, and it is incumbent, therefore, upon the operator who removes proliferative lesions of the urethra to study them microscopically. Carcinoma of the urethra is an exceedingly serious problem because of the high degree of malignancy of this growth.

Polyps may on occasion be found anywhere along the urethra. Treatment is simple excision.

The posterior urethra presents a somewhat different problem. Embryologically, the posterior urethra is entodermal, whereas the anterior two-thirds are ectodermal, and the epithelium is transitional, that of the distal urethra being squamous. Recently, Beneventi³ found true prostatic tissue and glands in the posterior urethra of the female newborn. Such a finding helps to explain the obstruction of the vesical neck in adult women, the condition simulating a true prostatic urinary obstruction of the man. It is not our purpose to argue the presence or absence of a "female prostate", but the presence of numerous glands in the posterior urethra is undisputed, and it is these glands when infected that produce very distressing bladder symptoms. The frequency, pain, urgency, and dysuria may incapacitate the individual for work or social activity. Pathologic findings are dilated vessels, polypoid or cystic degeneration at the neck of the bladder, and a corrugated, irregular, dusky outline of the internal sphincter instead of the smooth, regular, glistening, pink mucosa of the normal. Not infrequently, there is actually heaping up of tissue at the sphincter floor, with a sharp decline to the trigone. Indeed, trabeculation of the bladder wall and residual urine may accompany this finding. Folsom¹ has particularly stressed the proliferative tendency of lesions of the posterior urethra; he has described, in addition to granulations, cystic formations in the mucosa together with polypi and papillomas (Fig. 3). Such excrescences at the bladder neck produce symptoms which are exactly the counterpart of prostatic obstruction in the male: there is hesitancy on voiding, a small stream, straining on urination, and occasionally dribbling and overflow incontinence.

URETHRAL DISEASE IN WOMEN

Treatment in these cases is not just the simple dilatation which is so effective where simple urethritis of the anterior urethra is present. The polypoid, cystic, or hyperplastic changes will require destruction by coagulation, either by topical application of silver nitrate through an appropriate cystoscope, or by the electrocautery. Occasionally, the punch or resectoscope will have to be employed to remove the obstructive tissue.



FIGURE 3

Case 2—A 53 year old housewife gave a history of difficulty in voiding of approximately 10 years' duration. There was associated frequency, nocturia, and dysuria, all of which had been steadily progressive. Cystoscopic examination revealed several papillomatous growths at the vesical neck which obstructed the urinary outflow. These were fulgurized, and the patient was much relieved of her difficulty in voiding, although some symptoms of dysuria and frequency persisted. At the time of discharge from the hospital, residual urine still measured 75 cc.

Differential Diagnosis. Symptoms of bladder dysfunction should be sought in the history of every woman patient, especially gynecological cases. Inspection of the fourchette should note the presence of vaginal discharge and the appearance of the external urethral meatus. The presence of a cystocele, atrophic vaginitis, or *Trichomonas vaginalis* infection should not be overlooked. A catheterized urine specimen should be obtained; the voided specimen should never be employed for examination. The bladder symptoms should not be explained away by "pressure of the uterus on the bladder." Except in the case of pregnancy or very large fibroids, such pressure is entirely physiologic and is not productive of bladder distress. Similarly, states of the urine other than infection, as polyuria from excess fluid intake or diabetes, should not be assigned etiologic significance. Too, an "acid urine" per se is never

a causative factor even though the administration of alkali may relieve frequency and dysuria to some extent. Above all, however, a thorough and complete urologic investigation should be made to discover the presence of upper urinary or midurinary tract disease before the role of causative agent is applied to the urethra. Where, however, such elimination has been done, the presence of abnormal findings in the urethra should not be minimized, and treatment should be instituted. It will often be found that the simple therapeutic measures described will frequently change a nervous uncomfortable woman with "bladder trouble" into a very grateful patient.

REFERENCES

1. Folsom, A. I.: The female urethra. *J.A.M.A.* 97:1345-1351, 1931.
2. Stark, G. W.: In discussion of a paper. *N. Y. State J. Med.* 36:1832, 1936.
3. Beneventi, F. A.: A study of posterior urethra in the newborn female. *Surg. Gynec. & Obst.* 76:64-76, 1943.
4. Everett, J. H.: Urology in the female. *Am. J. Surg.* 52:521-659, 1941.
5. Herbst, R. H., and Merricks, J. W.: Chronic primary disease of the lower female urinary tract. *M. Clin. North America.* 25:245-269, 1941.
6. Hochman, S.: A review of 500 gynecological patients with urinary symptoms. *Am. J. Surg.* 52:472-476, 1941.
7. McCrea, L. E.: Urologic conditions of the urethra. *M. Clin. North America.* 2:1801-1811, 1940.