

INTERPARIETAL HERNIAS

WILLIAM E. LOWER AND N. FRED HICKEN

Reprinted by permission from ANNALS OF SURGERY, 94:1070-1087, December, 1931.

The term "interparietal hernia" is used collectively to designate a group of rather unusual hernias which are located in the inguinal region between the various layers of the abdominal parietes. Anatomically, these hernias may be classified as follows: (1) Properitoneal hernia, that type in which the hernial sac lies between the peritoneum and the transversalis fascia; (2) interstitial hernia, in which the sac lies between the transversalis fascia and the transversalis, internal oblique, or external oblique muscles; and (3) superficial hernia, in which the sac is situated between the aponeurosis of the external oblique muscle and the integument.

Since interparietal hernia has been spoken of by all authorities as being of rare occurrence it is surprising to find that 587 cases have been reported in the literature. The inability to diagnose this condition pre-operatively and the consequent high mortality rate indicate how superficial is our knowledge of this type of hernia. Since the days of Thomas Bartholin (1661), many noted surgeons have been chagrined because they failed to recognize this type of hernia at the operating table, the mistake being revealed at necropsy.

Because of these considerations, we feel justified in presenting a clinical study of interparietal hernias based on cases observed at the Cleveland Clinic and those reported in the literature.

TWO CASES OF INTERSTITIAL HERNIA

Case I.—The patient, a truck driver, aged fifty-eight, reported at the Cleveland Clinic April 27, 1929, complaining of pain occurring low in the left side.

Four years previously, a severe pain suddenly developed in the lower left abdominal quadrant radiating downward toward the bladder and penis. The paroxysm lasted about thirty minutes and then subsided, leaving him perfectly well. There had been no nocturia, frequency, burning on urination, urgency, nor hæmaturia, and the urine had never contained any gravel.

Three months later a similar attack occurred, and since then the attacks had progressively increased in frequency and severity. Most of the paroxysms were initiated by work, exercise, lifting, or straining, and were always associated with the act of defecation. When the patient lay down, the pain immediately disappeared, often recurring, however, as soon as he stood up. He had never observed any swelling in the groin, and emphatically denied being

"ruptured." Both testicles had always been in the scrotum. The day before his admission to the clinic he had an attack of severe pain in the left groin and felt nauseated but did not vomit. The pain was intense while he was working, but subsided when he assumed a recumbent position. Some soreness was present in the region of the left groin.

The general physical examination showed a well-nourished adult male. The temperature was 97.6° , the pulse rate 64, and the blood-pressure 135/100. The pupillary reactions were normal, the teeth were in good condition, the tonsils atrophic, and the heart and lungs were normal. The abdomen was symmetrical, slightly distended, and presented the appearance of generalized rigidity. The patient complained of slight tenderness in the left groin above Poupart's ligament near the internal inguinal ring, and when pressure was applied at this point the patient felt a sense of soreness and said that he could feel "something slipping back into the abdomen." No masses or swellings could be detected. Both external rings were slightly dilated, but no hernial sac could be felt, and no impulse was transmitted during the act of coughing. Cystoscopic and pyelographic studies showed that the genito-urinary tract was normal, and all laboratory studies gave normal values. Gastro-intestinal roentgenograms failed to indicate any point of intestinal obstruction.

We felt that we were dealing with a case of partial intestinal obstruction produced by some mechanical constriction in the region of the internal inguinal ring. We were convinced, however, that the cause was not a common direct or indirect inguinal hernia. As conservative treatment did not result in improvement, operative intervention was deemed necessary.

An oblique incision was made in the lower left quadrant a half-inch above and parallel to Poupart's ligament. The aponeurosis of the external oblique muscle was exposed, but no inguinal hernia was palpable. On palpation in the region of the internal inguinal ring, a "gurgling sensation" could be felt, and it seemed as if a "loop of bowel" suddenly receded into the abdomen. The external oblique muscle was incised just mesial to the course of the inguinal canal, and a small empty hernial sac was found between the external and internal oblique muscles. By careful dissection the sac was isolated and it was found to have passed through the internal and external oblique and transversalis muscles, piercing the transversalis fascia, and opening into the peritoneal cavity about one centimeter to the left and just above the internal inguinal ring. There was no communication with the inguinal canal. The spermatic cord and

vessels could be seen entering the inguinal canal through the internal ring, and no inguinal hernia was demonstrable. The orifice of the hernial sac readily admitted the thumb, and the neck was thick and elastic but easily dilatable. The belief seemed reasonable that any increased intro-abdominal pressure would dilate the neck of the sac and permit the intestines to enter. No incarceration, however, had taken place. The neck of the sac was securely ligated, the various layers of the abdominal wall were closed, and the patient made an uneventful recovery.

Case II.—The patient, a woman, aged forty-one, the mother of three children, reported at the Cleveland Clinic on May 13, 1930, complaining of abdominal pain.

For the past six years she had suffered from flatulence, abdominal distention, and pains in the upper right quadrant. On two occasions there had been "chills and fever," associated with some tenderness over the region of the gall-bladder. Five years before this examination cholecystostomy had been performed, and a few stones and much pus had been found. Since then abdominal pain and tenderness had recurred in the old scar. During the three months previous to her entering the Clinic, pain had been present in the right inguinal region which was accentuated by working or by lifting heavy objects. At times the patient thought she could feel a slight swelling in the groin, but when questioned, she admitted that it was only her "imagination." At times the distress became so intense that she would be compelled to lie down, and immediately she would feel a peculiar "sliding sensation" in the right groin, and the pain would disappear. She denied having been ruptured.

Examination revealed a well-developed adult female. The temperature was 99.2°, the pulse rate 92, and the blood-pressure 148/94. The pupils were equal, with normal reactions. The heart and lungs were essentially normal. A scar in the upper right rectus muscle was indurated; tender and inflamed. There was some localized muscular rigidity but no feeling of fluctuation. The gall-bladder could not be palpated on account of the tenderness in this region. In the right groin, just above the external inguinal ring, was a small swelling which increased in size on straining and to which a definite impulse was imparted by coughing. The external ring was small, and no enterocele could be palpated in the canal. Both femoral rings and the left external inguinal ring were normal.

The pre-operative impression was that an abscess of the gall-bladder was pointing in the old cholecystostomy scar, and that an interstitial hernia was present in the right inguinal region. The

latter diagnosis was made because of our experience with the previous case.

A transverse incision was made over the right inguinal canal. A probe was readily introduced into the canal through the external ring, and no enterocele or obstruction was encountered. On palpation, a small tumor-like mass could be felt just near the outer side of the canal. An incision was made directly over the swelling, and as soon as the fibres of the external oblique muscle were separated, a small, partially collapsed hernial sac was seen lying between the two oblique muscles. When this sac was opened, a few tags of omentum were disclosed. The sac was carefully dissected free from the adjacent structures, to which it was fairly adherent. It lay in direct apposition to the lateral walls of the inguinal canal, pierced the internal oblique and transversalis muscles, as well as the transversalis fascia, and opened into the peritoneal cavity by its individual orifice, situated just lateral to and above the internal inguinal ring. The round ligament entered the inguinal canal through a normally located inguinal ring, and there was no communication between this canal and the interstitial hernia. The sac was ligated, the aperture through the abdominal wall was closed, and the patient made an uneventful recovery.

In both of the cases described above the condition was caused by a simple interstitial hernia, the sac in each instance being contiguous to but not communicating with the inguinal canal, each having its own separate orifice. Kronlein has discussed this type of hernia to which, because of its juxtaposition to the inguinal canal, he gave the name "para-inguinal interstitial hernia."

As there are three anatomical varieties of interparietal hernia — properitoneal, interstitial and superficial hernias, these will be discussed separately.

PROPERITONEAL HERNIA

The first authentic report on interparietal hernias was made by Bartholin in 1661, but his description was not sufficiently complete to permit classification. In 1779 Petit described a group of hernias which were situated within the interstices of the abdominal wall. In 1839 Parise saw a hernia in which the sac was situated between the peritoneum and the transversalis fascia, and in 1851 he described it under the name of "intra-iliac hernia." In 1864 Streubel collected reports of fourteen cases. The most important work however was done by Kronlein, a report of which was published in 1876. He collected and analyzed twenty-three cases which had been reported

INTERPARIETAL HERNIAS

up to that time; he carefully described the anatomical positions and clarified the etiologic factors concerned in their production, giving to this type of hernia the name "hernia inguinoproperitonealis." In 1895 Breiter, a pupil of Kronlein, collected thirty-six additional cases, and in 1900 Goebell brought the literature up to date, presenting a series of sixty-nine cases. Since that time we have been able to gather reports of fifty cases from foreign and English journals, making a grand total of 119 cases of properitoneal hernia thus far reported.

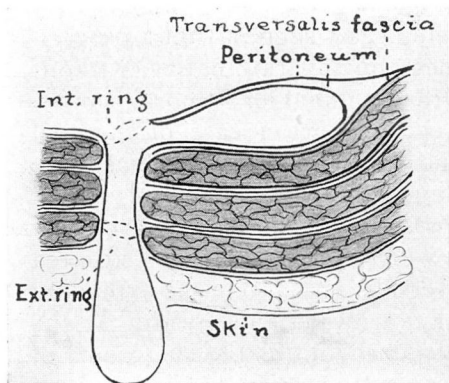


Fig. 1

Bilocular properitoneal hernia

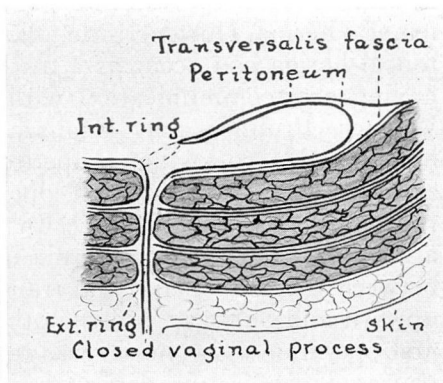


Fig. 2

Monolocular properitoneal hernia

Definition and Anatomical Considerations.— Since properitoneal hernia usually occurs in the form of a diverticulum from the walls of an inguinal or femoral hernia, cases of this type are generally designated inguinoproperitoneal or cruroproperitoneal hernias. Moynihan reserves the name "properitoneal hernia" for those which fulfill the following conditions: (1) The hernial sac must be bilocular, one loculus extending down into the inguinal or femoral canal, and the other spreading out between the peritoneum and the transversalis fascia. (2) The two loculi must communicate with each other. (3) Both loculi must open into the peritoneal cavity by means of a common orifice — either the internal inguinal or the femoral ring.

Moynihan, Halstead, and many other authorities agree that all properitoneal hernias are bilocular, as shown in fig. 1. However, we have been able to collect fourteen authentic cases in which only one sac could be demonstrated, as illustrated in fig. 2. At operation, the enterocele was found to have entered the inguinal canal through a normal internal inguinal ring, but instead of extending down the

inguinal canal, the hernial sac had spread out between the fibres of the peritoneum and transversalis fascia. The process vaginalis which continued down into the scrotum or into the labia was completely closed, and no hernia was present. These, therefore, were typical monolocular hernias. Goebell found that of sixty-nine cases of properitoneal hernia sixty were bilocular and nine were monolocular. Novaro, who in 1921 made a careful study of this type of hernia, is convinced that monolocular forms do exist.

Halstead maintains that a properitoneal hernia always occurs as a diverticulum or outpouching from a pre-existing inguinal or femoral hernia. However, the following cases suggest that a properitoneal hernia can occur as a distinct and separate entity, without having any communication with the inguinal or femoral canals. Wagner, Brunner, and Englisch each report a case of inguinal hernia and a coexisting properitoneal hernia. These hernias were separate and distinct, each opening into the abdominal cavity through an individual orifice. In 1902, Howlett reported a case of a bilocular properitoneal hernia in which both loculi were situated between the peritoneum and transversalis fascia, one sac extending upward and outward and the other downward and inward. At the first operation only one sac was recognized, but as the symptoms of nausea and vomiting persisted, a second operation was performed which revealed a loop of strangulated bowel in the second properitoneal sac. This is a good example of a properitoneal hernia occurring outside of the inguinal canal but lying adjacent to it.

It would seem, therefore, that properitoneal hernia, in both the monolocular and the bilocular forms, may be classified as follows: (1) Inguinoproperitoneal hernia, which occurs as a diverticulum from a pre-existing inguinal hernia. (2) Cruroproperitoneal hernia, which occurs as an outpouching of a femoral hernia. (3) Simple properitoneal hernia which is independent of the inguinal or femoral canals.

The anatomical positions which may be assumed by the properitoneal sac must be clearly understood if these hernias are to be treated surgically. Usually it occupies one of three positions: (1) It may pass upward and outward toward the anterosuperior iliac spine. This is the usual position. (2) It may pass directly backward, and occupy the iliac fossa. This form is often mistaken for a retroperitoneal hernia, and its relation to the inguinal canal is forgotten. (3) It may pass downward and inward to the side of or in front of the bladder. This type has been called the inguinovesical or pre-vesical hernia.

Etiology.—Precise knowledge concerning the formation of properitoneal hernia is wanting, as is attested by the number of theories which have been advanced, of which only a few of the most logical can be discussed.

After making a meticulous study of the inguinal canal, Eppinger decided that its anatomical structure was such that it predisposed to the formation of properitoneal hernia. He arbitrarily divided the canal into three portions: (1) the innermost section, which extends from the internal inguinal ring to the point where the infundibuliform fascia pierces the transversalis muscle. In this portion of the canal the transversalis fascia is firmly adherent to the transversalis muscle, but only a few fibrous tissues connect it with the peritoneum, this space being filled with loose, non-resisting fatty tissue. (2) The middle portion of the canal, which is 10 to 12 centimetres long, and is surrounded by the internal oblique and transversalis muscles. Here the muscular reinforcement precludes the formation of interparietal hernias. (3) The anterior segment of the canal, which corresponds to the space between the internal oblique muscle and the external inguinal ring. The two oblique muscles are loosely attached to each other by strands of connective tissue, and the interstices are filled with loose, yielding, adipose tissue. It is thus evident that the weakest points in the inguinal canal are at the inner and anterior segments, and it is here that interparietal hernias are encountered clinically.

It has been observed that properitoneal hernia frequently is associated with conditions which prevent the normal descent of the hernial sac. Macready, Streubel, and Kronlein noticed that an ectopic testicle situated in the inguinal canal or just outside of the external inguinal ring obstructs the descent of a congenital hernia, and if the impulses from above continue, the hernial sac is forced between the layers of the abdominal wall. It must be remembered, however, that properitoneal hernias are found in males with normal testicles, and have been reported also as occurring in women; hence some other factors must operate in their production. Von Mosetig-Moorhof insists that a narrowing of the external inguinal ring permits the bowel to descend into the dilated inguinal canal but prevents its descent through the external ring, and therefore, the hernial sac insinuates itself between the abdominal muscles. In support of this theory, Tillaux describes a case of properitoneal hernia in which the opening of the external ring was so small that it barely permitted the passage of a nerve, much less an enterocele. Butz and Bramann cite a case in which the external ring was entirely absent, yet a properitoneal hernia was found. Moynihan

believes that a defective formation of the scrotum results in an ectopic process vaginalis and testes, with resulting obstruction to the descent of a coexisting congenital hernia. Coley encountered a case in which a hydrocele in the canal of Nuck acted as a barrier to the descent of a congenital enterocele and caused a properitoneal hernia. Streubel maintains that an ill-fitting truss which permits the canal to remain open and merely presses over the external ring causes a mechanical obstruction which predisposes to the formation of interparietal hernia. According to Birkett, this theory is untenable, as malposition of a truss is very common and the occurrence of this hernia is infrequent.

It has been suggested that a narrowing of the internal inguinal ring might prevent the replacement of a large hernia into the peritoneal cavity. Gosselin and Streubel pointed out that if the internal inguinal ring was constricted and pressure was exerted from below, as in repeated and indiscriminate taxis, it might cause a bulging of the neck of the sac between the peritoneum and the transversalis fascia. By pressure over a large scrotal enterocele, Corner was able to force the intestines into a properitoneal sac, and by pressure over the properitoneal swelling, the hernial content immediately descended into the scrotum. While doing the herniorrhaphy, he was able to repeat this phenomenon, and found a narrow internal ring which diverted the scrotal contents into the properitoneal sac. Many of the so-called reductions en masse were merely instances in which the scrotal hernia was forced into a preformed properitoneal sac. The accepted explanation of reduction en masse is that an inguinal or crural sac, by repeated and forcible manipulation, is separated from its surrounding structures, and is invaginated or pushed back into the abdominal cavity without disturbing the mutual relationship between the sac and its contents. The reduced hernia always lies outside of the peritoneum.

To us it seems that the difficulty encountered in separating a hernial sac from its surrounding structures during herniorrhaphy would preclude dislocation of the hernial sac en masse by simple taxis. Streubel and Halstead believe that such cases of reduction en masse are merely the transference of the content of a scrotal or crural sac into a preformed properitoneal sac. Moynihan reviewed the specimens of reduction en masse in Guy's Hospital Museum, and concluded that most of them were from cases of properitoneal hernia. In studying the reports of cases of reduction en masse, we found that the description of the operative findings was so meager that the true anatomical position of the sacs could not be determined. We agree with Halstead and Moynihan, however, that examples of

true reduction en masse are rare, and that most of the cases which purport to be of this nature are really cases of properitoneal hernia.

In contrast with the theory of the mechanical origin of properitoneal hernia are the arguments of those who believe that all hernias are congenital. Rokitansky pointed out that in many cases small peritoneal pouches or diverticula could be seen in the immediate neighborhood of the internal inguinal ring; these, he believes, constitute the anlage of properitoneal hernia. Brunner, Englisch, and Wagner also noticed these small peritoneal pouches, and thought them responsible for interparietal hernias. In 1884, Wagner confirmed his convictions by finding a case of inguinal hernia with a coexisting properitoneal hernia which lay adjacent to the inguinal canal but did not communicate with it. Russell maintains that all hernias are congenital, and that the process vaginalis can be caught up between the layers of the abdominal muscles and form any variety of interparietal hernia. In a series of 200 post-mortem examinations, Raw and Murray found sixty-eight peritoneal diverticula, fifty-two of them being femoral, thirteen inguinal, and three umbilical. Murray believes that when these congenital diverticula or pouches exist, the occurrence of hernia depends on the size of the opening and the strength of the muscles that protect the orifice.

Coughlin's anatomical studies of adults and Moynihan's of fetuses revealed that in 22 per cent. of necropsies they could clearly demonstrate deep peritoneal pouches or fossæ near the obliterated hypogastric artery which easily could have developed into properitoneal hernias.

Kirchner reports a case of such a properitoneal hernia arising in Hesselbach's triangle as the result of a peritoneal diverticulum near the obliterated hypogastric artery. How can the occurrence of multiple hernias in the same individual be explained unless the theory of their congenital origin is accepted? Bainbridge operated on a woman in whom six separate and distinct hernias were present. Congenital malformation of a hernial sac is evident in the bifid or pantaloons hernias of Halstead, in which the inguinal sac is divided into two compartments like a pair of trousers and opens into the abdominal cavity through a normal internal inguinal ring.

Schmidt demonstrated that there might be a congenital dislocation of the internal inguinal ring upward and outward. As a result of the displacement, the spermatic cord would be too short to reach the scrotum, and an ectopic testicle would result. He convinced Oberst, Trendelenberg, Zeller, and Link that this theory was correct, but we have been able to collect only three cases which substantiate this view, those of Schmidt, Bramann, and Holder.

It must be self-evident, therefore, that the pathogenesis of properitoneal hernia cannot be ascribed to a single cause, but rather to a combination of many factors.

Incidence and Sex.—The incidence of properitoneal hernia is a subject of much controversy. Bull and Coley found but one case out of 5,000 consecutive herniotomies, while Kirchner observed two cases out of 500. We believe that the frequency of properitoneal hernia is greater than these figures indicate, and that many cases have remained undiagnosed.

Both sexes are affected, but the condition is much more common in the male than in the female because of the greater percentage of congenital anomalies which are present in the male inguinal region. Of the cases collected since 1900, thirty-three have been reported in males and nine in females, and in eight the sex was not mentioned.

All ages are involved, the youngest patient being fifteen and the the oldest seventy-five. The average age for the male is thirty-eight; the greatest number of cases occur between the ages of thirty and fifty years, which is the period of greatest muscular activity. In women the average age is fifty-five.

The right side is involved more frequently than the left, because of the greater percentage of congenital anomalies associated with the later closing of the right vaginal process. In Goebell's series of sixty cases, thirty-seven occurred on the right side and twenty-three on the left. In our collection, twelve were found on the right side and eight on the left, the side not being mentioned in thirty cases.

Symptoms.—There is no pathognomonic sign or symptom that will lead to the diagnosis of properitoneal hernia. Fully 90 per cent of the patients will present themselves with the clinical syndrome of acute intestinal obstruction. They may have had a reducible inguinal or femoral hernia of long standing. Following an apparent reduction, the patient becomes nauseated and vomits, the abdomen becomes distended, and the bowels constipated. On examination, an irreducible inguinal or femoral hernia may be found, with some tenderness over the region of the internal inguinal ring, but as a rule no swelling occurs above Poupart's ligament. Of Breiter's thirty-six cases, a swelling was felt above Poupart's ligament in twenty-two. Moynihan disbelieves Breiter's contention, and corroborates his views by an examination of all specimens of properitoneal hernia in the museum of Guy's Hospital in which he found the position of the interstitial sac to be such that it precluded recognition on abdominal examination. In rare instances the content of the inguinal hernia may be reduced into the properitoneal sac,

INTERPARIETAL HERNIAS

and then the diagnosis is obvious. In those cases in which there is no accompanying inguinal or femoral hernia, it is usually impossible to make a pre-operative diagnosis.

It is only by operation or post-mortem examination that the true nature of the hernia is revealed. Many surgeons have performed a herniotomy for strangulated inguinal hernia, removed the sac, and closed the wound, but when, to their surprise, symptoms of obstruction persisted and a subsequent operation was performed, a strangulated properitoneal hernia was found.

Of the cases reported since 1900 that we have collected, thirty-four were strangulated or incarcerated, four were reducible, and in twelve no history was given. The failure to make an early diagnosis and the resultant delayed operative intervention has resulted in a high rate of mortality. Torrey in 1888 reported thirty-five cases of strangulated properitoneal hernia, with an operative mortality of 80 per cent. In our series of fifty herniorrhaphies, there were ten deaths, and in twenty cases the results were not known, making a mortality of 20 per cent or more.

The treatment of properitoneal hernia will be considered jointly with the treatment of the other types of interparietal hernias.

INTERSTITIAL HERNIA

The two cases we have presented are typical of this group of interparietal hernia. (See cases I and II.)

From an autopsy specimen, Hesselbach, in 1814, presented an excellent illustration of this variety of hernia, with the sac lying between the internal and external oblique muscles. In 1812, Cooper observed and, in 1827, published an account of the first successful herniotomy for a strangulated interstitial hernia, the sac being situated between the two oblique muscles. In 1893, Macready was able to gather 163 cases of this form of hernia from the records of the London Truss Society, but as these cases were not verified by autopsy or operative findings, their diagnosis is uncertain. Interstitial hernia in women was first described by Berger in 1891, and Auvray in 1900 reported fourteen such cases. In 1900 Goebell collected 115 cases of interstitial hernia which had been found at operation or post-mortem examination. We have been able to gather sixty-five cases from the literature and have made two personal observations, making our series a total of sixty-seven. These, added to the figures reported by Macready and Goebell, make a grand total of 345 known cases of interstitial hernia.

Definition and Anatomical Considerations.— In interstitial hernia the sac burrows its way between the layers of the abdominal wall, and may be found in any of the following positions: (1) Between

the transversalis muscle and fascia: (2) between the transversalis and internal oblique muscles; (3) between the fibres of the internal oblique muscle; or (4) between the internal and external oblique muscles, the latter being by far the most common position. Many writers contend that the only variety seen is the form in which the sac lies between the two oblique muscles. Moynihan even goes so far as to deny the possibility of other forms because he believes the anatomic structure of the inguinal canal is such as to preclude the formation of intermuscular hernias in this section of the canal.

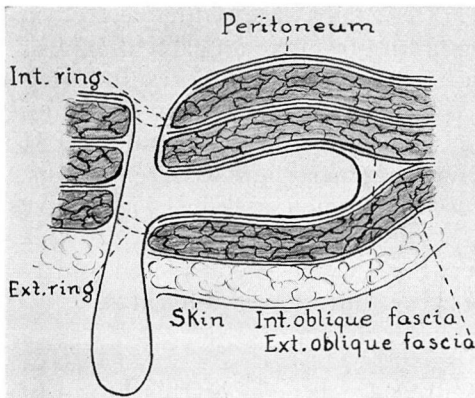


Fig. 3

Bilocular interstitial hernia

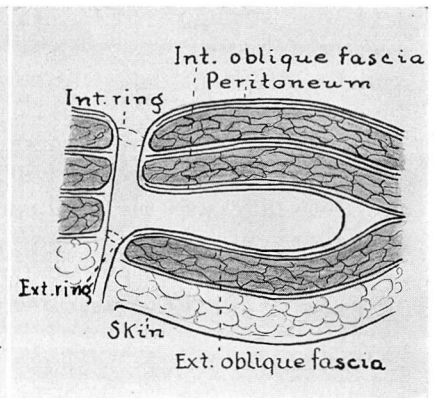


Fig. 4

Monolocular interstitial hernia

We have been able, however, to collect authentic cases of all four types of interstitial hernia mentioned above. Goebell reports eleven cases in which the hernial sac was located between the transversalis muscle and fascia, typifying group 1. He also found fifteen cases in which the hernial sac lay between the external oblique muscle and the transversalis fascia, the internal oblique and transversalis muscles being deficient in this area. As in every one of his cases the hernia was incarcerated, the exact anatomical position was determined during the operation. Coley and Sultan each describe a case in which the sac is situated between the fibres of the internal oblique and the transversalis muscles (group 2). Illustrative of group 3, Goyrand, Berger, and Venturoli have seen the hernial sac completely surrounded by the filaments of the internal oblique muscle. Goyrand, indeed, considers it characteristic, and believes that the hernial sac insinuates itself between the muscle fibres. In Berger's case, the man had a congenital monolocular hernia of the right side, and the hernial sac was surrounded by muscular fibres of the internal oblique muscle. Venturoli had to sever the

filaments of the internal oblique muscle in order to release the incarcerated hernial sac. Group 4 consists of the intermuscular hernias most commonly encountered — those situated between the two oblique muscles. Thus it seems to us that there is definite clinical evidence as to the existence of all four varieties of interstitial hernia.

Moynihan, Halstead, and Watson all assert that an interstitial hernia must be bilocular (fig. 3). One loculus must extend down the inguinal canal through the external ring and may or may not descend into the scrotum; the other loculus must pass out between the external and internal oblique muscles, and both loculi must communicate with each other and open into the peritoneal cavity through the internal inguinal ring. However, all interstitial hernias are not bilocular, for cases have been described which demonstrate that both trilocular and monolocular forms exist.

In Ehler's interstitial hernia there were three sacs, one extending between the internal and external oblique muscles, one between the skin and superficial fascia, and the third descending into the scrotum. All three loculi communicated with each other and opened into the abdominal cavity through the internal inguinal ring. In the monolocular variety (fig. 4), the interstitial sac is a direct continuation of the inguinal hernia and not a diverticulum with an inguinal hernia descending further down the canal. If the ectopic testicle is at the external ring and prevents the further descent of the hernia, the only direction in which the sac can expand is between the layers of the abdominal muscles. As there is no loculus going down into the scrotum, the hernia must of necessity be monolocular. At operation, the enterocele between the muscles is found to be a direct continuation of the sac that comes down the inguinal canal, while the process vaginalis is completely closed and in the majority of cases does not even descend into the malformed, empty scrotum. Goebell was able to collect reports of twenty-four such cases of monolocular interstitial hernias and eighty-four of the bilocular variety. In our series there were ten monolocular, thirty-six bilocular, and twenty-one that could not be diagnosed because of insufficient data.

In another variety of monolocular hernia the interstitial sac lies adjacent to but not communicating with the inguinal canal (fig. 5), and opens into the abdominal cavity through its own orifice, which lies near the internal inguinal ring. Kirchner describes such a case in which the sac does not involve the inguinal canal or the internal inguinal ring, but occurs as a separate and distinct entity. In the two cases which we have reported in this paper, the interstitial sac

was completely outside the inguinal canal, and may be classified as an extra-inguinal hernia of the interstitial variety. Perhaps some writers would consider this group as a form of ventral hernia, but its immediate proximity to the inguinal canal precludes this supposition.

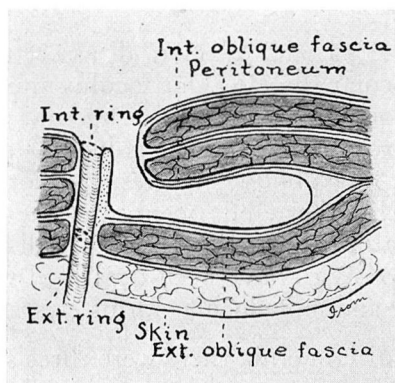


Fig. 5 — The authors' case of interstitial hernia occurring outside the inguinal canal

Etiology.—The same condition that contributes to the formation of properitoneal hernia contributes also to the production of the interstitial variety. The most satisfactory explanation of this form of rupture is based upon its connection with retained testicles. The testicle usually is situated at or just outside of the inguinal ring, and bars the further descent of the hernial sac, causing it to spread between the layers of the abdominal muscles. In Macready's 129 cases of males, abnormalities of the testicles were present in 73.4 per cent, and in 67.1 per cent there were congenital displacements of the testicles. In Goebell's 111 cases of interstitial hernia in males, abnormally placed testicles were present in fifty-seven, or 51.3 per cent. Since 1900, forty-five interstitial hernias in men have been reported, and twenty-five (55.5 per cent) of the patients had ectopic testicles. De Garmo describes two cases in which a tube and an ovary were found in the inguinal canal mechanically obstructing the descent of a congenital hernia. The cases of Macready and Goebell, combined with our series produce a total of 285 cases of interstitial hernia in males, in 186 of which the factor of retained testes was present, making a total of 65 per cent with congenital aberrant testes. Macready states that in practically all hernias of this group there is a maldevelopment of the scrotum which prevents

the normal descent of the testicle and process vaginalis. Moynihan strengthens this belief by showing that the scrotum is never fully occupied by the testicle.

That an ectopic testicle is not the only etiologic factor present, however, is evidenced by the occurrence of interstitial hernia in males with normally placed testicles, and in females. Our series includes the records of twenty-two women in whom interstitial hernias were present.

We believe that the preformed pouches of Rokitansky play a lesser part in the formation of these hernias than in the properitoneal variety; yet how can we explain the existence of the form of interstitial hernia which occurs separately from the inguinal canal unless we accept the premise that it developed in a congenitally preformed sac? The case of Kirchner, together with our two cases, illustrates this form of hernia.

Incidence.—The incidence of interstitial hernia seems to vary, as Langton observed forty-two in 50,000 herniorrhaphies, while Remedi encountered twelve in only 760 such operations. The condition occurs 3.5 times more frequently in men than in women. In Goebell's series of 115 cases, four were in women. Of Macready's 163 interstitial hernias, thirty-four were in females, while Auvray reports fourteen and Berger eight cases in women. Thus far we have been able to find 285 interstitial hernias in men and eighty-two in women. The average age incidence in males was thirty-six and in females fifty-six. The youngest patient reported was four months old and the oldest sixty-six.

Symptoms.—The outstanding clinical syndrome is that of intestinal obstruction, as evidenced by the fact that in Goebell's 115 cases, ninety-seven hernias were incarcerated. In our series thirty were incarcerated, fourteen were reducible, and in twenty-three no history was given. If a patient complains of pain in the inguinal region, is nauseated and vomits, and if examination reveals an ectopic testicle with a palpable mass above Poupart's ligament, the presence of interstitial hernia should be suspected. The intermuscular swelling, however, cannot always be palpated, the testes may be in the scrotum, and the obstructive symptoms may be missing. In such cases the diagnosis is difficult and, in fact, impossible. In our two cases no obstructive symptoms were present. Both patients complained of pain in the inguinal region which was accentuated by straining and was relieved by lying down. No inguinal mass was present. We surmised that we were dealing with some abnormal form of hernia, the exact nature of which we did not know.

SUPERFICIAL HERNIA

Boyer, in 1822, was the first to describe a hernia which proceeded from the external inguinal ring and spread out between the aponeurosis of the external oblique muscle and the integument. He termed it intra-inguinal hernia. In 1886, Le Fort revived interest in this variety of hernia, but it remained for Kuester, in 1887, clearly to describe and to define this rare condition, which he named inguinosuperficial hernia. He presented histories of fourteen cases and discussed the probable etiologic factors concerned in their production. In 1903, Moschowitz collected sixteen cases and added one of his own. In 1905, Sellenings published reports of a series of twenty-seven cases which he had collected. In a review of the literature we have been able to accumulate records of ninety-six cases, some of which date back to 1893 and are not included in any of the aforementioned series. We realize that it is a hopeless task to collect all reported cases because of the variety of titles and subjects under which they have been published. Many reports of so-called superficial inguinal hernias had to be discarded because of insufficient data which made it impossible to determine accurately their anatomical position.

The addition to our series of that of Sellenings produces a total of 123 authentic cases of superficial hernia.

Definition and Anatomical Considerations.— In inguinosuperficial hernia the sac descends into the inguinal canal, then through the external inguinal ring, and spreads out between the aponeurosis of the external oblique muscle and the skin. The sac may occupy one of three positions: (1) It may pass laterally toward the antero-superior iliac spine. This is the most common location. (2) It may extend upward and medialward toward the umbilicus, as in Broca's case. (3) It may pass downward over Poupart's ligament and come to lie directly over the femoral opening between the deep fascia of the thigh and the skin.

Cases belonging to the last group have often been described as inguinofemoral hernia. In fact, Twyman considers them a clinical entity and reports the cases of Holthouse, Key, and his own as being representative of this variety. It seems to us that these are true inguinosuperficial hernias, and should be so classified. An inguinofemoral hernia, as the name implies, is one involving both inguinal and femoral canals. For example, an inguinal hernia passes down the inguinal canal as far as the lower part of the canal; then because of an anatomical defect it passes beneath Poupart's ligament and emerges through the femoral openings. In Twyman's case the hernial

INTERPARIETAL HERNIAS

sac came through the external inguinal ring, passed downward over Poupart's ligament, and was found in the superficial tissue in Scarpa's area. The hernia was inguinal, and never came into contact with the femoral canal; hence it is merely a superficial inguinal hernia, and should be so classified.

The bilocular theory of Moynihan again is applicable to this form of hernia, one loculus passing down into the scrotum or labia and the other passing out between the aponeurosis and the integument.

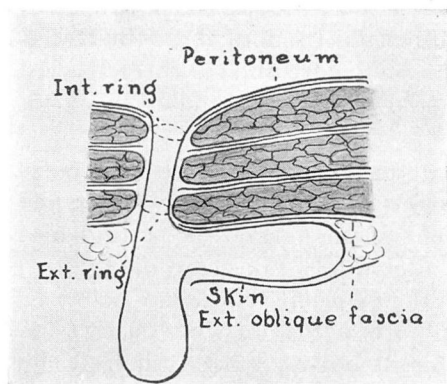


Fig. 6

Bilocular superficial hernia

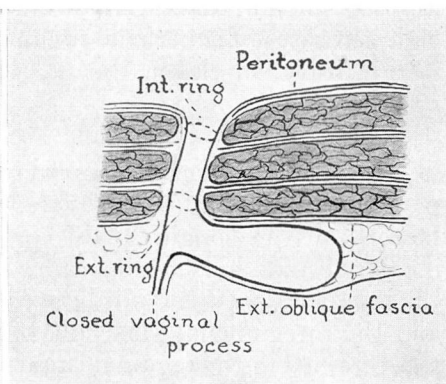


Fig. 7

Monolocular superficial hernia

(fig. 6). It is true that in some cases the superficial hernia is merely a diverticulum from the process vaginalis and that the main portion of the hernia descends into or near the scrotum. On the other hand, we have found cases in which the process vaginalis is situated between the external oblique aponeurosis and the skin, there being no hernial sac descending into the scrotum. When the process vaginalis and the testicle are both ectopic, it seems that they constitute true monolocular hernia. Goebell maintains that the monolocular variety is just as prevalent in the superficial hernias as in the other forms of interparietal hernias which have been discussed so far (fig. 7). In our series of ninety-six cases of superficial hernias thirty were bilocular, ten monolocular, and in fifty-six insufficient data made it impossible to determine the nature of the interstitial sac.

Etiology.—Practically all that has been said concerning the etiology of properitoneal and interstitial hernia could be mentioned as being causative factors in the formation of superficial hernias. The pathogenesis of this variety of hernia, however, is concerned

chiefly with congenital malformations of the process vaginalis and the testicles. As a rule, both are placed between the skin and the external oblique aponeurosis, and very seldom communicate with the scrotum. In those few cases in which the process vaginalis and the testicle enter the scrotum, the superficial hernia is merely a diverticulum from the walls of the scrotal hernia. In other cases the testicle is ectopic, but the vaginal process enters the scrotum, although it is completely obliterated below the testicle. The spermatic cord usually is short, and Schmidt considers this a factor in inhibiting the normal descent of the testicle. In 1900, Goebell collected eighteen cases of superficial inguinal hernia. In all of these the testes were ectopic, in eleven the sac was bilocular, and in three it was monolocular. In our series of cases eighty-six were in males, in sixty-seven of whom ectopic testicles were present.

However, as eight cases were found in males with normally placed testicles and seven were found in females, other etiologic factors must be sought. If the content of the hernial sac is suddenly increased and the scrotum cannot adequately take care of it, then the hernia must extend out between the external oblique aponeurosis and the integument. Moschowitz reports a case in which a testicle was retained in the inguinal canal. As the boy developed, the testicle gradually descended into the scrotum, but since the descent was accompanied by pain, he frequently forced the testicle and the accompanying congenital hernia back out of the scrotum. Following such a reduction, the testicle and hernia were forced out between the external oblique aponeurosis and the skin, as the external inguinal ring was too small to permit their return into the inguinal canal and abdomen. The hernia became strangulated, and at operation the sac was found to be as described. Repeated and indiscriminate taxis, therefore, may produce this form of hernia.

Incidence.—The incidence of this group is very low. So far, only 123 cases have been described, 101 in males and seven in females, and in fifteen the sex was not mentioned. The average age is forty-five years.

Symptoms.—The symptoms of superficial hernia usually are those of intestinal obstruction. Out of ninety-six cases, thirty were irreducible and presented symptoms of obstruction, twelve were reducible, and in fifty-four no clinical history was given. In this type, a palpable tumor generally is encountered about Poupart's ligament, and when the scrotum is examined the testicle is missing. It must be remembered, however, that in a few cases the superficial sac may pass downward into the region of the femoral ring and be mistaken for a femoral hernia.

INTERPARIETAL HERNIAS

TREATMENT OF INTERPARIETAL HERNIA

As most interparietal hernias are either incarcerated or strangulated when the patient presents himself, immediate operative intervention is indicated. Delay merely increases the risk of mortality. If a patient presents symptoms of intestinal obstruction following an inguinal or femoral herniorrhaphy, an incarcerated properitoneal hernia should be suspected, and intervention should be instituted immediately. In all herniotomies, in order to be certain that an intermuscular sac has not been missed, the entire inguinal canal should be carefully explored. When operating on an interparietal hernia, the surgeon must remember that the strangulation may be at the internal ring, the neck of the interstitial diverticulum or sac, or the external ring. The abdomen never should be closed until the site of obstruction has been found. Generally, careful exploration will reveal the enterocele in a diverticulum.

In an operation for interparietal hernia, some surgeons prefer the inguinal approach, and then, if necessary, the incision can be extended until the abdomen is opened. Moynihan thinks that a combined abdomino-inguinal route is better. It seems to us that the latter is the more practical, as it precludes injury to the bowel, since the site of obstruction is more clearly revealed by this approach.

In dealing with simple non-strangulated hernias, all that is necessary is to isolate the sac, ligate it, and close the hernial tract through the abdominal parietes.

SUMMARY

1. Interparietal hernia is a term used to designate a group of hernias which occur in the inguinal region between the various layers of the abdominal muscles, and are classified according to the anatomical location of the hernial sac.

2. Properitoneal hernia includes all those cases in which the hernial sac lies between the peritoneum and the transversalis fascia, 119 such cases being reported.

3. In interstitial hernia the sac lies between the transversalis fascia and muscle, between the transversalis and internal oblique muscles, or between the two oblique muscles, 348 such hernias having been reported.

4. In superficial hernia the sac lies between the skin and the aponeurosis of the external oblique muscle. We have found 123 cases of this type.

5. In interparietal hernia the sac may be monolocular or multilocular, the latter being the form present in the majority of cases.
6. The usual clinical picture is that of intestinal obstruction.
7. Treatment consists of early recognition and immediate relief by operation.

BIBLIOGRAPHY

- Auvray, M.: *Hernie inguino-interstitielle chez la femme (Hernie de Goyrand)*. Gaz. hebdomadaire de Médecine et de Chirurgie, vol. xlvii, pp. 542-547, 1900.
- Bainbridge, W. S.: *Multiple Herniæ*. Buffalo M. J., n. s., vol. xlv, pp. 566-568, 1904-5.
- Bartholin, T.: *Historiarum anatomicarum et medicarum rariorum centuriæ v et vi*. Accessit Joannis Rhodii mantissa anatomica. Hafniæ, typ. H. Goediani, 1661.
- Berger, P.: Sur quelques variétés de la hernie inguinale congénitale chez la femme; en particulier, des hernies compliquées d'un kyste du canal de Nuck et des hernies en bissac. Bull. et mém. Soc. de chir. de Par., n. s., vol. xvii, pp. 283-294, 1891.
- Birkett, J.: *Hernia*. In Holmes' System of Surgery, 2d ed., vol. iv, p. 706. William Wood & Co., New York, 1875.
- Boyer, A.: *Traité des maladies chirurgicales et des opérations qui leur conviennent*. Vol. viii, p. 227, Migneret, Paris, 1822.
- Bramann, F.: Der Processus vaginalis und sein Verhalten bei Störungen des Descensus testiculorum. Arch. f. klin. Chir., vol. xl, pp. 137-168, 1890.
- Breiter, W.: Ueber die Hernia inguino- und cruro-properitonealis. Beitr. z. klin. Chir., vol. xiii, pp. 659-713, 1895.
- Broca, A.: *Hernie inguino-interstitielle*. Bull. Soc. anat. de Par., vol. lxiii, pp. 111-125, 1888.
- Brunner, C.: Ueber Harnblasenbrueche. Deutsche Ztschr. f. chir., 1898, 47:121. Herniologische Beobachtungen. Beitr. z. klin. chir., vol. iv, p. 1, 1889.
- Bull, W. T., and Coley, W. B.: Observations on the Mechanical and Operative Treatment of Hernia at the Hospital for Ruptured and Crippled of New York. Annals of Surgery, vol. xvii, pp. 527-541, 1893.
- Butz, R. V.: On Properitoneal Hernia. Chir. Vestnik, vol. iv, pp. 419-422, St. Petersburg, 1888.
- Coley, W. B.: Double Inguinoperineal Herniæ, with Double Ectopic Testes. Annals of Surgery, vol. 1, p. 638, 1909. Inguinal Hernia in the Female. *Ibid.*, pp. 609-629; Superficial Inguinal Hernia Associated with Undescended Left Testis. Annals of Surgery, vol. liii, p. 301, 1911. Hernia. Syst. Surg. (Keen), vol. iv, pp. 109, 198, Philadelphia, 1908.
- Cooper, A. P.: The Anatomy and Surgical Treatment of Abdominal Hernia. In two parts. 2d ed. by C. A. Key. Longman and others, London, 1827.
- Corner, E. M.: A Case of Strangulated Hernia, First in One, and Then in the Second Sac (a Hernia en bissac) of an Inguinal Hernia. Med. Press and Circ., n. s., vol. xciv, p. 213, 1912.
- Coughlin, W. T.: Anatomical and Pathological Observation on the Formation of Hernia at Hesselbach's Triangle. St. Louis Cour. Med., vol. xxxiii, pp. 336-339, 1905.
- De Garmo, W. B.: *Abdominal Hernia; Its Diagnosis and Treatment*. J. B. Lippincott Co., Philadelphia and London, 1907.

INTERPARIETAL HERNIAS

- Ehler, F.: Ueber einige Faelle von interparietalen Leistenbruechen. Arch. f. klin. Chir., vol. xcvi, pp. 1012-1034, 1911.
- Englisch: Hernia inguinalis incarcerata; Herniotomia; Peritonitis; Existus letalis post decem horas; Platzen des Darmes bei der Reposition. Tod. Med. Chir. Centralbl., vol. xx, p. 304, 1885.
- Eppinger, H.: Beitræge zur pathologischen Anatomie der Hernien in der Leisten- gegend. Internat. Beitr. z. wissensch. Med., vol. ii, pp. 357-422, 1891.
- Goebell, R.: Ueber interparietale Leistenbrueche. Deutsche Ztschr. f. Chir., vol. lvi, pp. 1-45, 1900.
- Gosselin, L.: Leçons sur les hernies abdominales faites à la faculté de médecine de Paris. A. Delahaye, Paris, 1865.
- Goyrand, G.: De la hernie inguino-interstitielle. Mém. de l'Acad. Roy., vol. v, pp. 14-30, Paris, 1835-36. Cited by Goebell.
- Halstead, A. E.: Inguino-properitoneal Hernia, Inguino-interstitial Hernia; Report of Cases. Annals of Surgery, vol. xliii, pp. 704-716, 1906; Strangulated Inguino-peritoneal Hernia; Reduction en masse; Operation; Recovery. Med. and Surg. Rept., St. Luke's Hosp., pp. 90-100, Chicago, 1905; Left Inguino-interstitial Hernia; Hernia Inguino-subfacialis; Herniotomy; Recovery. *Ibid.*, pp. 100-106.
- Hesselbach, F. C.: Neuste anatomish-pathologische Untersuchungen ueber den Ursprung und das Fortschreiten der Leisten- und Schenkelbruecke. J. Stahel, Wuerzburg, 1814.
- Hoelder, F.: Ueber Hernia properitonealis. Beitr. z. klin. Chir., vol. vii, pp. 257-292, 1890-91.
- Holthouse, C.: Hernial and Other Tumors of the Groin and its Neighborhood. John Churchill and Sons, London, 1870.
- Howlett, E. H.: A Case of Properitoneal Hernia. Quart. M. J., vol. x, pp. 336-339, 1901-2.
- Key, C. A.: Abstract of a Clinical Lecture on Strangulated Inguinal Hernia De- livered at Guy's Hospital, July 1, 1829. Lond. Med. Gaz., vol. iv, p. 193, July 18, 1829.
- Kirchner, W. C. G.: Formation of Hernial Sac by the Obliterated Hypogastric Artery; Report of a Case. St. Louis Cour. Med., vol. xxxiii, pp. 339-341, 1905; Properitoneal Hernia. Trans. Am. Assn. Obst. and Gynec., 1912; vol. xxv, pp. 466-472, New York, 1913; Am. J. Obst., vol. lxvii, pp. 690-696, 1913.
- Kroenlein, R. U.: Hernia inguino-properitonealis incarcerata. Arch. f. klin. Chir., vol. xix, pp. 408-420, 1875-6; Weitere Mittheilungen ueber die Hernia in- guino-properitonealis. *Ibid.*, vol. xxv, p. 548, 1880; Weitere Notiz ueber die Hernia inguino-properitonealis. *Ibid.*, vol. xxvi, p. 521, 1881.
- Kuester, E.: Beitræge zur Lehre von den Hernien. Arch. f. klin. Chir., vol. xxxiv, pp. 202-221, 1887.
- Langton, J.: The Bradshaw Lecture on the Association of Inguinal Hernia with Descent of the Testis. Lancet, vol. ii, pp. 1857-1864, December 29, 1900.
- Le Clerc, R.: Hernie propéritonéale crurale. Bull. et. mém. Soc. de chir. de Paris, n. s., vol. xxxviii, pp. 437-439, 1913.
- Le Fort, L.: Sur un cas rare de hernie inguinale qu'on pourrait appeler préinguinale. Bull. gén. de thérap., vol. cx, pp. 49-55, 1886.
- Link: Zur Kasuistik der Hernia inguino-properitonealis. Centralbl. f. Chir., vol. xix, pp. 82-84, 1892.
- Macready, J. F. C. H.: A Treatise on Ruptures. C. Griffin & Co., London, 1893.

- Moschcowitz, A. V.: Inguino-superficial hernia (Kuester). *Med. Rec.* vol. lxiii, pp. 52-55, 1903.
- Moynihan, B. G. A.: Arris and Gale Lectures on the Anatomy and Pathology of the Rarer Forms of Hernia. *Lancet*, pp. 513-520, February 24, 1900.
- Murray, R. W.: *Hernia; Its Cause and Treatment*. 2d ed. P. Blakiston's Son & Co., Philadelphia, 1910.
- Novaro, N.: Delle ernie inguino-interparietali (inguino-superficiali, inguino-interstiziali, inguino-properitoneali). *Gass. internaz. di med.*, vol. xxiv, pp. 3-6 1921.
- Oberst, M.: Ein Fall von incarcerirter Hernia inguina-properitonealis; Herniotomie; Heilung. *Centralbl. f. Chir.*, vol. x, pp. 65-68, 1883.
- Parise, J.: Mémoire sur deux variétés nouvelles de hernies, la hernie inguinale intra-iliaque et la hernie inguinale antévésicale. *Mém. Soc. de Chir. de Paris*, vol. ii, pp. 399-430, 1847-51.
- Petit, J. L.: *Traité des maladies chirurgicales, et des opérations qui leur conviennent*. Méquignon l'aîné, vol. ii, p. 217, Paris, 1790.
- Remedi, V.: Quoted by Novaro.
- Rokitansky, C.: *A Manual of Pathological Anatomy*, vol. ii, p. 12. The Sydenham Society, London, 1849.
- Russell, R. H.: Inguinal Herniæ. *Brit. J. Surg.*, vol. ix, pp. 502-508, April, 1922.
- Schmidt, M.: Zur Aufrechterhaltung meiner Erklarung fuer die Genese der Hernia inguino-interstitialis und Hernia inguino-properitonealis. *Arch. f. klin. Chir.*, vol. xli, pp. 292-304, 1891.
- Sellenings, A. E.: Superficial Inguinal Hernia, with Report of a Case. *Med. News*, vol. lxxvi, pp. 489-491, 1905.
- Streubel, C. G.: Ueber die scheinveduction bei Hernien, und insbesondere bei eingeklemmten Hernien. *Leipsig*, 1864.
- Sultan G.: *Atlas and Epitome of Abdominal Hernias*. Translation from the German edited by William B. Coley. Philadelphia, 1902.
- Tillaux, P.: De la hernie inguino-interstitielle; rôle du taxis dans cette hernie. *Bull. gén. de therap.*, vol. lxxxi, pp. 209-217, 1871.
- Torrey, W. S.: Inguino-properitoneal Hernia. *Annals of Surgery*, vol. vii, pp. 161-170, 1888.
- Trendelenburg, F.: *Centralbl. f. Chir. Original Referat.*, 1881. Cited by Goebell.
- Twyman, E. D.: Combined Inguinofemoral Hernia. *Surg. Gynec. and Obst.*, vol. xxvii, p. 182, August, 1918.
- Venturoli: *Novi Comment. acad. scient. institut. Bononiens*, T. iv., 1840. Schmidt's *Jahrbuecher*, vol. xxxiii, p. 233. Cited by Goebell.
- Von Mosetig-Moorhof: Fall von Hernia inguino-properitonealis. *Wien. med. Wchnschr.*, vol. xxxv, pp. 257-260, 1885.
- Wagner, A.: *Ueber die Hernia properitonealis*. Dorpat, Schnakenburg, 1884.
- Watson, L. F.: *Hernia*, p. 163. C. V. Mosby Co., St. Louis, 1924.
- Zeller: Ein Fall von Hernia inguino-properitonealis incarcerata. *Medicin. Correspondenzblatt des Wuerttemberg. aertzl. Landesvereins*, No. 32, 1887. Cited by Goebell.