

TABLE OF CONTENTS

FROM THE EDITOR

Foxglove, not quite gone or forgotten

458

Digoxin use has waned dramatically over the past decades, with good reason, but for select patients, it may be a very reasonable option.

Brian F. Mandell, MD, PhD

THE CLINICAL PICTURE

Persistent erosions of the glans penis and foreskin

463

A 66-year-old man presented with an 8-month history of persistent erosions of the glans penis and foreskin with slight itching and pain.

Zheng Gu, MD; Dong-Lai Ma, MD, PhD

1-MINUTE CONSULT

What fluids should I order for my patient with acute pancreatitis?

466

Recent data show that moderate fluid resuscitation is associated with fewer adverse events and that lactated Ringer's may be superior to normal saline.

Anusha Agarwal, MD; Arjun Chatterjee, MD; Prabhleen Chahal, MD

SYMPTOMS TO DIAGNOSIS

Recurrent syncope in a 62-year-old man

473

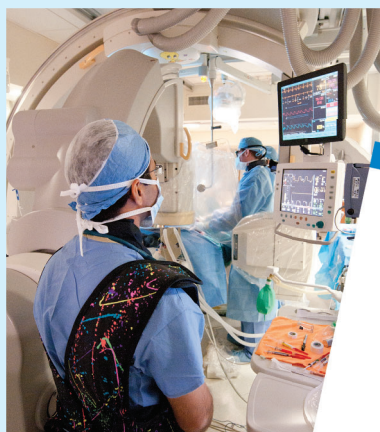The patient experienced 2 episodes of syncope over 4 weeks, had a history of recurrent carpal tunnel syndrome, and had ankle edema for the previous 18 months.

Cindy Hsin-Ti Lin, MD; Michael Sheu, MD; Faiz Anwer, MD

CONTINUED ON PAGE 457

Upcoming Features

- Primary adrenal insufficiency in adults: When to suspect, how to diagnose and manage
- Should I refer my patients for renal denervation?



CLEVELAND
CLINIC
JOURNAL OF
MEDICINE

CONTINUED FROM PAGE 454

REVIEW

***Helicobacter pylori*: A concise review of the latest treatments against an old foe** 481

H pylori eradication regimens are tailored based on the presence of effective empiric therapy (local cure rates $\geq 90\%$ for a given regimen) or antimicrobial susceptibility testing.

Wafa A. Aldhaleei, MBBCh, MSc, MPH; Michael B. Wallace, MD, MPH; Dana M. Harris, MD; Yan Bi, MD, PhD

REVIEW

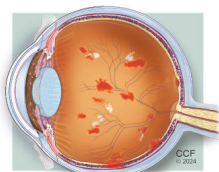
CME MOC

Digoxin is still useful, but is still causing toxicity 489

The authors review the presentation of digoxin toxicity, its mechanisms and predisposing factors, and its medical management.

Alejandro Durán Crane, MD; Michael Militello, PharmD, BCPS; Michael D. Faulx, MD

REVIEW

**Diabetic retinopathy: Screening, prevention, and treatment** 503

Effective screening processes, timely referrals, and strategic diabetes management are essential to prevent and mitigate the consequences of diabetic retinopathy.

David D. Chong, BA; Nikhil Das, MD; Rishi P. Singh, MD

DEPARTMENTS

CME Calendar 460**CME/MOC Instructions** 512**CME CREDIT TEST**

Visit **WWW.CCJM.ORG**
Test your knowledge
of clinical topics and earn
AMA PRA Category 1 Credit™
and **ABIM MOC points**

CLEVELAND
CLINIC
JOURNAL OF
MEDICINE