

TABLE OF CONTENTS

FROM THE EDITOR

Dealing with the “T” (testosterone) 78

If a patient feels better when taking testosterone supplementation, is it the “T” or is it a placebo effect?

Brian F. Mandell, MD, PhD

1-MINUTE CONSULT

What are the management considerations for venous thromboembolic events in patients with cirrhosis? 86

The authors review the current evidence on venous thromboembolic event (VTE) risk prediction in patients with cirrhosis, as well as VTE prophylaxis and anticoagulant therapy.

Marie M. Plante, MD, BSN, RN; Emily B. Wolf, MD; Razvan M. Chirila, MD

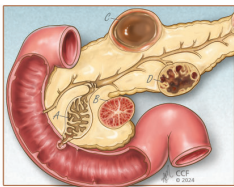
1-MINUTE CONSULT

Does my patient have testosterone deficiency? 93

Diagnosis of testosterone deficiency requires the presence of relevant signs or symptoms along with biochemical evidence.

Andrew D. Shumaker, MD; Navid Leelani, DO; Bradley Roth; Prajit Khooblal, MD; Raevti Bole, MD; Scott D. Lundy, MD, PhD; Petar Bajic, MD

REVIEW



Diagnosis and management of pancreatic cystic lesions for the non-gastroenterologist 96

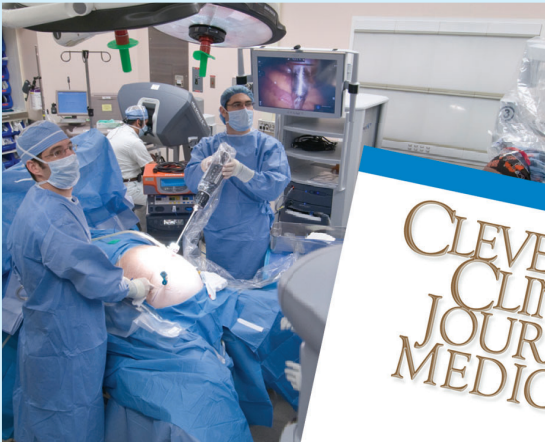A summary of current guidelines from several organizations on the diagnosis and surveillance of pancreatic cystic lesions.

Arjun Chatterjee, MD; Tyler Stevens, MD, FACP, FASGE; Prabhleen Chahal, MD, FACP, FASGE

CONTINUED ON PAGE 77

Upcoming Features

- Artificial intelligence in clinical practice: A look at ChatGPT
- Multiple metabolic renal manifestations of a systemic disease



CONTINUED FROM PAGE 71

SYMPTOMS TO DIAGNOSIS

Hypertension and severe hyperreninemia in a young man 103

A 29-year-old man with blood pressure measurements of 152/118 mm Hg and 156/116 mm Hg at 2 separate clinic visits is started on combination antihypertensive therapy and undergoes evaluation for secondary causes of hypertension.

Joshua M. Leisring, MD; Jason Lyou, MD; Eshetu Obote, MD; Amy A. Yau, MD

REVIEW

CME MOC

Management of venous thromboembolism in patients with active cancer 109

The authors review the presentation and diagnosis of venous thromboembolism in patients with cancer and present an approach to treatment that aims to balance the bleeding risk from anticoagulation with the risk of recurrent thrombosis.

Heloni M. Dave, MBBS; Alok A. Khorana, MD, FACP, FASCO

REVIEW

von Willebrand disease: A guide for the internist 119

The pathophysiology of von Willebrand disease, its subtypes, common presentations of each subtype, diagnostic testing, and management of clinical manifestations of the disease are reviewed.

Varinder Kaur, MD; Omar Elghawy, MD; Saarang Deshpande, MD; David Riley, MD

LETTERS TO THE EDITOR

Should I start an SGLT-2 inhibitor in my patient with heart failure and chronic kidney disease? 82

Taher Modarressi, MD

In Reply: Should I start an SGLT-2 inhibitor in my patient with heart failure and chronic kidney disease? 82

Pooja Prasad, MD; Megha Prasad, MD

Surgical and procedural management of benign prostatic hyperplasia 83

Sameer Gadani, MD; Ihab Haddadin, MD; Justin Guan, MD; Michael Bergen, MD; Abraham Levitin, MD

In Reply: Surgical and procedural management of benign prostatic hyperplasia 83

Ayodeji E. Sotimehin, MD; Bradley C. Gill, MD, MS

DEPARTMENTS

CME Calendar 69**Our Peer-Reviewers for 2023 85****Correction 118**

In the January 2024 issue, the article “When should we consider SGLT-2 inhibitors in patients with acute decompensated heart failure?” by Badwan OZ et al [Cleve Clin J Med 2024; 91(1): 47–51. doi:10.3949/ccjm.91a.23034] contained an error in Figure 1.

CME/MOC Instructions 128