

TABLE OF CONTENTS

FROM THE EDITOR

The causes of vascular insufficiency and Hickam vs Ockham 713

Is our reflexive search for a single explanatory diagnosis always reasonable and warranted—or is it truly “just” an academic intellectual exercise?

Brian F. Mandell, MD, PhD

THE CLINICAL PICTURE

Oral condylomata lata 725

The patient had a 3-month history of painless oral lumps and intermittent sore throat.

Carine J. Moezinia, MBBS, MD; Benjamin P. Zuckerman, MBBS; Ayesha Abdul-Hamid, MBChB

1-MINUTE CONSULT

How do I manage my patients with thyrotoxicosis until they see the endocrinologist? 727

Primary care physicians can start beta-blockers promptly for symptomatic relief, obtain radioactive iodine uptake and scan, and start methimazole if high uptake is noted.

Timothy W. Bodnar, MD

COMMENTARY

Matter of the heart: Prioritizing harm reduction in managing infective endocarditis associated with injection drug use 731

Despite specialty society recommendations, many patients do not receive treatment for substance use disorder in conjunction with heart disease treatment.

Akhil Anand, MD; Jared Ontko; Jyothika Yermal; Kush Sehgal, MBBS; Ashley Cantu-Weinstein

SYMPTOMS TO DIAGNOSIS

A 74-year-old woman with purple toes 735

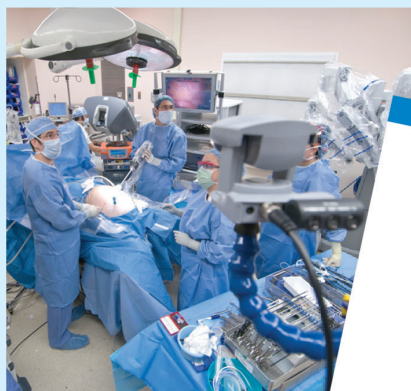While the patient was undergoing treatment for livedoid vasculopathy, her toes started to become purple and she experienced persistent “stinging” pain in her feet.

Baila R. Elkin, MD; Megan McGervey, MD

CONTINUED ON PAGE 710

Upcoming Features

- **Insomnia in older adults:**
A review of treatment options
- **Risk-factor modification to prevent recurrent atrial fibrillation after catheter ablation**

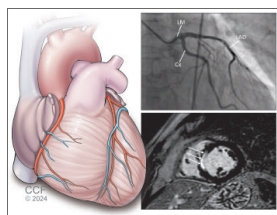


CLEVELAND
CLINIC
JOURNAL OF
MEDICINE

CONTINUED FROM PAGE 709

REVIEW

CME MOC



Myocardial infarction with nonobstructive coronary arteries: 743 Current management strategies

Intracoronary imaging and cardiac magnetic resonance imaging are key tests in the diagnosis.

Kevin G. Buda, DO; Sanjoyita Mallick, DO; Louis P. Kohl, MD

EDITORIAL

The diagnostic dilemma of myocardial infarction without obstructive 755 coronary artery disease: Advanced imaging to the rescue!

Advances in cardiac and coronary imaging and physiologic assessment now allow for a thorough, accurate workup of this condition that accounts for up to 15% of all myocardial infarctions.

Fawzi Zghyer, MD; Khaled M. Ziada, MD

REVIEW

Managing urogenital tract disorders: 10 urology pearls 762 for primary care physicians

These pearls offer evidence-based guidance on issues that physicians are likely to encounter in practice with some frequency.

Neil M. Paige, MD, MSHS; Joseph D. Shirk, MD

LETTERS TO THE EDITOR

Diabetic retinopathy: Screening, prevention, and treatment 723

Ashley Lim

In reply: Diabetic retinopathy: Screening, prevention, and treatment 723

David D. Chong, BA; Nikhil Das, MD; Rishi P. Singh, MD

DEPARTMENTS

CME Calendar 716

CME/MOC Instructions 768

CME/MOC CREDIT

**Test your knowledge
of clinical topics and earn
AMA PRA Category 1 Credit™
and ABIM MOC points**
www.ccjm.org/content/latest-articles-cmemoc

CLEVELAND
CLINIC
JOURNAL OF
MEDICINE