

TABLE OF CONTENTS

FROM THE EDITOR

It's time for a little history of medicine— introducing a new feature in *CCJM* 650

This month, we debut a feature focused on topics in the history of medicine, authored by Cleveland Clinic rheumatologist Adam Brown, MD.

Brian F. Mandell, MD, PhD

THE CLINICAL PICTURE

Skin manifestations in a patient with acute bacterial infective endocarditis 657

During a dialysis session, the patient experienced the onset of rigors accompanied by the appearance of painless purpuric lesions, which developed into petechiae.

Basar Aykent, MD; Ozlem Yilmaz, MD

EDITORIAL

The history of blood cultures: From the research laboratory to the bedside 661

Efforts to prove that bacteria cause endocarditis paved the way for use of blood cultures in the clinic.

Adam J. Brown, MD

1-MINUTE CONSULT

What are options for my patients with erectile dysfunction who have an unsatisfactory response to PDE5 inhibitors? 667

Alternative therapies include intracavernosal injection, vacuum erection devices, and penile prosthesis implantation.

Vivian Hua, BA; Bradley Roth, BS; Andrew Shumaker, MD; Raevti Bole, MD; Petar Bajic, MD

CONTINUED ON PAGE 648

Upcoming Features

- Myocardial infarction without obstructive coronary artery disease: Current management strategies
- Hypoglycemia after bariatric surgery: Management updates



CONTINUED FROM PAGE 647

COMMENTARY

**Effective but inaccessible antiobesity medications:
A call for sharing responsibility for improving access
to evidence-based care** 671

The potentially transformative benefits of second-generation obesity medications have yet to be realized because many patients lack access to these medications.

Bartolome Burguera, MD, PhD; Marcio L. Griebeler, MD; W. Timothy Garvey, MD

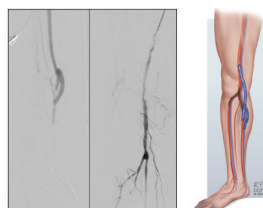
COMMENTARY

The PRECISE trial: How should patients with chest pain be tested? 677

Can a risk score identify individuals with chest pain who can safely forego testing?

Rahul Aggarwal, MD; Ron Blankstein, MD; Deepak L. Bhatt, MD, MPH, MBA

SYMPTOMS TO DIAGNOSIS



**A man with chronic limb-threatening ischemia
and no revascularization options: Can we save his foot?** 683

The patient's right foot was edematous with extensive, dry-appearing gangrene of the big toe, and no pedal pulses were felt.

Fachreza Aryo Damara, MD; Khaled I. Alnahhal, MD; Hassan Dehaini, MD; Georgeanne Botek, DPM; Ammar A. Saati, MD; Pulkit Chaudhury, MD; Lee Kirksey, MD, MBA

REVIEW

CME MOC

**Cervical cancer screening in high-risk patients:
Clinical challenges in primary care** 693

The authors provide up-to-date guidance on cervical cancer screening, surveillance, and management for high-risk patients.

Rebecca S. Gold, MD, MAS; Meagan Williams, MD; Heather M. Wainstein, MD

LETTERS TO THE EDITOR

Primary adrenal insufficiency in adults 665

Anup Katyal, MD

DEPARTMENTS

CME Calendar 655

CME/MOC Instructions 704

CME/MOC CREDIT

Test your knowledge
of clinical topics and earn
AMA PRA Category 1 Credit™
and **ABIM MOC points**
www.ccjm.org/content/latest-articles-cmemoc

CLEVELAND
CLINIC
JOURNAL OF
MEDICINE