

TABLE OF CONTENTS

FROM THE EDITOR

Continuous glucose monitoring: High-tech devices still need some low-tech backup 585

High-end devices that monitor patients' physiology offer many benefits, but device malfunctions and disruptions are not rare events.

Brian F. Mandell, MD, PhD

THE CLINICAL PICTURE.....

Salt-and-pepper skin pigmentation 593

Dermoscopy of the skin lesions revealed homogeneous depigmented areas with perifollicular pigmentation.

Ramachandran Gnanasuriyan, MD; Savitha Murali, MD; Sheela Kuruvila, MD

THE CLINICAL PICTURE.....

Fixed drug eruption due to ibuprofen 597

The patient had a 2-month history of a lesion on the left groin that caused a burning sensation.

Aneri Patel, BS; Ilana D. Breen, MD; Joshua M. Schulman, MD; Apra Sood, MD

SYMPTOMS TO DIAGNOSIS

Abdominal pain in a patient with epistaxis, telangiectasias, and arteriovenous malformations 601

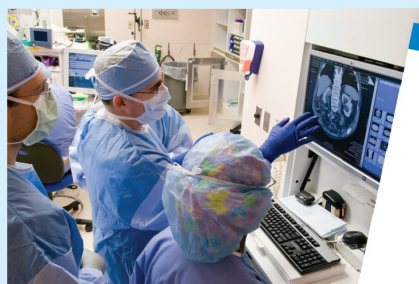The pain was radiating to the back, exacerbated by eating, and accompanied by intermittent nausea and fatigue.

Akash Mathavan, MD; Akshay Mathavan, MD; Andreas Giovanni Zori, MD; Marc Stuart Zumberg, MD; Jeb M. Justice, MD; Ali Ataya, MD

CONTINUED ON PAGE 584

Upcoming Features

- Cervical cancer screening in high-risk patients: Clinical challenges in primary care
- How do I manage my patients with thyrotoxicosis until they see the endocrinologist?



CLEVELAND
CLINIC
JOURNAL OF
MEDICINE

CONTINUED FROM PAGE 583

REVIEW

Using continuous glucose monitoring data in daily clinical practice 611

The authors review data elements of the Ambulatory Glucose Profile Report, a standardized format for displaying glucose monitoring data, and present a structured approach to using the data to optimize glycemic management.

Thomas W. Martens, MD; Gregg D. Simonson, PhD; Richard M. Bergenstal, MD

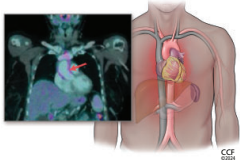
REVIEW

CME MOC

Incidentally detected noninfectious thoracic aortitis: A clinical approach 621

The author reviews how aortitis is detected, its many possible causes, and the workup and treatment of patients who are found to have it.

Alison H. Clifford, MD, MSc



EDITORIAL

Sorting out aortic aneurysms: A team enterprise 635

Aortic aneurysms present considerable diagnostic and treatment challenges owing to their diverse causes, incomplete understanding of pathogenesis, and variations in presentation and disease course.

Gary S. Hoffman, MD, MS, MACR

DEPARTMENTS

CME Calendar 591**Correction 638**

In the August 2024 issue, the article “*Helicobacter pylori*: A concise review of the latest treatments against an old foe” by Aldhaleei WA, Wallace MB, Harris DM, Bi Y [Cleve Clin J Med 2024; 91(8):481–487; doi:10.3949/ccjm.91a.24031] contained an error in the first paragraph of the section titled “Proton pump inhibitor or potassium-competitive acid blockers” (pages 484–485).

CME/MOC Instructions 640**CME CREDIT TEST**

Visit **WWW.CCJM.ORG**
Test your knowledge
of clinical topics and earn
AMA PRA Category 1 Credit™
and **ABIM MOC points**

CLEVELAND
CLINIC
JOURNAL OF
MEDICINE