

**Li-wen Zhang, MD**

Department of Dermatovenereology,  
Chengdu Second People's Hospital,  
Chengdu, Sichuan, China

**Wen-ju Wang, MD**

Department of Dermatovenereology,  
Chengdu Second People's Hospital,  
Chengdu, Sichuan, China

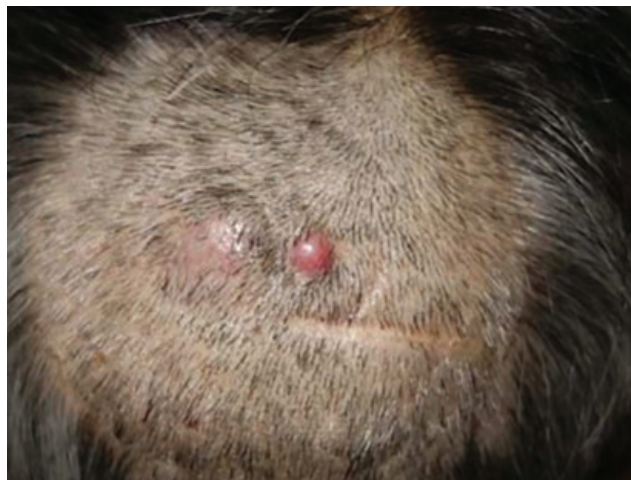**Tao Chen, MD, PhD**

Department of Dermatovenereology,  
Chengdu Second People's Hospital,  
Chengdu, Sichuan, China

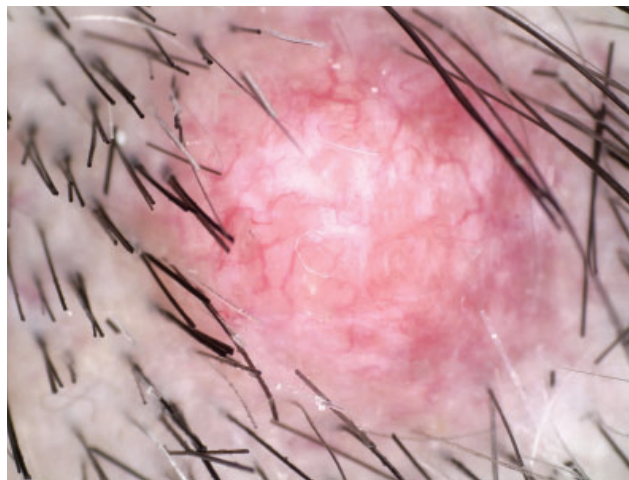
**Rong-hua Xu, MD**

Institute of Dermatology  
Chengdu Second People's Hospital,  
Chengdu, Sichuan, China

# Cutaneous metastasis from gastric carcinoma



**Figure 1.** Two smooth, pink, rubbery nodules in the occipital region. The nodules had grown in size over the past 3 months.



**Figure 2.** Dermoscopy of a round, pink nodule showed thick, linear, and arborizing vessels, shiny white structureless areas, and loss of follicular openings.

**A** 75-YEAR-OLD MAN presented with a 3-month history of asymptomatic nodules with alopecia on the scalp. He said that 3 years before this presentation, he had undergone total gastrectomy with Roux-en-Y anastomosis and extended lymphadenectomy due to poorly differentiated, diffuse gastric adenocarcinoma with loco-regional metastatic lymph nodes. For 24 weeks after that, he had received 8 cycles of chemotherapy with epirubicin, cisplatin, and 5-fluorouracil. At a 2-year follow-up, there was no evidence of recurrence or metastasis.

On examination, 2 round, smooth, pink, rubbery nodules were noted in the occipital region (**Figure 1**). The patient said that the nodules had gradually grown in size over the past 3 months.

Dermoscopy showed a round, pink nodule with thick linear and arborizing vessels, shiny white structureless

areas, and loss of follicular openings (**Figure 2**). Biopsy of a nodule revealed adenocarcinoma with diffuse infiltration of carcinoma cells arranged as single cells and forming tubules and glands in the dermis and subcutis. On immunohistochemical study, the neoplastic cells were positive for cytokeratin 7, cytokeratin 20, caudal-type homeobox 2, and villin, and negative for special AT-rich sequence-binding protein 2. The patient was referred to the oncology department, where metastasis to the abdominal cavity and lymph nodes was identified. The patient refused further chemotherapy and died 1 year later.

## CUTANEOUS METASTASIS FROM GASTRIC CARCINOMA

Cutaneous metastases from visceral carcinomas are rare, with an overall incidence of 0.7% to 9%.<sup>1</sup> The

doi:10.3949/ccjm.90a.22085

scalp is one of the most frequent cutaneous sites of distant metastasis from visceral carcinomas, and most lesions have a nodular presentation.<sup>2</sup> Alopecia neoplastica is a cutaneous metastasis due to underlying cancer spreading to the scalp, accounting for 4% of all cutaneous metastasis, and associated with a poor prognosis.<sup>3</sup>

Alopecia neoplastica usually presents as single or multiple asymptomatic, reddish-violet or flesh-colored nodules with scarring alopecia, and is most prevalent in the frontal or parietal region of the scalp.<sup>3</sup> It can also manifest as a plaque or patch.<sup>3</sup> The primary tumor associated with alopecia neoplastica is most frequently in the gastrointestinal tract, followed by the

breast, kidney, lung, and thyroid.<sup>3</sup> Adenocarcinoma is the most frequent histologic subtype.<sup>3</sup>

The diagnosis of alopecia neoplastica can be challenging, but timely pathologic examination is critical, and immunohistochemistry is helpful in determining the origin of the tumor. It must be distinguished from common and benign alopecia conditions. Alopecia neoplastica indicates a poor prognosis for cancer patients, and a comprehensive evaluation is needed to guide treatment.

## DISCLOSURES

The authors report no relevant financial relationships which, in the context of their contributions, could be perceived as a potential conflict of interest.

## REFERENCES

1. Lookingbill DP, Spangler N, Sexton FM. Skin involvement as the presenting sign of internal carcinoma. A retrospective study of 7316 cancer patients. *J Am Acad Dermatol* 1990; 22(1):19–26. doi:10.1016/0190-9622(90)70002-y
2. Betlloch-Mas I, Soriano-García T, Boira I, et al. Cutaneous metastases of solid tumors: demographic, clinical, and survival characteristics. *Cureus* 2021; 13(11):e19970. doi:10.7759/cureus.19970
3. Paolino G, Pampena R, Grassi S, et al. Alopecia neoplastica as a sign of visceral malignancies: a systematic review. *J Eur Acad Dermatol Venereol* 2019; 33(6):1020–1028. doi:10.1111/jdv.15498

Address: Tao Chen, MD, PhD, Department of Dermatovenereology, Chengdu Second People's Hospital, 165 Caoshi Street, Chengdu 610017, Sichuan, China; 13980427003@163.com and Rong-hua Xu, MD, Institute of Dermatology, Chengdu Second People's Hospital; elvis0508@sina.com