

TABLE OF CONTENTS

FROM THE EDITOR

To prophylax or not to prophylax for endocarditis: Still a question **455**

Give prophylactic antibiotics before invasive dental procedures? On the surface, it may seem sensible. But we have more to learn about the successful clearance of bacteria from the bloodstream and why protective mechanisms occasionally fail.

Brian F. Mandell, MD, PhD

THE CLINICAL PICTURE.....

'Kissing tonsils' and splenic infarction from infectious mononucleosis **463**

A 36-year-old male presented with severe pain in the left upper quadrant after 10 days of cough, sore throat, and fever.

Nicholas L. Kensey, DO; James Higgs, MD

1-MINUTE CONSULT

Getting to the root of the problem: Should my patient receive antibiotics before dental procedures to prevent infective endocarditis? **465**

Individual risk depends on inherent patient and procedural risk factors. The authors offer practical points to aid decision-making.

Cindy McCartney, MD; Thomas Crilley, MD; Steven Gordon, MD

GUIDELINES TO PRACTICE

CME | MOC

A new policy update on breastfeeding: What all clinicians need to know **469**

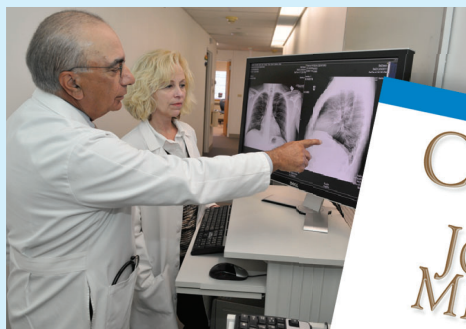
An overview of current American Academy of Pediatrics policy, directed to clinicians of all disciplines who may interact with breastfeeding mothers and their babies.

Heidi Szugye, DO, IBCLC, FAAP; Ali Murra, BS; Suet Kam Lam, MD, IBCLC, MPH, MS, FAAP

CONTINUED ON PAGE 454

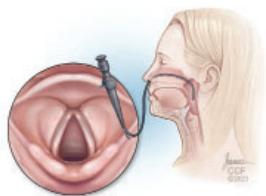
Upcoming Features

- Metformin for weight loss in adults with obesity
- When to keep mpox in the differential diagnosis



CONTINUED FROM PAGE 453

REVIEW



Hoarseness: When to observe and when to refer 475

A concise, illustrated review of basic laryngeal anatomy and function, symptoms of vocal-fold pathology, and current guidelines from the American Academy of Otolaryngology–Head and Neck Surgery.

Ellen L. Ferraro, MD; Rebecca Chota Nelson, MD; Paul C. Bryson, MD, MBA

REVIEW

Evaluating troponin elevation in patients with chronic kidney disease and suspected acute coronary syndrome 483

The authors examine challenges in diagnosing acute coronary syndrome in patients with chronic kidney disease and provide a diagnostic algorithm to risk-stratify these patients.

Lorenzo Braghieri, MD; Osamah Z. Badwan, MD; Warren Skoza, MD; Maan Fares, MD; Venu Menon, MD

SYMPTOMS TO DIAGNOSIS

Unilateral green pleural effusion in a 22-year-old woman 491

Chills, night sweats, palpitations, and a 5-lb weight loss, preceded by 6 months of progressive dyspnea, fatigue, and reduced exercise tolerance. What is the diagnosis?

Sauradeep Sarkar, MD; Utsav Shrestha, MD; Huda Elzahrany, MD; Bathmapriya Balakrishnan, BMedSci, BMBS, FCCP

REVIEW

Late complications after allogeneic hematopoietic cell transplant: What primary care physicians can do 499

Cardiovascular, metabolic, endocrine, rheumatologic, orthopedic, infectious, neurologic, and cognitive complications are examined, as well as secondary malignancies, psychiatric disorders, and impairments in quality of life and sexual health.

Lauren M. Granat, DO, MS; Mariah Ondeck, MD; Bennett Osantowski, MD; Michael Sheu, MD; Vishwanath Ganesan, MD; Seth Rotz, MD; Betty K. Hamilton, MD

LETTERS TO THE EDITOR

Computed tomography of the head 461

Rahul B. Ganatra, MD, MPH

Computed tomography of the head 461

Gilad Muth, DO; Thomas A. Bayer, MD; Richard Libman, MD

Severe skin rashes 461

Li-wen Zhang, MD; Juan Wu, MD, PhD; Tao Chen, MD, PhD

Severe skin rashes 462

Valerie Jaroenpuntaruk, MD; Adam Gray, MD

DEPARTMENTS

CME Calendar 458

CME/MOC Instructions 510