

TABLE OF CONTENTS

FROM THE EDITOR

Viruses change; we can, too

135

As we learn more about the mpox (formerly monkeypox) virus, Sossai et al in this issue of the *Journal* discuss how our understanding of its link to variola has led to therapeutic and prophylactic vaccination options.

Brian F. Mandell, MD, PhD

REVIEW

Smallpox and monkeypox: Looking back and looking ahead

141

Two vaccines have been developed for mpox prevention, but clarity is needed on when and how to use them.

Paolo Sossai, MD, PhD; Domenico Staiti, MD; Massimiliano Cannas, MD; Piero Grima, MD

THE CLINICAL PICTURE

Mass under the lip

145

The mass had grown slowly over several weeks while the patient was in rehabilitation after a stroke.

Sagar Khanna, BDS, DDS

1-MINUTE CONSULT

What is the rationale for the laboratory workup for suspected pheochromocytomas and paragangliomas?

150

The decision to test is best guided by clinical suspicion. Test results should be interpreted with careful consideration of how the samples were collected.

Hiba Z. Hashmi, MD; Muhammad Arslan Arif Maan, MD; Laura LaFave, MD

1-MINUTE CONSULT

Fundic gland polyps: Should my patient stop taking PPIs?

157

Of the 2 types of these polyps, the sporadic type is linked to proton pump inhibitor use, whereas the syndromic type occurs on a background of familial adenomatous polyposis—a key distinction.

Jiafei (Carolyn) Niu, DO; Yi Qin, MD

CONTINUED ON PAGE 134

Upcoming Features

- Heart failure with reduced ejection fraction: A detailed look at the 2022 guideline
- Multiple sclerosis and reproductive issues: 20 questions



CLEVELAND
CLINIC
JOURNAL OF
MEDICINE

CONTINUED FROM PAGE 132

COMMENTARY

The cost of 'free': Advising patients about sponsored genetic testing 161

A breakdown of benefits and drawbacks of sponsored genetic testing that clinicians can use to help patients make informed decisions.

Stephanie Allison Larson, PhD, HEC-C; Joseph Liu, MS; David Flannery, MD; Marsha Michie, PhD; Paul J. Ford, PhD

REVIEW

Colovesical fistula in men with chronic urinary tract infection: A diagnostic challenge 165

Most cases are in older men with diverticular disease, Crohn disease, cancer, or iatrogenic injury. Suspect it especially in these patients with UTI symptoms refractory to conventional treatments.

Risheng Xu, DO; Austin Vaughan, DO; Mitchell Fagan, DO; Dylan P. Schumacher, MD; Verra Wekullo, MD; Bruce Gehrke, MD

REVIEW

To repeat or not to repeat? Measuring bone mineral density during antiresorptive therapy or a drug holiday 173

The authors present evidence for and against monitoring bone mineral density in these patients, arguing against a one-size-fits-all approach.

Tayyab S. Khan, MD; Partha Sinha, MD, PhD; Harold Rosen, MD

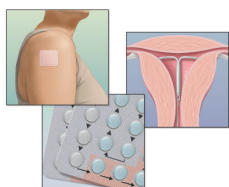
CURRENT DRUG THERAPY

CME | MOC

Update on current contraceptive options: A case-based discussion of efficacy, eligibility, and use 181

Rates of unintended pregnancy are high in the United States. Clinicians need to be well-informed about the full spectrum of contraceptive options to improve reproductive autonomy.

Alexa Nicole Fiffick, DO, MBS, NCMP; Tara K. Iyer, MD, NCMP; Tiffany Cochran, MD, MA, NCMP; Pelin Batur, MD, FACP, NCMP



DEPARTMENTS

CME Calendar 137

CME/MOC Instructions 192

CME CREDIT TEST

Visit WWW.CCJM.ORG
Test your knowledge
of clinical topics and earn
AMA PRA Category 1 Credit™

CLEVELAND
CLINIC
JOURNAL OF
MEDICINE