

TABLE OF CONTENTS

FROM THE EDITOR

A useful gap

587

A very low anion gap can suggest a laboratory measurement error or provide a clue to clinically important protein abnormalities or ingestions that warrant specific investigation.

Brian F. Mandell, MD, PhD

THE CLINICAL PICTURE

vOka vaccine-associated disseminated varicella zoster

599

The patient had received the live attenuated vaccine 1 month before presentation. He had no history of varicella infection.

Peter R. Hyson, MD; Louis B. Polish, MD

THE CLINICAL PICTURE

Masked tinea

601

A result of daily mask-wearing during a long hospitalization.

Ayano Hamai, MD; Yukinori Harada, MD, PhD

1-MINUTE CONSULT

Should midodrine be used as an intravenous vasopressor-sparing agent in septic shock?

603

Research and robust data are still lacking regarding use of midodrine in this setting.

Simran Gupta, MD; Ayan Sen, MD; Aman Verma, DO

1-MINUTE CONSULT

Should I start an SGLT-2 inhibitor in my patient with heart failure and chronic kidney disease?

607

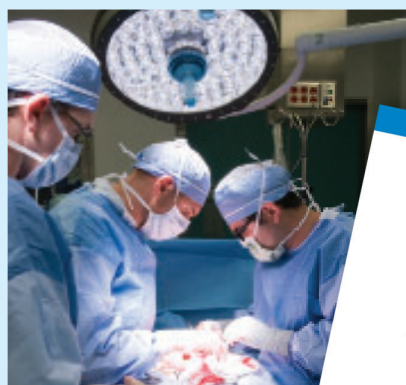These conditions often co-exist and can have complex interactions. The progression of kidney disease increases the risk of major adverse cardiovascular events.

Richard Sekerak, MD; Johanna Ben-Ami Lerner, MD; Pooja Prasad, MD; Megha Prasad, MD

CONTINUED ON PAGE 585

Upcoming Features

- Understanding *MTHFR* mutations and thrombosis risk
- Cirrhosis: Primary care approaches to screening, immunization, and lifestyle modifications



CLEVELAND
CLINIC
JOURNAL OF
MEDICINE

CONTINUED FROM PAGE 581

1-MINUTE CONSULT

Should you use compression duplex ultrasonography to detect deep vein thrombosis to evaluate unexplained fevers? 611

The authors provide recommendations on when to order imaging of the extremities in the evaluation of hospitalized patients with unexplained fever.

Daniel Rozenbaum, MD; Anirudh Yalamanchali, MD, MS; Deborah Hornacek, MD, FSVM

GUIDELINES TO PRACTICE

Inpatient glycemic management in noncritically ill patients: Updated guidelines 615

The guidelines include a role for newer diabetes technologies and nontraditional insulin and noninsulin therapies.

Michelle D. Lundholm, MD; Oscar L. Morey-Vargas, MD

REVIEW

CME MOC

Evaluating a low anion gap: A practical approach 619

In teaching and in practice, little attention is given to a low anion gap, an oversight that can result in a missed opportunity to diagnose acute or chronic disorders requiring treatment.

Lawrence A. Haber, MD; Gurpreet Dhaliwal, MD; Lowell Lo, MD; Gabrielle Rizzuto, MD, PhD

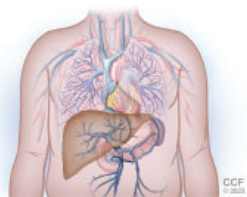
1-MINUTE CONSULT

What is the most appropriate management of patients with acute decompensated heart failure who develop in-hospital hypotension? 625

The authors offer a tailored approach to risk-stratification in these patients that focuses on early recognition and management of symptomatic and clinically significant hypotension.

Lorenzo Braghieri, MD; Warren A. Skoza, MD; Osamah Z. Badwan, MD; Paulino Alvarez, MD

REVIEW

**Portopulmonary hypertension: A focused review for the internist 632**

Key aspects of screening, diagnosis, and treatment, and a review of the various pulmonary hemodynamic patterns encountered in patients with liver disease.

Mamta S. Chhabria, MD; Leela Krishna Teja Boppana, MD; Gaurav Manek, MD; Adriano R. Tonelli, MD, MSc

LETTERS TO THE EDITOR

A new paradigm for adult ADHD 592

Vania Modesto-Lowe, MD, MPH; Samantha Frigon

A new paradigm for adult ADHD 592

Uche Nkanginieme, Medical student

In Reply: A new paradigm for adult ADHD 593

Michael J. Manos, PhD; Elizabeth J. Short, PhD

DEPARTMENTS

CME Calendar 590**CME/MOC Instructions 640**