

TABLE OF CONTENTS

FROM THE EDITOR

Some complexities of diabetes and the heart 13

Patients with diabetes are at greater risk of coronary artery disease than their peers without diabetes. That's straight and simple. But there the simplicity ends.

Brian F. Mandell, MD, PhD

THE CLINICAL PICTURE

Median rhomboid glossitis caused by tongue-brushing 15

The patient had started vigorous brushing 1 month earlier after being told that she had bad breath.

Tatsuya Shindo, MD

1-MINUTE CONSULT

What are my obligations to my incarcerated patient? 18

A court order authorizes a blood transfusion, but the incarcerated patient refuses the transfusion. As the caregiver, am I obligated to follow the court order against the patient's wishes?

Farah Acher Kaiksow, MD, MPP; Deval Patel, MD; Norman Fost, MD, MPH

1-MINUTE CONSULT

Which patients hospitalized with alcohol withdrawal syndrome should receive high-dose parenteral thiamine? 22

The authors briefly outline risk factors for Wernicke encephalopathy and when high-dose parenteral thiamine is indicated.

Rahul B. Ganatra, MD, MPH; Anthony C. Breu, MD; Matthew V. Ronan, MD

REVIEW

Bone turnover markers to monitor oral bisphosphonate therapy 26

Rapid changes in levels of bone turnover markers can be useful in monitoring the effectiveness of therapy and improving adherence to therapy.

Nikita Ashcherkin, MD; Archana A. Patel, MD, MPH; Alicia Algeciras-Schimmich, PhD; Krupa B. Doshi, MD, FACE

CME MOC

CONTINUED ON PAGE 12

Upcoming Features

- A stepwise approach to resistant hypertension
- Myasthenia gravis: When first-line treatments fail



CONTINUED FROM PAGE 8

EDITORIAL

Making best use of bone turnover markers to monitor oral bisphosphonate therapy 32

Clinical applications of bone turnover markers can include determining when to start or end a bisphosphonate “holiday” and measuring treatment response.

Sarah Keller, MD

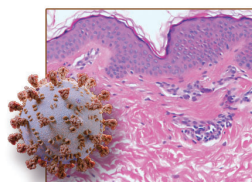
SYMPTOMS TO DIAGNOSIS

Central vision loss in a 44-year-old woman 35

The patient had a wide range of symptoms and comorbidities, resulting in a complicated differential diagnosis. Careful evaluation eventually led to a focus on sexually transmitted infection.

Walker M. Schmidt, BS; Nirosha D. Perera, MD; Blake H. Fortes, MD; Benjamin A. Nelson, MD; Wendy M. Smith, MD; Hannah C. Nordhues, MD

REVIEW

**Update in cutaneous manifestations of COVID-19: Special populations 43**

Recognition of skin reactions and their implications is beneficial to clinicians in shaping patient counseling and anticipatory guidance. An illustrated guide.

Samantha Polly, MD; Inga M. Muser, MD; Anthony P. Fernandez, MD, PhD

REVIEW

Statins may increase diabetes, but benefit still outweighs risk 53

The weight of the evidence suggests that statin use is associated with an increased risk of new-onset diabetes mellitus, but the magnitude of the effect has varied across studies.

Byron J. Hoogwerf, MD, FACP, FACE

DEPARTMENTS

CME Calendar 7**CME/MOC Instructions 64****CME CREDIT TEST**

Visit WWW.CCJM.ORG
Test your knowledge
of clinical topics and earn
AMA PRA Category 1 Credit™

CLEVELAND
CLINIC
JOURNAL OF
MEDICINE