

# STUDIES ON THE EFFECTIVENESS OF INSULIN IMPLANTS

E. PERRY McCULLAGH, M.D. and LENA A. LEWIS, Ph.D.

Ever since an active preparation of insulin was secured, methods have been sought for administering the hormone by some means other than injection. Major<sup>1</sup> reviewed the results which had been reported up to 1936. Since then numerous reports have been published, of which the following summarizes the more pertinent findings.

Parkes and Young<sup>2</sup> in experiments on rabbits found that the hypoglycemic action of amorphous insulin pellets was only slightly more prolonged than that of a similar amount of insulin in solution administered subcutaneously. Crystalline insulin pellets had a similar duration of action despite the fact that the tissue capsule around the pellet contained appreciable amounts of insulin.

Using depancreatized dogs Mark et al<sup>3</sup> found that pellets of crystalline zinc insulin with protamine were effective for as long as 100 hours. The pellets on examination four hours after implantation were swollen, and there was edema at the site of implantation.

Cutting et al<sup>4</sup> reported briefly on the effective use of pellets of cholesterol and insulin in depancreatized dogs. They observed a slow release of insulin during periods as long as 13 days. The irregularities of absorption were too great to justify the trial of such pellets in the clinical treatment of diabetes.

## EXPERIMENTAL

*Methods.* Adult dogs maintained on a constant diet were used. They were fed at 3 p. m. daily. Blood was drawn from the saphenous vein when the dog was in the postabsorptive state. All excitement was carefully avoided. Blood sugar was determined by the Somogyi modification of the micro-Shaffer-Hartman method.<sup>5</sup> Blood sugars were taken on the untreated animal at two-hour intervals. At the same times on other days they were taken following subcutaneous administration of amorphous insulin to determine the animal's response to various amounts of this hormone. Protamine zinc insulin was also tested. Preliminary experiments showed that cylinders packed with albumen with a molecular weight approximating that of insulin would deliver roughly 1.0 mg. per day to solution if the inner diameter of the cylinder was 2.0 mm.

and it was open at each end. Tubes of this size and 100 mm. in length were then packed with 25 to 30 mg. crystalline insulin and implanted subcutaneously.

Pellets weighing 325 mg. with a surface area of 2.5 sq. cm. and composed of a mixture of insulin and cholesterol were prepared. Twenty per cent insulin and 80 per cent cholesterol proved most satisfactory. They were sterilized by heating at 100° C. for one hour on three successive days. The capsules and pellets were implanted subcutaneously using local anesthesia.

*Results.* Following subcutaneous implantation of the silver capsules filled with insulin the blood sugar levels fell to approximately those observed following 20 to 30 units of protamine insulin. Chart 1 summarizes the results obtained on Dog N. After three to four weeks when the capsules were removed they were found to contain appreciable amounts of potent insulin. Examination of the tissue surrounding the capsule showed a mass of granulation and young fibrous tissue typical

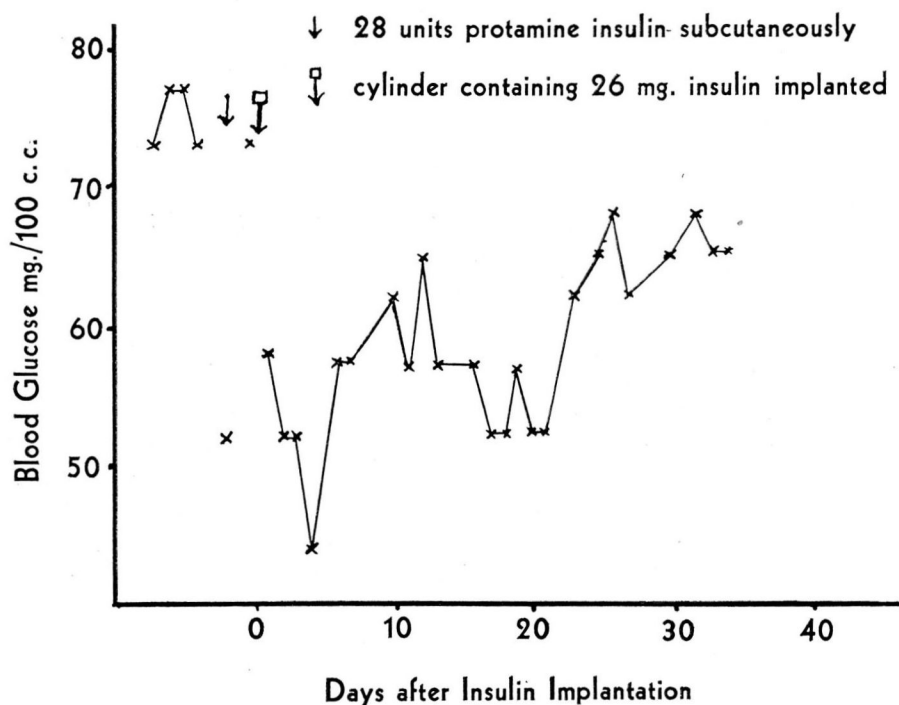


CHART 1

## EFFECTIVENESS OF INSULIN IMPLANTS

of that forming around a nonirritating foreign body. It appears that the release of insulin is greatly impeded by this tissue.

The implantation of the insulin-cholesterol pellets was also followed by a marked drop in blood glucose. Chart 2 summarizes the results on Dog S. In some cases a second pellet was implanted about one month after the first one. In each case the response was similar to that following the first implantation which showed that the animal was still sensitive to insulin. After several weeks when the pellets were removed they were surrounded by a capsule of tissue which presented a picture on histological examination similar to that surrounding the silver capsule-insulin implant. The pellet inside the tissue capsule had become "mushy," and it appeared to be maintained in shape by the tissue surrounding it. The entire pellet was moist. The material, however, still had marked insulin potency. Further studies are being carried out on relative effectiveness of different paths for the administration of insulin.

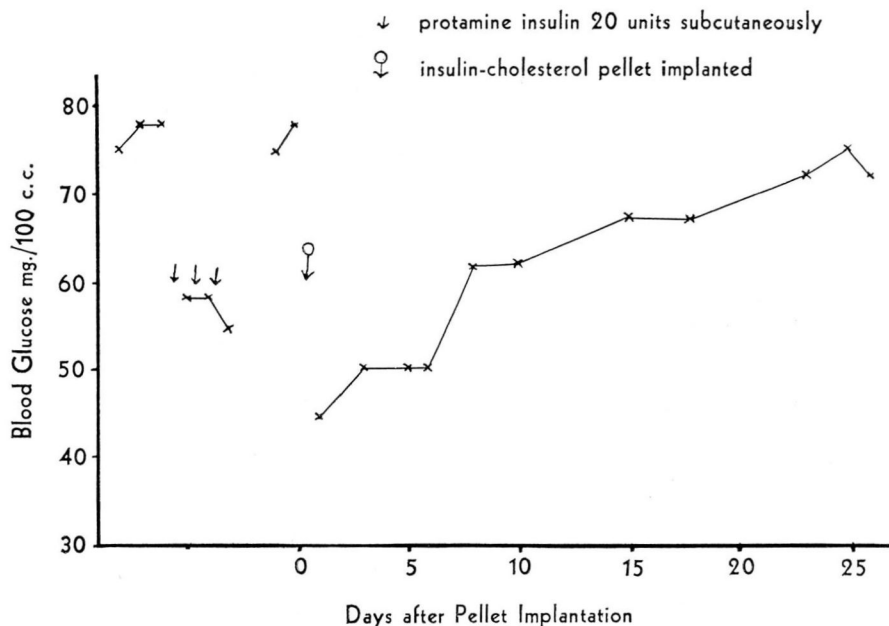


CHART 2

### SUMMARY

The subcutaneous implantation into the dog of silver capsules firmly packed with crystalline insulin is followed by a definite drop in the blood sugar level. The insulin effect gradually decreased until no appre-

ciable change in blood sugar level was observed after two to three weeks despite the fact that appreciable amounts of potent insulin were still in the capsule. Similar results were obtained following the subcutaneous implantation of pellets of insulin and cholesterol.

*We are indebted to Eli Lilly and Co. for the crystalline insulin used in these experiments.*

#### REFERENCES

1. Major, R. H.: Intranasal application of insulin; experimental and clinical experiences, *Am. J. M. Sc.* 192, 257, 1936.
2. Parkes, A. S., and Young, F. G.: Influence of subcutaneous implantation of tablets of solid insulin on blood sugar level of rabbit, *J. Endocrinol.* 1:108, 1939.
3. Mark, J., and Biskind, G. R.: Increased duration of insulin action by use of protamine insulin in pellet form, *Endocrinol.* 26:444, 1940.
4. Cutting, W. C., Morton, M. C., and Colin, R. B.: Subcutaneous administration of insulin by pellets, *Endocrinol.* 28:679, 1941.
5. Somogyi, M.: Notes on sugar determination, *J. Biol. Chem.* 70:599, 1926.