

BRONCHOLITHIASIS

Report of Two Cases

H. S. VanORDSTRAND, M.D., PAUL M. MOORE, Jr., M.D.
and H. E. HARRIS, M.D.

In patients presenting the symptoms and physical findings of partial to complete bronchial obstruction, a broncholith should be considered as a possible etiologic factor in addition to the two entities usually considered, namely, an aspirated foreign body or a bronchial tumor.

In its strictest sense the term broncholithiasis refers to the formation of calculi in a bronchus. It is the accepted diagnostic term for patients having bronchial stones, although in the majority of cases the calculus originally develops extrabronchially, for which reason a few authors in the literature mention pneumoliths, pulmoliths, and lung calculus or lung stone. As the majority of patients with broncholithiasis frequently experience an asthmatoïd type of wheeze, the term stone asthma is also used. Patients who are able to expel these stones by themselves experience a severe paroxysmal type of cough which the French have accurately described as "colique bronchique". The occurrence of "lung stones" has been recognized since the days of Aristotle and Galen, but a comprehensive clinical report did not appear until Schenck¹ recorded his observations in 1600.

The entity is not very common as is indicated by the fact that Lloyd² found only 18 cases reported in the English literature between 1900 and 1930. Lloyd reported four cases in 1930, and since that time only four additional cases of broncholithiasis have been reported in the English literature. In the majority of these the diagnosis was made after the patient had expelled the stone himself. In most instances only a single or a few calculi were expelled, although one patient coughed up 400 broncholiths in his lifetime.

Broncholithiasis develops when a calcareous deposit gains entrance into, or forms in, the lumen of the bronchus and may, therefore, be either of peribronchial or of endobronchial origin. As has been previously mentioned those gaining entrance into the bronchus from without are of much the greater frequency. A considerable number have been proved to be of tuberculous origin in the form of a calcification of a peribronchial or peritracheal lymph node. In other instances the calcareous extrabronchial formation may be due to other types of lung infection, such as pneumonia or previous lung abscess, and in some instances to a previous pulmonary infarction. Endobronchial calcareous formations may be caused by irritation and inflammation as a sequela

of previously aspirated foreign bodies from without, or as a piling up of further calcareous formations from aspirations into the lower respiratory tract of rhinoliths or tonsiliths from the upper respiratory tract.

Why the lung is such a frequent site of calcareous formation has never been completely explained. Long before biochemical analysis postmortem observers marveled at man's ability to form stones from soft tissues, but even since the advent of biochemistry our knowledge of the processes by which calcareous deposits are formed has been very limited. Chemically, with few exceptions, these pathologic deposits are quite similar to normal bone, 85 to 90 per cent calcium phosphate and 10 to 15 per cent calcium carbonate. Wells³ shows the close similarity between calcification and ossification. His opinion, which Harbitz⁴ concurs, is that the processes differ only morphologically, the calcium deposit in calculi being at first in granulous form, although later it may become homogeneous through fusion. Wells states that "within such deposits there are usually no living cells and no further changes take place unless it be absorption or the addition of more calcium salts." Calcium salts, according to Wells, are absorbed to a greater extent than can be held in solution by the arterial blood, so that no calcium is found deposited in the right side of the heart. However, after the blood passes through the lungs and loses a large part of its carbon dioxide, the calcium salts are precipitated in the pulmonary veins, the left heart, and are taken up by adjacent tissues.

The symptoms and clinical picture of broncholithiasis depend upon the extent of bronchial obstruction. With residual obstruction the patient may have only a chronic or paroxysmal cough. Obstruction of the bronchus produces atelectatic and inflammatory changes, and thus the findings may be those of pneumonitis, atelectasis, bronchiectasis, or lung abscess, with a history of bouts of fever and even occasional hemoptysis. With partial obstruction the patient frequently notes an asthmatoïd type of wheezing.

In the past the diagnosis of broncholithiasis usually has been made after the stone has been brought up with a fit of coughing. The patient may be seized with an attack of coughing, expiratory dyspnea, and marked loud wheezing very closely resembling an asthmatic attack. Hemoptysis of varying degree may or may not follow the attack. In the absence of a history of expelling a stone the diagnosis may be suspected roentgenographically but confirmed bronchoscopically.

Treatment consists of measures directed toward dislodging the bronchial calculus. At present there is no known way of preventing a recurrence. If the stone is not easily removable through the bronchoscope, it should only be manipulated gently as this procedure is not without danger. Pneumothoraces have occurred during attempted

bronchoscopic removal of broncholiths which initially formed extrabronchially without having gained complete entrance into the broncholumen. If the calculus can be only partially dislodged by the bronchoscope, expectorants and postural drainage exercises often help the patients to expel the stone. Chemotherapy is indicated in patients having clinical evidence of some form of suppurative pneumonitis behind the bronchial obstruction. Thoracic surgery such as subtotal lobectomy, lobectomy, or pneumonectomy may be indicated where long standing bronchial obstruction has led to irreparable damage, particularly in marked cicatricial bronchostensis and bronchiectasis.

REPORT OF CASES

Case 1. A 59 year old executive registered for the allergy department on October 31, 1941 with the chief complaints of a chronic cough and "attacks of asthma" which had been present for twelve months. Associated with the cough and episodes of wheezing he had occasional bouts of low grade fever. His expectoration was ordinarily mucoid and very minimal except when he experienced a fever, at which time it would become more productive and purulent, but he had never experienced hemoptysis.

The positive findings on the physical examination were confined entirely to the chest. A decreased percussion note was noted at the right base posteriorly between the levels of the eighth and tenth dorsal spines along with decreased breath sounds in this same area. Some diminution in breath sounds was noted over the right lower anterior chest as well. The temperature was normal at the time of the examination. Roentgen examination of the chest (Fig. 1) revealed a right deviation of the lower end of the trachea with partial atelectasis in the right lower lobe and a minimal degree of shifting of the lower mediastinum to the right. Calcifications in the right lower lung and right hilar region were not considered to be of clinical significance at the time.

A bronchoscopic examination revealed a calcific mass almost obstructing the right main stem bronchus just above the middle lobe orifice. This was partially removed with the grasping forceps. The patient was sent home to return in one week for another bronchoscopy.

Because of an exacerbation of symptoms upon his return he entered the hospital. The bronchoscopic procedure was repeated, and one relatively large calcific mass and several small pieces were removed. No further broncholiths were observed. After the large stone had been removed, a large amount of pus was released.

The patient remained in the hospital for nine days with continuous elevation of the foot of his bed, expectorants, postural drainage exercises, and sulfathiazole (the blood level being maintained at approximately 3 to 4 mg. per cent). On these measures all of his symptoms subsided, and he was entirely symptom free the last five days of his stay.

A progress roentgen examination of the chest on November 12 showed that the atelectasis had cleared, although a small area of calcification could still be observed in the area from which the broncholiths had been removed bronchoscopically (Fig. 2). For this reason another bronchoscopy was done which revealed one medium sized broncholith which could be manipulated, but not extracted. The patient was discharged on expectorants and postural drainage exercises. One week after returning home he expelled the calculus himself. Fig. 3 shows the broncholiths of this case.

The patient returned in four weeks and stated that he felt fine in all respects and was entirely symptom free. Physical examination of the chest revealed no abnormalities of any kind. However, it seemed advisable to make a lipiodol bronchogram of the right middle and right lower lobes to exclude bronchiectasis because the previous symptoms

BRONCHOLITHIASIS

had suggested bronchial obstruction of one year's duration. The bronchograms revealed an entirely normal tracheobronchial tree. In addition blood calcium, phosphorus, cholesterol, and phosphate determinations revealed normal values.

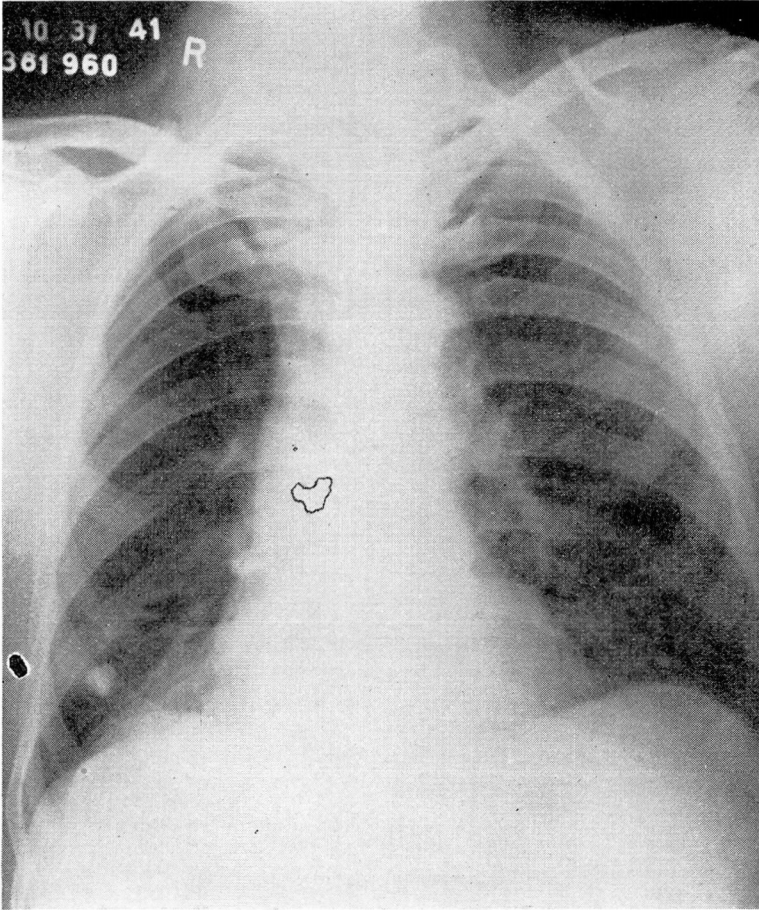


FIGURE 1: Initial x-ray of Case 1. Area of calcific mass encircled. Originated extra-bronchially to produce partial bronchial obstruction through eroding bronchial wall.

COMMENT

This case illustrates the value of bronchoscopy in the diagnosis of broncholithiasis as this patient had never expelled a calculus prior to his initial examination. The symptom complex was typical of stone asthma. In addition he experienced true bronchial colic in expelling the last broncholith. The etiology of the broncholithiasis was not determined, although both bronchoscopy and roentgenograms indicated that his calcifications were primarily of extrabronchial origin eroding into the bronchus.

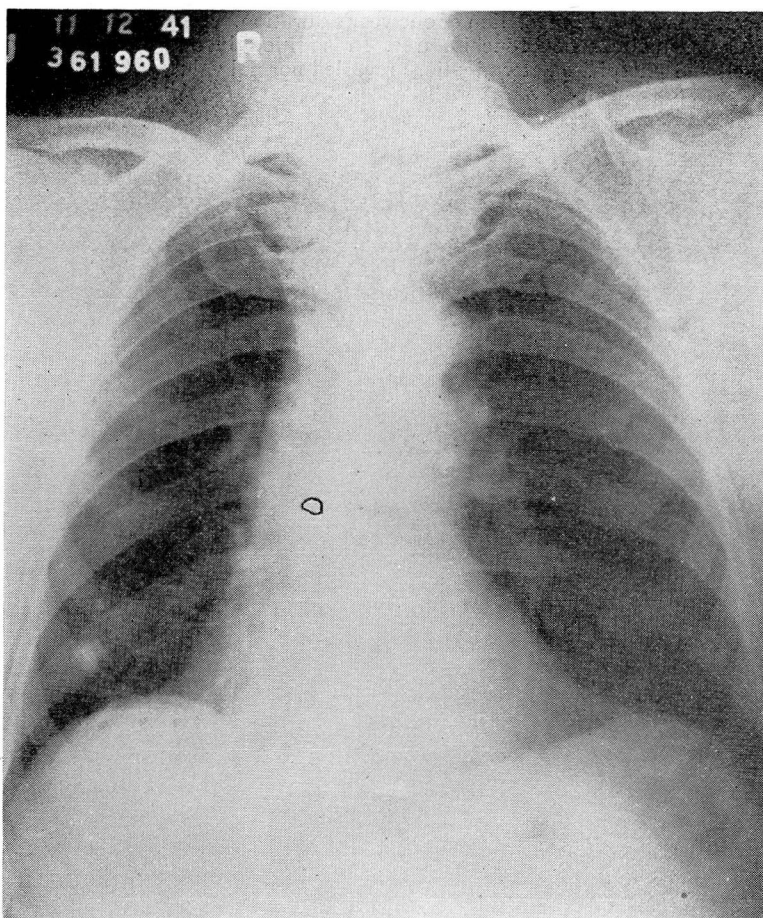


FIGURE 2: Later x-ray of Case 1 after part of bronchololiths have been removed bronchoscopically. Remaining stone expelled by patient.

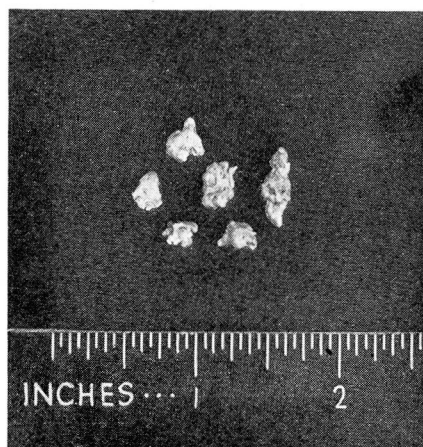


FIGURE 3: Bronchololiths of Case 1. Largest was expelled by patient. Others removed bronchoscopically.

BRONCHOLITHIASIS

Case 2. A 55 year old employee of an electric company came to the Clinic on July 11, 1941 presenting the symptoms of "recurrent attacks of flu" for the past four years. The attacks consisted of episodes of cough, productive of several ounces of purulent sputum, which were associated with chills and fever and lasted one to two weeks at intervals of every four to six months. In the previous six months, however, the attacks had occurred more frequently and had incapacitated him during the previous six weeks. He had lost 8 pounds in weight in the last six months.

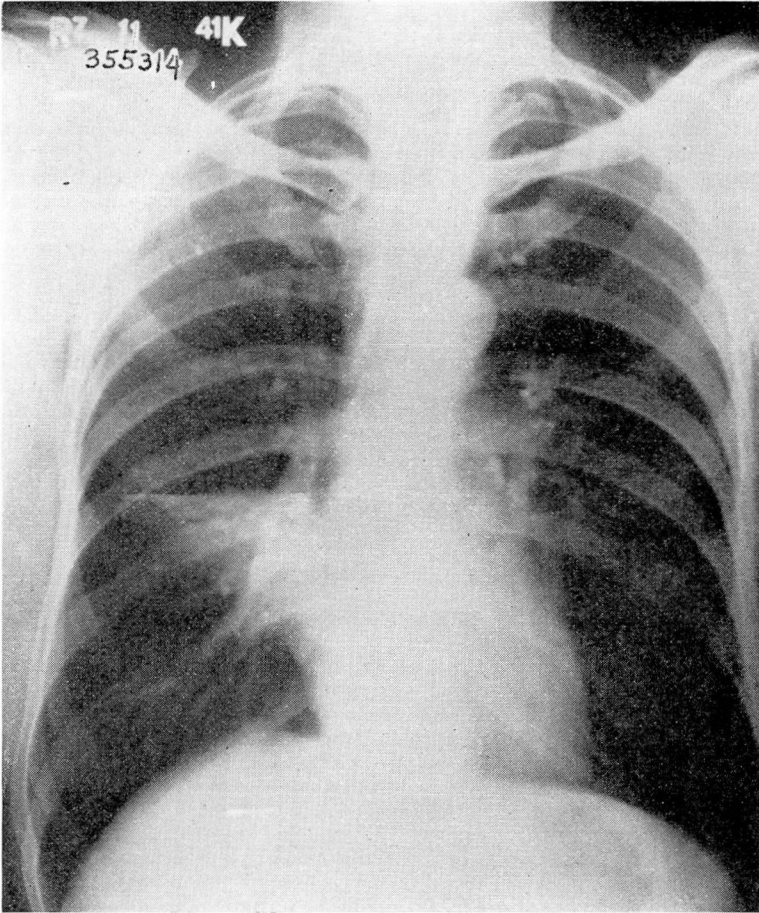


FIGURE 4: Preoperative x-ray of Case 2.

The only abnormalities were confined to the chest. Roentgen examination (Fig. 4) revealed partial atelectasis of the right middle lobe. At least one small abscess was discernible stereoroentgenographically in the area.

On the following day a bronchoscopic examination was carried out, and the right middle lobe bronchus was found to be constricted near its orifice to about $\frac{1}{4}$ its normal size. A thick grayish-yellow pus could be aspirated beyond the area of constriction. There was no ulceration nor other evidence of neoplasm. A biopsy was obtained from the mucosa in the right middle lobe bronchus in the area of stenosis. Microscopic study

of this biopsy showed only chronic non-specific inflammatory reaction with no evidence of neoplasm. Bacteriologic study on smear and culture of the bronchoscopically aspirated mucopurulent secretion revealed no pathogens. The patient entered the hospital on July 23, 1941 for further study relative to the etiology of his bronchostenosis (right middle lobe). On the following day bronchoscopy was repeated, and again nothing was found to account for the stenosed bronchus. However, immediately following manipulation in the area of stenosis, the patient developed a sudden severe pain in his right chest which proved to be due to pneumothorax. He gained no relief from morphine and was made comfortable only after 1800 cc. of air was aspirated into the chest wall. His convalescence from the complicating pneumothorax was uneventful.

As we were unable to determine the etiology of the bronchostenosis, and particularly as we were fearful of primary bronchogenic neoplasm, an exploratory thoracotomy was carried out on August 7, 1941. Dr. T. E. Jones made a transverse space between the third and fourth ribs extending from the right border of the sternum to the midaxillary line. The wound was spread with retractors without dividing the ribs. The right lower and right middle lobes were found collapsed, and the right upper lobe was densely adherent to the chest wall, especially anteriorly. Dense adhesions to the medial border of the right middle lobe of the pericardium were noted, and all adhesions were freed. There was no palpable evidence of neoplasm.

Because of the dense interlobar adhesions and the atelectasis of both the middle and lower lobes, total pneumonectomy seemed to be the wisest procedure. The superior and inferior pulmonary veins were doubly ligated and divided. The pulmonary artery was doubly ligated with double strands of black silk and divided. The main stem bronchus was clamped and divided, and the entire right lung delivered intact. The bronchus was closed with multiple interrupted sutures with No. 35 steel alloy wire. Three grams of prontosil powder was dusted in the pleural cavity. The third and fourth ribs were approximated with two heavy steel alloy sutures through drill holes. The pectoral muscles were approximated with figure of eight catgut sutures, the superficial fascia approximated with fine catgut sutures, and the skin closed with running dermal locked sutures.

The pathologic report on the surgical specimen is as follows: The gross specimen consisted of the right lung with three distinct lobes weighing 450 grams. Firm adhesions obliterated the upper half of the sinus between the upper and middle lobes. There were extensive fibrous adhesions over the lateral surface of the upper lobe with areas of plastic exudate upon the plural surface of the upper lobe and upon the base of the lower lobe. Examination of all the bronchioles going to the upper, middle, and lower lobes disclosed no neoplasm, and no tumor nodules were discovered in the lung. In the bronchus of the middle lobe was an area of incomplete stenosis through cicatrization in the wall of the bronchus. This occurred at the site of origin of one of the smaller bronchi passing through the upper portion of the middle lobe. External to the bronchus at this site was a hard calcified nodule about 1 cm. in diameter which might have been an old healed tubercle. The mucosal surface opposite the calcified nodule was irregular, granular, and appeared to be the site of an inflammatory process. The bronchiole for the upper portion of the lobe was almost completely occluded by this inflammatory tissue and cicatricial reaction. Slightly distal to this site in the fork of the smaller bifurcation was a small calcified nodule about 4 mm. in diameter apparently causing no stenosis. Several small subpleural calcified nodules were present in the middle and upper lobes. Impression was incomplete stenosis of the middle lobe bronchus probably incidental to calcified extrabronchial tubercles. Microscopic sections of the bronchiolar walls showed obsolete caseous tubercles in the peribronchial lymph node with erosion into the bronchiole and ulceration of the mucosa. There was considerable granulation tissue and acute inflammation of the mucosa and nodule. There was no histologic tuberculin, nor giant cells. Conclusion: Incomplete stenosis middle lobe bronchus, caseous and tuberculous peribronchial node with ulceration in the middle lobe bronchus.

The patient experienced a very uneventful postoperative convalescence. His temperature never rose more than $1\frac{1}{2}$ degrees at any time, and he was discharged on

BRONCHOLITHIASIS

the twenty-second postoperative day. His subsequent progress continues to be excellent, and he is well and symptom free. Fig. 5 demonstrates the last progress postoperative film, at which time the patient was symptom free, and his pneumonectomy uncomplicated by empyema.

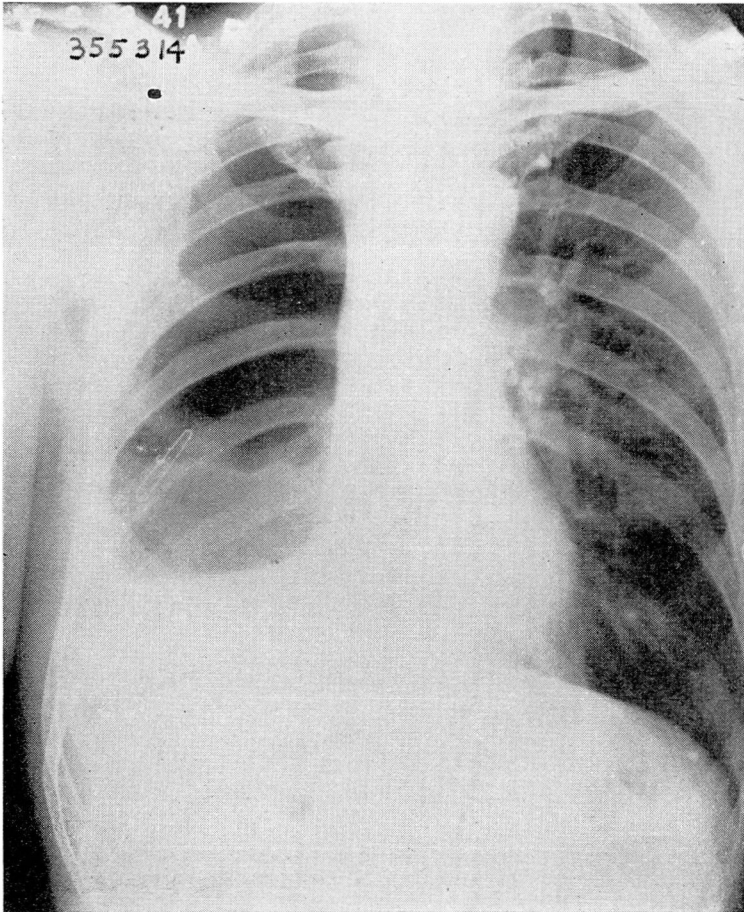


FIGURE 5: Postoperative x-ray of Case 2 (ten weeks later). Pneumonectomy for bronchostenosis secondary to broncholithiasis.

COMMENT

In this patient the broncholith was definitely of extrabronchial origin in the form of a partially calcified tuberculous gland with the complicating factor producing bronchostenosis and irreparable damage to the obstructed lung lobe beyond. This case also illustrated the com-

plication of pneumothorax in bronchoscopic manipulation in broncholithiasis. Although the diagnosis was not established until after surgery, this form of treatment proved to be the correct one.

SUMMARY

1. Broncholithiasis must be considered in the diagnosis of cases in which the history and findings suggest bronchial obstruction.
2. Bronchoscopy is essential for accurate diagnosis in these cases.
3. Broncholithiasis arises from calculous formations endobronchially or extrabronchially (with secondary erosion into the bronchus).
4. Two case reports illustrating the latter are presented; in one bronchoscopy was the method of diagnosis and treatment, and in the other lung surgery.

REFERENCES

1. Schenck, J.: As quoted by Poulalion; *Observ. Med.*, etc. Frankfort, 1600, I, 351.
2. Lloyd, J. J.: Broncholiths, with report of 4 cases. *Am. J. M. Sc.* 179:694-699, (May) 1930.
3. Wells, H. G.: Calcification and ossification. *Arch. Int. Med.*, 7:721-753, 1911.
4. Harbitz, F.: Extensive calcification of the lung as a distinct disease. *Arch. Int. Med.*, 21:139-146, 1918.