

## RADIODERMATITIS

### *Its Prevention as a Sequel to Roentgen Therapy for Certain Common Dermatoses*

GEO. H. CURTIS, M.D.

Every year we see a number of cases of radiodermatitis. It is depressing to inform an individual that the condition is permanent. Furthermore, we see the development and extension of carcinoma in radiodermatitis by growth and metastases, and the ingenuity of the dermatologist, surgeon, and roentgenologist is often taxed to destroy it. This results in more disfiguring scars and mutilations. Metastases are fatal. Not infrequently patients object to x-ray therapy even when they are convinced of its therapeutic efficacy because of the fear of sequelae.

Except, perhaps, in the treatment of cancer there is no legitimate excuse for radiodermatitis. In the treatment of non-cancerous dermatoses radiodermatitis is the result of mistakes in diagnosis, inadequate recording of previous x-ray therapy, allowing oneself to be persuaded by the patient or by the course of the eruption to excessive dosage, and failure to have the machines calibrated at regular intervals. Other reasons include failure to study the type of skin to be treated, and to recognize that x-ray therapy in many skin eruptions is not curative but palliative. Careful attention to these and other factors will reduce to an irreducible minimum the number of cases of sequela to roentgen irradiation.

Radiodermatitis as a sequela to modern irradiation technic may be said to be rare. A study of our records shows a ratio of less than two cases for 1000 admissions. The following table shows the distribution of radiodermatitis from roentgen therapy in 69 consecutive cases.

<i>No. of Cases of Radiodermatitis</i>	<i>Disease Treated</i>
8	Pruritus of vulva, anus, and scrotum
5	Acne vulgaris
5	Eczema of the hands
4	Keratosis (senile, seborrheic), moles
4	Verruca of palms and soles
3	Psoriasis
2	Epidermophytosis
2	Removal of hair
2	Atopic dermatitis
1	Lichen planus
1	Localized neurodermatitis
1	Lupus vulgaris
1	Tinea sycosis
*15	Radiodermatitis in doctors, dentists, and experimental workers
15	Miscellaneous (thyroid disease, carcinoma breast, sarcoma, hydrarthrosis, rheumatism, uterine tumors)

\*Radiodermatitis in these cases was incurred in the course of professional work.

I shall not attempt to draw any far-reaching conclusions from the meager data derived from a study of the cases; however, certain facts stand out. Approximately one-fourth of the cases occurred in physicians, dentists, and experimental workers in radiology. Two physicians had been affected during the early days of roentgenology. One individual had been burned in the course of experimentation with roentgen rays and radium emanations. The remaining ten physicians had acquired the dermatosis through faulty fluoroscopic technic. Four of the dentists had been affected by holding dental films in patients' mouths during the exposure.

Of the 39 cases in which roentgen therapy had been administered for cutaneous disease, one case of acne vulgaris had been treated by an advertent skin clinic, and two cases of removal of hair by a nonmedical organization. The remainder of the cases had been treated by physicians who had given either a few large doses or too many small doses. The small doses had been given at short intervals over a long period of time up to one to two years. The untoward effects usually had not developed for one to three years after the course of treatment. This is the trap into which any physician may fall because the cumulative biologic effect of small doses is slow, and radiodermatitis is of late development. In the other cases in which a small number of treatments had been given, the dosages evidently had been large as the histories indicated irradiation reactions. Instead of permanently discontinuing treatment after a reaction, one or more additional treatments had been administered. The usual result had been a severe dermatitis which took weeks to subside.

It is of interest to note that the greatest number of cases of radiodermatitis occur in those dermatoses for which roentgen therapy is usually only palliative, or in which the amount of irradiation necessary to cure is dangerously close to that which causes radiodermatitis. In all the cases of pruritus of the vulva, anus and scrotum, eczema of the hands, verrucae, psoriasis, atopic dermatitis, and lichen planus not only was the disease not cured, but radiodermatitis also was added to it. The cases of keratoses, moles, removal of hair, lupus vulgaris, and tinea sycosis were cured, but radiodermatitis resulted. Carcinoma developed in the case of lupus vulgaris and in two cases of psoriasis. In some of the cases, both cured and uncured, painful non-healing ulcers added to the patient's discomfort.

#### CASE REPORTS

The following case reports are representative of those in the foregoing table. A discussion is included of the amount of roentgen therapy which may be given with impunity, its efficacy, and of other successful methods of treatment.

## RADIODERMATITIS

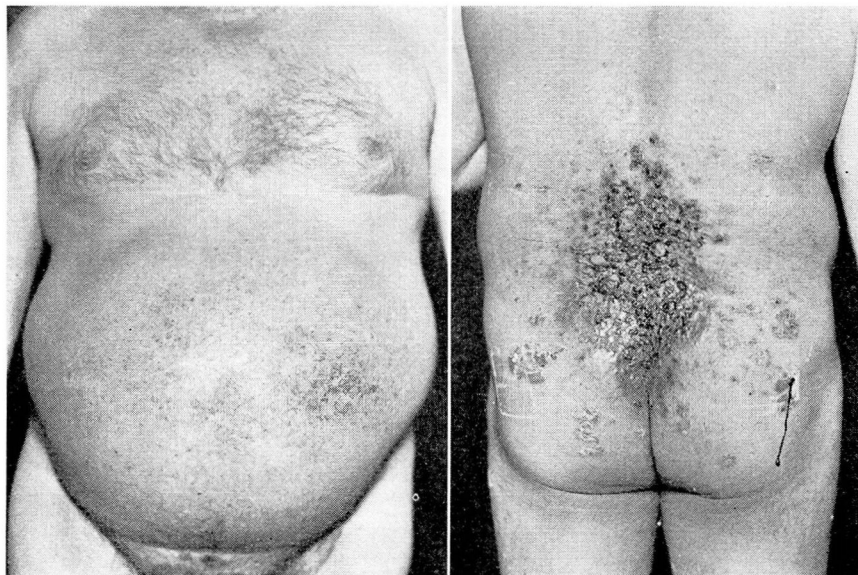### *Case 1. Cirrhosis of Liver, Psoriasis, and Radiodermatitis with Ulceration.*

An Italian, aged 52, came to the Clinic on August 15, 1941 complaining of an eruption on his body of five years' duration. Early in the course of the disease the eruption had disappeared following fever therapy, but had recurred about two years ago. Since then he had had generalized "light" treatments, and he estimated that he had had a treatment twice a week for a year. About two months ago a large area on his back had become ulcerated.

Six months ago he had noticed swelling of his abdomen. In the past few months he had had a pressure sensation in his chest and dyspnea on exertion. Other symptoms had been indigestion and anorexia. He had been a heavy drinker since the age of 16.

The physical examination showed ascites, caput medusa, enlarged heart, edema of the legs, and varicose veins. Typical plaques, nummular and guttate lesions of psoriasis were disseminated over the cutaneous surface, with the exception of the scalp, face, hands, and feet. The anterior surface of the trunk, thighs, and legs showed large areas of telangiectasia, atrophy, scaling, and deep fibrosis of the dermis. The entire lumbar and sacral regions, the buttocks and posterior surfaces of the thighs showed similar changes. In the midpart of the lumbosacral region was a large area of ulceration with fungating tumor masses of granulation tissue varying from pea to walnut size.

A macrocytosis and 20 per cent bromsulfalein test confirmed the diagnosis of cirrhosis of the liver. The dermatosis was typical of psoriasis, and the telangiectasia, atrophy, fibrosis, and ulceration were typical of radiodermatitis. Unfortunately, the patient's physical condition prohibited excision and subsequent skin grafting of the ulcerated area.



### LEGENDS

FIGURE 1. A. Chronic radiodermatitis with telangiectasis, atrophy, keratosis, and fibrosis. Case 1.

B. Radiodermatitis with deep ulcerative vegetation. Note psoriatic plaques at the periphery.

COMMENT

Roentgen therapy, in spite of the danger of radiodermatitis, is one of the best therapeutic methods in the treatment of psoriasis. It is clean, simple of administration, and frequently causes complete disappearance of lesions. Not uncommonly, however, in resistant cases the lesions are refractory to x-rays, and in spite of continued irradiation the old lesions persist and new lesions appear. The usual and safe scheme of treatment consists of 75 r of low voltage and unfiltered irradiation at weekly intervals for six to ten treatments. In generalized irradiation overlapping of the fields of exposure should be avoided. If the eruption does not respond to this amount of treatment, it may be classified as resistant, and further irradiation usually is valueless. With good judgment and a careful recording of the cutaneous areas treated, recurrent eruptions may be treated as long as the lesions respond to short courses of a few treatments if the recurrences are several months apart or in areas not previously treated. In my opinion sixteen to twenty treatments should be the maximum in such cases. Ordinarily when this amount of treatment is reached, it will be found that the recurrences have failed to respond favorably.

Keratolytics such as salicylic acid, chrysarobin, anthrolin, neorobin, tar, and pyragallol should not be used for at least one or two weeks before and after roentgen therapy.

*Case 2. Chronic Recurrent Eczematoid Dermatitis of the Hands. Acute Radiodermatitis and Contact Dermatitis.*

A white woman, aged 25, came to the Clinic on October 9, 1939, presenting swollen hands and a painful dermatitis extending almost to the elbows. Since childhood she had had a recurrent, vesicular and itching dermatitis on the hands. Following an x-ray treatment in July, 1939 her hands had become swollen, red and painful. Another treatment in September, 1939 had been followed by marked redness, swelling, and pain. An ointment had been prescribed, and a few days later an acute, itching dermatitis had appeared, extending to the elbows.

On examination the hands were found to be swollen and red with small ulcerations, and an acute vesicular pruritic dermatitis extended over the forearms to the elbows. A secondary pyoderma was also present.

After several weeks of treatment with potassium permanganate soaks, soothing lotions and ointments the acute symptoms subsided. Patch tests with the incriminated ointment and its chief ingredients, benzocaine and picric acid, were positive.

Three months later early signs of chronic radiodermatitis with dryness, scaling, pigmentation, and slight telangiectasia were apparent. A year later atrophy, keratoses, and telangiectasia on the dorsa of the hands and the palms were plainly evident, in addition to nummular patches of vesicular eczematoid dermatitis.

COMMENT

Information was obtained that a total of 5,270 r with copper and aluminum filtration had been administered in 1935, 1936, 1937, 1938 and 1939. By rough calculation, the total irradiation had been approxi-

## RADIODERMATITIS

mately 9700 r for back scattering and exposure of palms and dorsa of hands separately. Obviously, this amount of irradiation had been sufficient to cause radiodermatitis. The acute symptoms had not appeared until after the last two treatments of 210 r each two months apart, thus demonstrating the cumulative effect of roentgen rays. These two treatments with  $\frac{1}{2}$  copper filter had not been sufficient in themselves to cause symptoms.

The superimposed contact dermatitis and secondary pyoderma complicated the acute symptoms of the radiodermatitis. The former dermatoses subsided in about ten days, and the underlying edema, ulceration, and erythema of the latter were revealed, which did not begin to subside until several weeks later.

### COMMENT

In many cases of eczematous dermatitis on the hands and/or feet the eruption may be classified as a contact dermatitis, an eczematoid dermatitis from primary irritants and physical agents, a nummular eczema, an atopic dermatitis, a dermatomycid, or a cheiopompholyx, and appropriate therapy may include a minimum amount of roentgen irradiation<sup>1</sup>. Nummular eczema and cheiopompholyx are among the eczematoid eruptions of unknown cause, and recurrences are common. Roentgen therapy in these conditions is dangerous, as it is merely palliative and the limit of safety is rapidly exceeded. If after a thorough investigation the cause of the dermatitis is not found and roentgen therapy is necessary for relief, three to eight treatments of 75 r each of low voltage, unfiltered irradiation at weekly intervals may be administered. If this amount does not produce a favorable result, irradiation is discontinued. It is my practice to stop treatment of recurrences for several years at least when a total of 1200 r has been administered.

#### *Case 3. Radiodermatitis and Carcinoma Following Treatment of Lupus Vulgaris.*

A Scotsman, aged 38, came to the Clinic on January 25, 1938 presenting a growth on the right cheek. During infancy and up to the age of 15 he had been treated with x-rays for lupus vulgaris. In later years radiodermatitis had developed on the face and neck. Four years ago a small nodule had appeared in the area of healed lupus scars and radiodermatitis near the right commissure of the mouth. By simultaneous extension and cicatrization the lesion had migrated toward the ear.

The general physical and laboratory examinations including roentgenograms of the chest were normal.

Both sides of the face and neck showed extensive scarring and radiodermatitis. A number of keratoses were disseminated over the affected areas. On the right side of the face, extending from the commissure of the mouth to the ear, was a band-like scar, and at its upper pole was an elevated tumor mass which was the size of a half dollar and was crusted and bled easily. Along the scar were smaller, crusted, less-elevated nodular lesions. There was no regional adenopathy. Histologic examination of a small piece of the tissue showed squamous cell carcinoma.

From January, 1938 to July, 1939 the lesion was given a total of 1150 millicurie hours of radium. In October, 1940 a recurrence was noted. In September, 1941 the



ulcerated recurrence was excised, and a Thiersch graft applied. The patient is still under observation, and there is no evidence of recurrence of the carcinoma.

#### COMMENT

Lupus vulgaris was one of the first skin diseases to be treated with x-rays. Early reports gave a high percentage of cures because early workers did not hesitate to produce severe reactions. Later, when serious sequelae of radiodermatitis made their appearance, x-ray therapy became more conservative, and the percentage of cures decreased. In the United States x-ray therapy has been largely superseded by other methods, including excision of small plaques, electrocoagulation, cold quartz ultraviolet irradiation (Kromayer lamp), and salt-free diets. Kile<sup>2</sup> has recently described a method of injecting a starch solution into the lesions. This method has shown some promising results and deserves further trial.

When the decision to use roentgen therapy is reached MacKee<sup>3</sup> advises routine administration of 225 r unfiltered every four weeks for three or four treatments. In children 150 r is the usual dose. The remaining nodules may be destroyed by other methods.

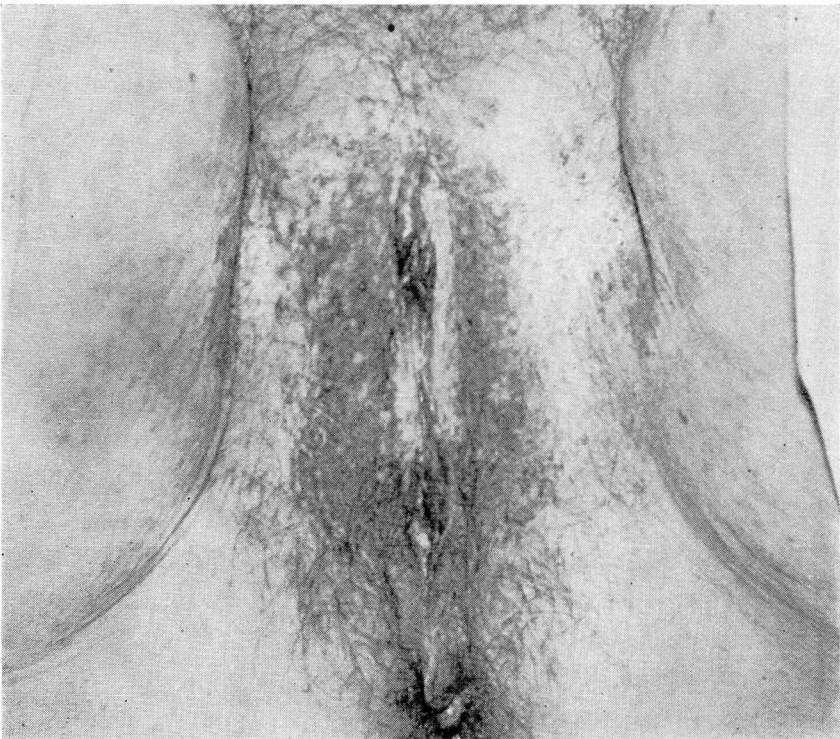


FIGURE 2. Radiodermatitis following roentgen therapy for pruritus vulvae. Case 4.

## RADIODERMATITIS

### *Case 4. Pruritus Vulvae and Radiodermatitis.*

A secretary, aged 36, came to the Clinic on September 21, 1936, complaining of pruritus of the vulva which she had had for six years. There had been periods of remission for a few months at a time. She had had 31 x-ray treatments, each being one-third skin unit, given at intervals of two to four weeks for two years. The last treatment had been in 1934. She had first noticed a developing telangiectasia on the vulva in 1935.

Examination showed telangiectasia, atrophy, and keratoses of the vulva and the medial surfaces of the thighs. In addition the vaginal mucosa was inflamed, and a frothy discharge was present. A specimen of the discharge contained numerous trichomonas vaginalis organisms.

The trichomonas infection was cured, and the pruritus was treated by an hydrochloric acid injection. This relieved the pruritus, and the patient was lost from observation.

### COMMENT

A thorough investigation should be made to find the various organic and neurotic causes of pruritus of the vulva and anus. Topical soothing and antipruritic measures including a minimum of roentgen irradiation may be used during the course of study. If 75 r of low voltage unfiltered irradiation once weekly for six to ten treatments is not sufficient to stop the pruritus, x-ray therapy should be stopped. Recurrences are most troublesome and lead to excessive irritation and radiodermatitis. If combined etiologic and dermatologic management including roentgen therapy fails to cure the pruritus, it is then necessary to resort to alcohol injections, which may be repeated one or more times. I have had no experience with the tattoo method<sup>4</sup> for pruritus ani, although the literature indicates promising results.

### *Case 5. Epidermophytosis of the Feet and Radiodermatitis with Ulceration.*

A white woman, aged 33, came to the Clinic on crutches on August 14, 1941, complaining of severe pain and ulceration of her right foot. In May, 1940 a vesicular eruption had appeared on the sole, had been diagnosed as ringworm, and five x-ray treatments had been administered as follows: three treatments in May, one in July, and one in August. Several days after the last treatment the foot had begun to turn red and to swell. Later blisters and ulcerations had appeared. The acute symptoms had begun to subside after about five weeks. From time to time during the following year painful ulcerations would occur and heal. The patient had been using crutches since the acute dermatitis had subsided.

On examination the right ankle and foot were found to be swollen. The margins of the foot showed telangiectasia which extended to an area of keratosis, ulceration, scarring, and fibrosis involving the arch and heel. The keratoses were islands of piled-up wart-like epithelium. The ball of the foot and toes were free of dermatitis.

The patient was admitted to the hospital, the affected area excised, and a skin graft applied. The graft was successful, but she has not yet been permitted to walk without crutches.

### COMMENT

If this case had been diagnosed as one of epidermophytosis and the diagnosis confirmed by microscopic examination of vesicle roots and scales for fungi, the fungous infection could in all probability have been cured without roentgen irradiation. Dermatologists resort to roentgen

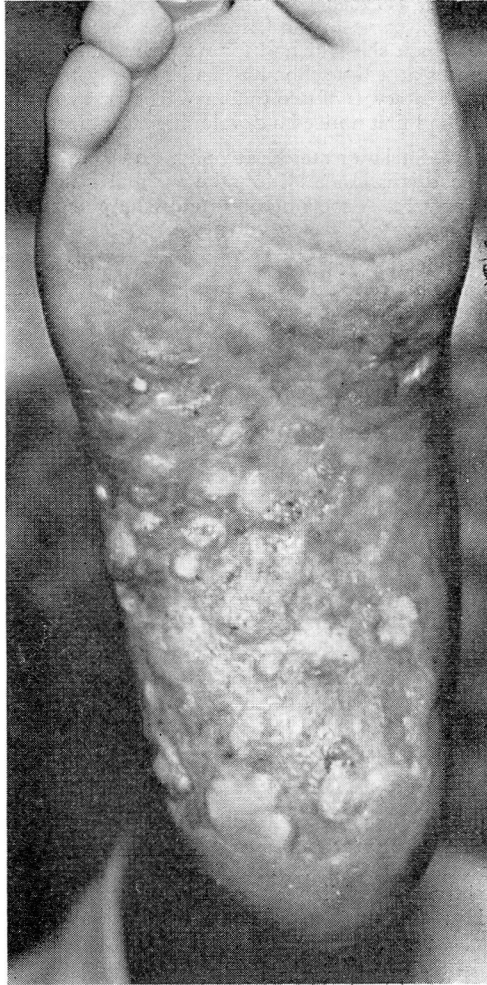

FIGURE 3. Radiodermatitis of sole following roentgen therapy for epidermophytosis. Case 5.

therapy when the dermatophytosis is obstinate or hyperkeratotic. Roentgen rays do not kill fungi, but are used for their stimulating and healing effect on tissues. Consequently, seldom more than 6-10 treatments of 75 r each at weekly intervals is necessary.

The amount of irradiation could not be determined from the history, but it must have been in large doses since four treatments of 75 r or even 100 r each would not have produced an acute radiodermatitis. The epidermophytosis was cured.



## RADIODERMATITIS

### *Case 6. Verruca Plantaris and Radiodermatitis with Ulceration.*

A married woman, aged 30, came to the Clinic on May 23, 1941, complaining of an ulcer on the ball of the right foot of nine weeks' duration. A diagnosis of verruca plantaris had been made, and the lesion had been treated with five x-ray treatments one week apart. The sixth treatment, as the patient's physician had told her, had been equal to the total amount of the previous five doses. It had been given in the sixth week. Two weeks later a seventh treatment with the same dose as the sixth treatment had been given. After about three weeks the treated area had become red, swollen, and painful. A scab had formed and upon removing it, a large deep hole filled with fluid had been exposed. During the succeeding nine weeks the ulcer had failed to heal.

On examination an ulcer 1 cm. in diameter was seen directly overlying the first metatarsophalangeal joint and was located in the center of a red, swollen, edematous area which included several toes and extended to the middle of the arch of the foot. The entire area was painful, and the lesion had a foul odor. A wart was present at the base of the great toe distal to the rim of the ulcer.

The patient was instructed as to local treatment with potassium permanganate soaks and soothing ointments. Four months later, after the swelling and inflammation subsided, the ulcer and surrounding tissue showing early chronic radiodermatitis was excised, and the area skin-grafted.

### COMMENT

Warts are capricious. There is no clinical sign which will indicate whether or not a wart will be amenable to x-ray therapy, but in many instances the minimal therapeutic dose administered by dermatologists is sufficient to cure. The technic is important. The wart should be carefully trimmed, and the normal skin should be well screened with lead and red rubber. Lead shields, 2 mm. thick, 3 by 5 inches in size, in the center of which round holes are punched varying from 3 to 15 mm. in diameter are used to isolate the wart from the normal skin.

The routine dosage as given by MacKee is used. The dose varies from 300 to 1200 r depending on the size of the wart. Larger doses of 600 to 1200 r are given to small warts with thick hyperkeratoses or to larger warts which are deep with thick hyperkeratoses. If a 300 r dose is given and if at the end of four weeks there is no response to treatment, another treatment is given. If larger doses (600 to 1200 r) are given, the interval between treatments is up to three months. If a second treatment does not effect a cure, other methods must be tried.

Contact x-ray therapy seems to be rapidly coming into the fore in the treatment of verrucae. With this low voltage (40 to 50 KV), a large amount of beta rays (2000 to 4000 r) is concentrated within the substance of the wart itself and is without sequelae, except that the early reaction may be slightly more severe with large doses than that which follows x-ray therapy. This reaction subsides without subsequent radiodermatitis. This method is especially useful when there are numerous plantar or palmar warts. A dozen warts may be treated in much less time than it takes to treat one wart by x-ray and because of the size and shape of the instrument, no lead shields need be used, nor is the

tedious procedure of punching holes in lead foil to fit over the warts necessary. Contact x-ray is also valuable in the treatment of small carcinomas, senile keratoses, hemangiomas, small keloids, and pre-cancerous dermatoses.

#### DISCUSSION

Radiologists and dermatologists disagree somewhat about the practical application of roentgen therapy. The radiologist tends to use higher voltages, greater filtration, larger doses, and shorter intervals between

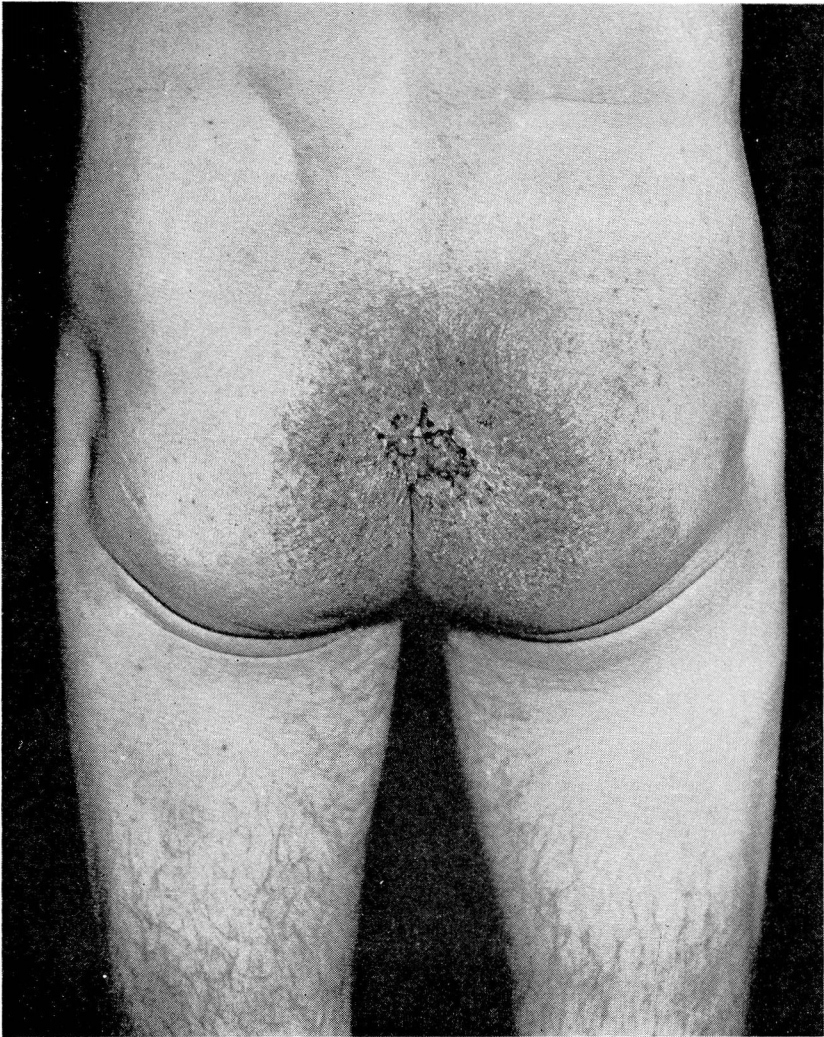


FIGURE 4. Radiodermatitis with ulceration following roentgen therapy for pruritus ani.

treatments; whereas, dermatologists employ lower voltages, little or no filtration, smaller doses, and longer intervals between treatments. Important requirements in the use of either method are (1) that the physician use a calibrated machine; (2) that he have wide experience in the diagnosis and treatment of skin diseases, and (3) that he know the limits of safety of the particular method used to avoid radiodermatitis, since the object of roentgen therapy is to ameliorate or cure cutaneous affections without leaving irradiation sequelae.

The modern, well-trained dermatologist uses great discrimination in the treatment of various dermatoses with roentgen therapy, as it is only one of the many therapeutic methods in his armamentarium. Irradiation is employed when, after careful consideration, it is the treatment of choice at a particular time in the course of the dermatosis. For example, in generalized psoriasis much of the eruption may be made to disappear by topical treatment; however, when a few of the more resistant lesions remain, they may be cleared up by a few roentgen ray treatments (of 75 r each). In recurrences this method may be used a number of times, and at the same time the amount of irradiation is held within safe limits.

Forcing the issue with irradiation therapy by increasing the number and/or size of the doses or by shortening the interval between treatments is likely to have serious results. Repeated recurrences or increasing resistance of an eruption to irradiation are common causes. If a small number of treatments fail to cause a psoriatic or a plaque of circumscribed neurodermatitis to disappear, irradiation should be discontinued for several months. A repeat course may then cause it to clear up.

The variation in susceptibility of various parts of the cutaneous surface is important in determining the amount of irradiation to be used. The face is the most sensitive part. Therefore, during the course of treatment of acne vulgaris, rosacea and the like, the skin should be carefully scrutinized for evidences of irritability, such as increased reactivity to heat, light, friction, emotional excitement, and also dryness and fine wrinkling, etc. The tendency of keratolytics to increase irritability adds to the x-ray effect. The flexures are very sensitive, and the thin skin over the external surfaces of the joints are more sensitive than that in the immediate vicinity. The scalp, palms, and soles are the least sensitive parts. The mucous membranes are more sensitive than any region of the cutaneous surface.

Hyperemia and congestion, as well as inflammation produced by topical medication (counterirritants, ultraviolet irradiation, etc.), may heighten the biologic effect of x-rays more than is anticipated. Thus, roentgen therapy to sensitive areas with these superimposed factors may result in an unexpected radiodermatitis.

The location, extent, depth, and nature of the pathologic process are the deciding factors in the quality and quantity of irradiation to be administered. In the foregoing list of dermatoses the process is superficial. The range of depth varies from the epidermis and papillae (eczematous and eczematoid dermatoses) to the level of the sweat glands (lupus vulgaris). Consequently, in these dermatoses (and other superficially located dermatoses as well) the object is to deliver to the affected depths as many r as possible without affecting the more deeply situated important structures. From the dermatologist's viewpoint low voltage (80 to 100 KV) unfiltered roentgen therapy serves this purpose. According to Cipollaro<sup>5</sup>, at the level of the sebaceous glands (about 1 mm.) 22 per cent of unfiltered irradiation at 40 KV peak and 16 per cent at 100 KV peak is absorbed, while only 8 per cent at 140 KV with 3 mm. Al filter is absorbed. Thus, of a 75 r dose at 80 KV unfiltered irradiation, 13.5 r is absorbed in the first millimeter of skin, while of 75 r at 140 KV with 3 mm. Al filter, only 4.5 r is absorbed. At 3 mm. depth (level of hair bulb) 30 r of a 75 r dose at 80 KV unfiltered irradiation is absorbed, while only 10.5 r of the same dose at 140 KV 3 mm. Al is absorbed. Consequently, larger doses of high voltage filtered irradiation at shorter intervals are necessary for the absorption of the same quantity as that of low voltage irradiation at the same level to obtain the same biologic effect. Furthermore, larger doses of filtered high voltage irradiation at shorter intervals unnecessarily affect the deeper structures. On the other hand, the erythema dose of low voltage unfiltered roentgen rays is 300 to 350 r; whereas, it is up to 700 r for high voltage heavily filtered irradiation. This influences the dermatologist to be exact in his judgment, technic, and the diagnosis; but since a larger number of r is absorbed from a smaller dose of low voltage unfiltered irradiation in the upper layers of the skin where the pathologic process is located, he is able to give smaller doses at longer intervals and to follow the biologic effect on the *skin* during the course of treatment.

#### SUMMARY

This article is limited to a brief discussion of the principal factors in the etiology of radiodermatitis from roentgen therapy in 69 cases. Of the 69 cases 39 were the result of treatment of superficial dermatoses; 15 cases occurred among physicians, dentists, and experimentalists; and 15 cases were the result of treatment of cancer, sarcoma, thyroid disease, etc. The cases of radiodermatitis in the treatment of cancer, sarcoma, etc. have not been discussed.

Five case reports of representative superficial dermatoses with superimposed radiodermatitis selected from the list of 39 cases are given in addition to a brief description of an accepted method of administering a safe total dose of superficial low voltage unfiltered roentgen therapy.



## RADIODERMATITIS

Radiodermatitis may be prevented in the treatment of superficial skin diseases either by the method of high voltage, filtered irradiation or by low voltage, unfiltered and superficial irradiation if three principles are fulfilled: (1) calibration of machines, (2) a wide experience in the diagnosis and treatment of skin diseases, and (3) a knowledge of the limits of safety of the method used. Other minor factors discussed are (1) the failure to record previous roentgen therapy; (2) the failure to study the color and type of skin treatment and variations in sensitivity of different regions of the cutaneous surface; (3) the necessity for a thorough knowledge of the characteristics and course of the particular dermatosis under treatment; (4) avoiding the use of keratolytics during roentgen therapy; and (5) avoiding the trap of "forcing the issue" in the treatment by the physician allowing himself to be persuaded to give excessive treatment either by the course of the eruption or by the patient.

## REFERENCES

1. Curtis, G. H.: Allergy in Clinical Practice. Philadelphia: The J. B. Lippincott Co. 1941, Chapters 7, 8, 10.
2. Kile, R. L.: Treatment of lupus vulgaris by injections of starch U. S. P. (cornstarch). Arch. Derm. and Syph. 39:471-473, (March) 1939.
3. MacKee, G. M.: X-rays and Radium in the Treatment of Skin Diseases. 3rd ed. Philadelphia: Lee and Febiger, 1938, pg. 613.
4. Turell, R., Buda, A. M., and Marino, A. W. M.: Treatment of pruritus ani by tattooing with mercury sulfide. Arch. Derm. and Syph. 41:521-526, (March) 1940.
5. Cipollaro, A. C.: Irradiation dermatology. Radiology. 36:684-693, (June) 1941.