

TRANSPOSITION OF THE ANUS

Report of a Case

WM. E. LOWER, M.D.

The case which is herewith reported was that of a girl, aged $4\frac{1}{2}$, who was first seen in September, 1939 with a chief complaint of congenital absence of the rectal opening in the perineum; however, she had an opening into the vagina (Fig. 1) which in appearance was not unlike a normal anus. The only repair had been a slight enlargement of the opening into the vagina to permit freer bowel movements.

The patient had an almost constant fecal drainage unless she was constipated; then she had formed stools. There was no history of bladder difficulty nor nocturia, although there had been some frequency;

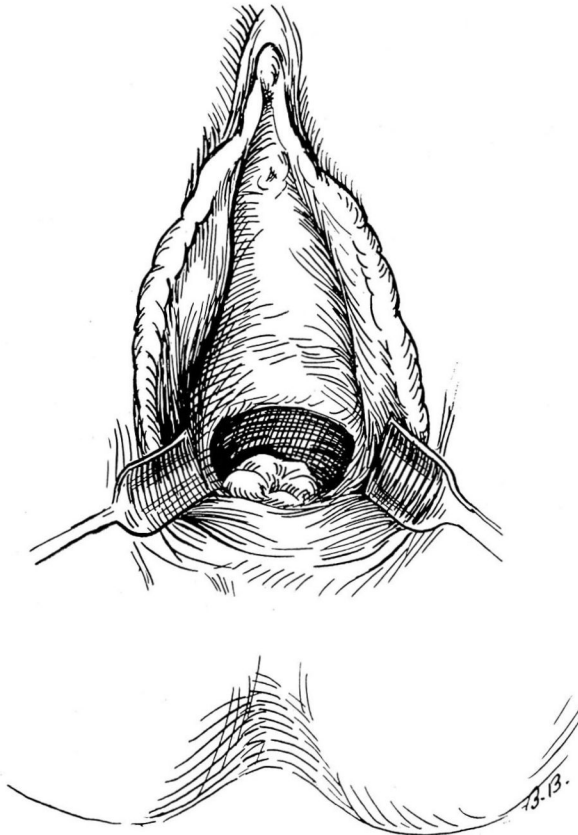


FIGURE 1. Diagram showing the opening in the vagina.

TRANSPOSITION OF THE ANUS

and the child had good bladder control. Some voluntary control of bowel movements also had been observed.

In June, 1941 the patient was admitted to the Cleveland Clinic Hospital for operation. Under general anesthesia a loop sigmoid

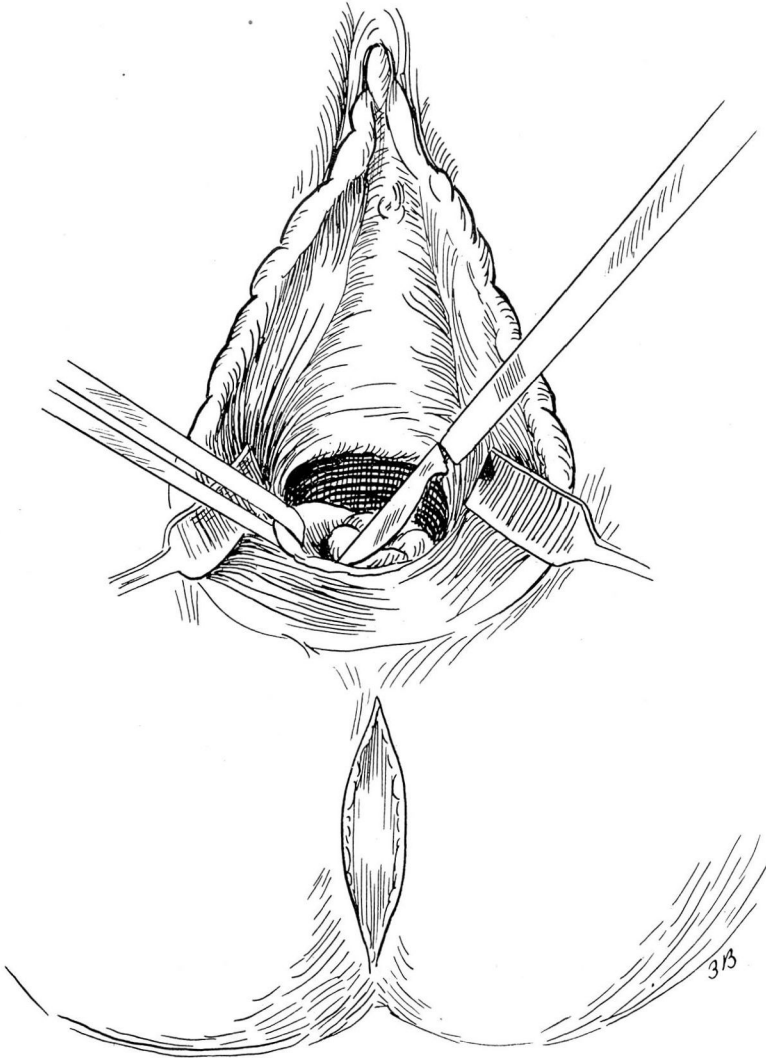


FIGURE 2. Separation of the opening in the vagina and the perineal incision.

colostomy was performed, after which the lower bowel was thoroughly cleansed. When the colostomy was functioning well, an opening was made in the perineum, and the opening in the vagina dissected free

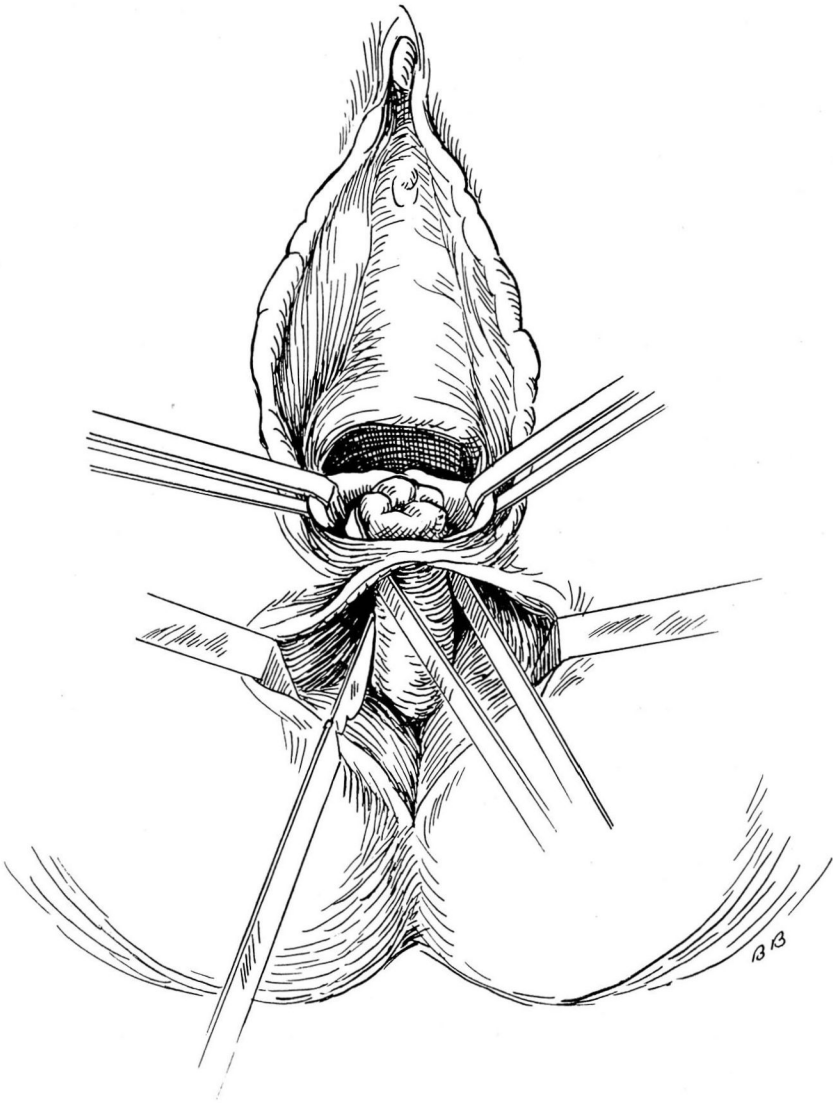


FIGURE 3. Freeing the opening into the vagina.

(Figs. 2 and 3). With a long forceps this part of the gut was transposed to the new opening in the perineum (Fig. 4). The transposed opening was then sutured to the skin and perineal tissue. A perineorrhaphy was performed which obliterated the newly made opening in the vagina (Fig. 5). The child's mother was instructed in the dilatation of the anus

TRANSPPOSITION OF THE ANUS

every other day, and the child was sent home to return later for closure of the colostomy.

In September, 1941 the patient was readmitted to the hospital, and Dr. T. E. Jones closed the colostomy. Examination of the rectum re-

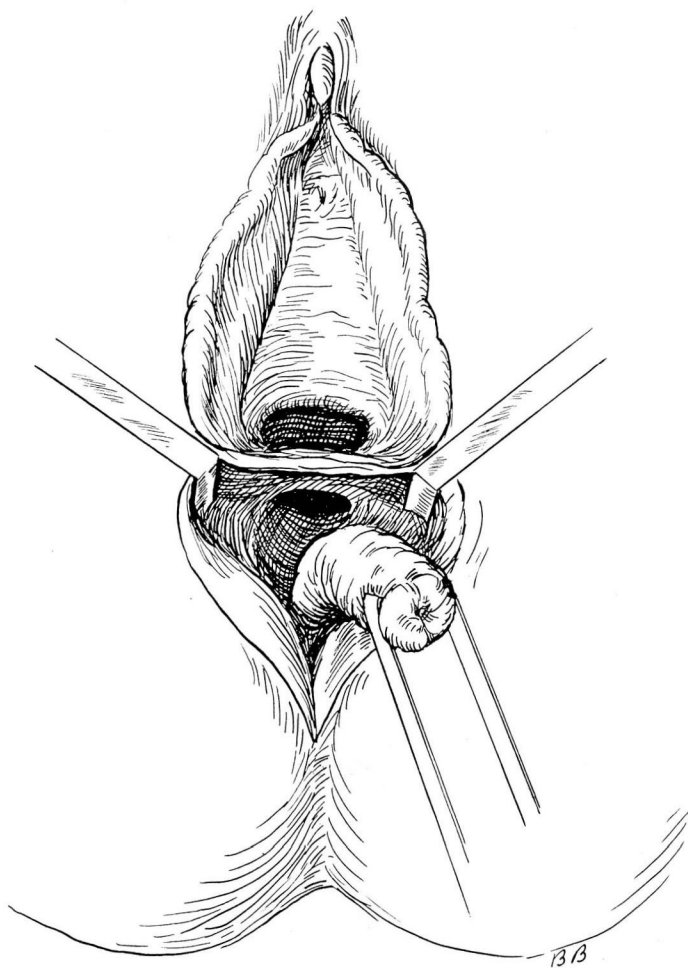


FIGURE 4. Replacing the gut into the perineum.

vealed a tight fibrous anus, and the smallest Young dilator was inserted into the rectum and left in place. After a two weeks period of hospitalization, the patient was discharged to return for closure of the colostomy when the function of the anus was adequate.

The patient was readmitted in October, 1941, and the colostomy closed. Upon discharge from the hospital, the patient was having normal evacuation and peristalsis, and her condition was good.

SUMMARY

The case herewith reported probably would be classified with the cases of congenital rectovaginal fistula, but in this instance the opening was at the end of the rectum and seemed to give the appearance of a transposed anus rather than that of a fistula from the rectum. The

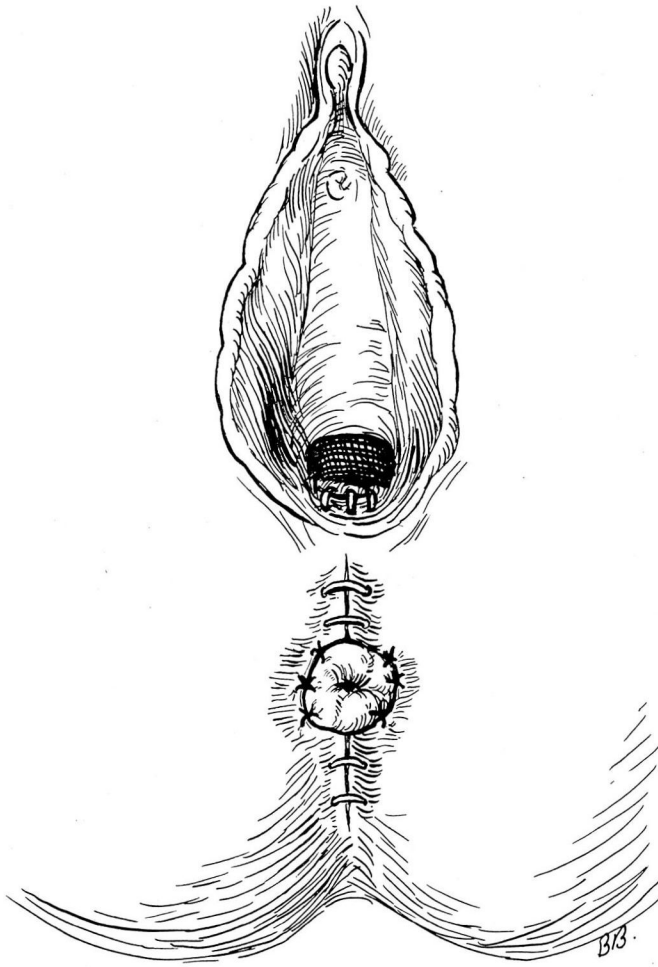


FIGURE 5. The completed operation.

TRANSPOSITION OF THE ANUS

opening in the vagina was just inside the margin of the vagina. The sphincter was not very efficient, and anal incontinence was one of the symptoms. The treatment consisted in making an opening in the perineum and transposing the opening which was in the vagina to the location in the perineum corresponding to that of a normal anus. In this way the gut was not cut, but the opening dissected free from the vagina and transferred to the perineum, thus obviating the necessity for closing the original opening and establishing a second opening which would be more liable to contraction and stricture.