

TABLE OF CONTENTS

FROM THE EDITOR

Balancing the myths of corticosteroid therapy 480

No class of drug has more mythical attributes, interfaces with different medical specialties, or clinical street lore than corticosteroids.

Brian F. Mandell, MD, PhD

THE CLINICAL PICTURE

Widespread skin-thickening and hyperpigmentation 485

A 37-year-old military veteran presented with extensive velvety hyperpigmented plaques over nearly 15% of the total body surface.

India K. Poetzsch; Nikolai Klebanov, MD; Shinjita Das, MD, MPH

THE CLINICAL PICTURE

Phenytoin-induced gingival overgrowth 488

A young man presented with lower-extremity weakness and slurred speech. He has been on seizure prophylaxis after experiencing a seizure following hemispherectomy for subdural hematoma.

Mitesh Karn; Ranjan Sah; Shabal Sapkota, MD

THE CLINICAL PICTURE

Mucinous ascites: Pseudomyxoma peritonei 491

A 59-year-old man presented with progressive abdominal distention that limited daily activities and oral intake. The ascitic fluid was markedly viscous and jelly-like.

Sansrita Nepal, MD; Adam Schwertner, MD; John M. Cunningham, MD

THE CLINICAL PICTURE

Nasal herpes simplex virus infection 495

Skin changes on the nose in a 37-year-old patient that began after a scratch were concerning for extensive nasal skin necrosis.

Nina L. Tamashunas, MD; Robert Simonds, MD; Sarah Young, MD

CONTINUED ON PAGE 479

Upcoming Features

- Reducing breast-cancer risk: The role of chemoprevention
- Benign paroxysmal positional vertigo: Effective diagnosis and treatment



CONTINUED FROM PAGE 477

THE CLINICAL PICTURE

Hyperpigmentation as a clue to Addison disease 498

The 66-year-old woman presented with fatigue, loss of appetite, and hyperpigmentation of the tongue, soft palate, buccal mucosa, lower lip, fingers, and nail beds.

Yusuke Hirota, MD, PhD; Takaya Matsushita, MD, PhD

COMMENTARY

Diversifying medical humanities: The case for Jay-Z 501

Physicians carry considerable power in the patient-physician relationship. Opening our minds to the viewpoints of others diffuses some of that power and grounds us in the communities we serve.

Alok A. Khorana, MD

MEDICAL GRAND ROUNDS

Steroids in the acutely ill: Evolving recommendations and practice 505

New information has been generated with regard to what causes critical illness-related corticosteroid insufficiency, how to diagnose it, who should receive corticosteroid treatment, and what regimens to use.

Stephen M. Pastores, MD, MACP, FCCP, FCCM

REVIEW

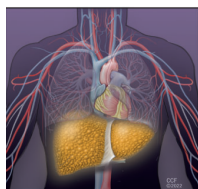
CME MOC

Primary and secondary prevention of atherosclerotic cardiovascular disease: A case-based approach 513

The authors present commonly encountered clinical scenarios that pose challenges in decision-making in primary and secondary prevention.

Essa H. Hariri, MD, MS; Mazen M. Al Hammoud, BS; Steven E. Nissen, MD; Donald F. Hammer, MD

REVIEW



Cirrhotic coagulopathy: A rebalanced hemostasis 523

Cirrhosis affects all 3 phases of coagulation, leading to a delicate new equilibrium, easily disturbed and tipped toward either bleeding or thrombosis by acute events such as infection, renal failure, and invasive procedures.

Achintya D. Singh, MD, MBBS; Simon R. Mucha, MD; Christina C. Lindenmeyer, MD

DEPARTMENTS

CME Calendar 482

CME/MOC Instructions 536

CME CREDIT TEST

Visit WWW.CCJM.ORG
Test your knowledge
of clinical topics and earn
AMA PRA Category 1 Credit™

CLEVELAND
CLINIC
JOURNAL OF
MEDICINE