

TABLE OF CONTENTS

FROM THE EDITOR

Circulating lipids are not all bad: 422

An LDL mimic that may be only skin deep

Although lipoprotein-X separates out by density in the low-density lipoprotein (LDL) fraction and thus may appear as LDL in the laboratory report, it is biologically unique.

Brian F. Mandell, MD, PhD

THE CLINICAL PICTURE

Xanthomas: Differentiating atherogenic from nonatherogenic 429

The patient had tendinous xanthomas on the dorsal joints of the hand and eruptive xanthomas on the buttock, as well as xanthoma striatum palmare on the volar aspect of the hand.

Vy Mai, MD; Hossein Akhondi, MD

THE CLINICAL PICTURE

The double-tongue sign 435

Computed tomography showed enlarged mylohyoid and geniohyoid muscles, surrounding inflammatory findings, and small gas retentions.

Nami Yoshimura, MD; Takashi Watari, MD, MHQS, MCTM, PhD; Keisuke Misao, MD; Toshihiro Imada, MD; Junji Mashino, MD

1-MINUTE CONSULT

Is exercise restriction necessary in patients with pericarditis? 437

The authors review current recommendations and illustrate possible approaches through a case scenario.

Felix Berglund, MD; Allan L. Klein, MD

1-MINUTE CONSULT

What are the considerations in patient selection and timing of risk-reducing mastectomy? 442

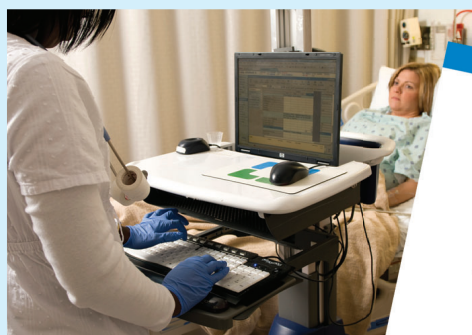
The option of risk-reducing mastectomy is for those at highest risk, and multidisciplinary conversations setting patient expectations are critical for optimal patient outcomes.

Holly J. Pederson, MD; Allison W. Kurian, MD, MSc; Zahraa Al Hilli, MD

CONTINUED ON PAGE 421

Upcoming Features

- Atherosclerotic cardiovascular disease: Primary and secondary prevention
- Cirrhotic coagulopathy
- Reducing breast-cancer risk: The role of chemoprevention



CLEVELAND
CLINIC
JOURNAL OF
MEDICINE

CONTINUED FROM PAGE 416

SYMPTOMS TO DIAGNOSIS

Altered mental status in a man with metabolic syndrome 445

A 25-year-old man with bipolar I disorder, hypertension, posttraumatic stress disorder, and obesity was found unresponsive with shallow breathing and foaming at the mouth.

Bernie P. Wu, BS; Molly Wheeler, PharmD; Jennifer K. Hockings, PharmD, PhD; Andrew Coulter, MD; Leopoldo Pozuelo, MD

1-MINUTE CONSULT

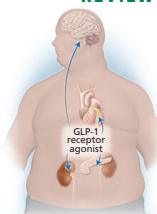
Do all patients with primary pulmonary coccidioidomycosis need antifungal therapy? 451

Patients diagnosed with this condition who have no symptoms or are mildly symptomatic do not require treatment and can be closely monitored.

Simran Gupta, MD; Nikita Ashcherkin, MD; Janis E. Blair, MD

REVIEW

CME MOC

**The role of GLP-1 receptor agonists in managing type 2 diabetes 457**

A review of the evidence regarding the benefits and adverse effects of GLP-1 receptor agonists in patients with type 2 diabetes mellitus or obesity.

Noura Nachawi, MD; Pratibha PR Rao, MD, MPH; Vinni Makin, MBBS, MD, FACE

SYMPTOMS TO DIAGNOSIS

Unilateral atrophic kidney in a 45-year-old woman 465

The patient presented with 2 days of constant, sharp, nonradiating flank pain on the right side, worse with movement and coughing, and severe enough to limit ambulation.

Mohammad A. Sohail, MD; John Sedor, MD; Lee Kirksey, MD, MBA; Steven C. Blaha, MD; Heather Hofmann, MD, FACP

DEPARTMENTS

CME Calendar 427**Correction 455**

The following article in the July 2022 issue contained an error: Ganeshan S, Kelemen B, Dhaliwal G, Zier L. An unexpected turn: A 71-year-old man with myocardial infarction. *Cleve Clin J Med.* 2022;89(7):401–407. doi:10.3949/ccjm.89a.21030

CME/MOC Instructions 472**CME CREDIT TEST**

Visit **WWW.CCJM.ORG**
Test your knowledge
of clinical topics and earn
AMA PRA Category 1 Credit™

CLEVELAND
CLINIC
JOURNAL OF
MEDICINE