

TABLE OF CONTENTS

FROM THE EDITOR

A clinical trial and another clinical practice bites the dust, or should there not be an appendix? 288

Studies over the past 2 decades have assessed an alternative approach to acute appendicitis: treatment with systemic antibiotics and observation.

Brian F. Mandell, MD, PhD

THE CLINICAL PICTURE

Atypical erythema as a clinical presentation of tinea incognito 295

The lesions were originally diagnosed as contact allergic dermatitis and treated with topical corticosteroids, but culture revealed *Trichophyton rubrum*.

Ana Ravić Nikolić, MD, PhD; Gordana Ristić

THE CLINICAL PICTURE

Skin-colored papules on the cheeks, acrochordons on the axillae 297

Biopsy revealed dermal follicular structures surrounded by a perifollicular fibrous sheath and a densely fibrous stroma, consistent with a fibrofolliculoma.

Irene López Riquelme, MD; María Ayala Blanca, MD, PhD; Elisabeth Gómez Moyano, MD, PhD

THE CLINICAL PICTURE

Spider nevi secondary to alcoholic chronic liver disease 301

The lesions blanched when pressure was applied centrally and refilled from the center outward when pressure was released.

Mohamed Adam Ali, MBBS, BSc, FHEA

THE CLINICAL PICTURE

Pigmented lesion on nail bed: Pseudo-Hutchinson sign 303

The discoloration had been present since the patient was 14, and it had not changed in appearance.

Yahya Daneshbod, MD; Majid Akrami, MD; Sara Fanaee, MD; Komeil Mirzaei Baboli, MD; Hadi Mirfazaelian, MD

THE CLINICAL PICTURE

Spotty skin pigmentation in Carney complex 307

Characteristic skin findings and their locations can indicate underlying hereditary lentiginosis syndromes.

Azusa Sano, MD; Yosuke Ono, MD, PhD; Naoya Fujita, MD; Yuji Tanaka, MD, PhD

CONTINUED ON PAGE 287

COMMENTARY

Appendicitis management: Is it time for a change? 309

Antibiotic therapy has been a successful alternative to surgery for more than 60 years, but surgery is still the primary treatment.

Anthony DeRoss, MD, FACS, FAAP; Alisan Fathalizadeh, MD

1-MINUTE CONSULT

Does incidentally detected common bile duct dilation need evaluation? 315

A patient-centered approach and knowledge of the diagnostic yield of further testing helps determine appropriate management.

Anam Rizvi, MD; Amrita Sethi, MD; John Poneros, MD; Kavel H. Visrodia, MD

SYMPTOMS TO DIAGNOSIS

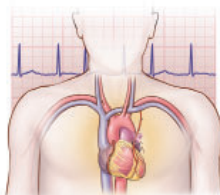
CME MOC

Dyspnea and cough in a lung transplant recipient 321

The patient developed sudden shortness of breath at rest, a decline in home spirometry values, and dry cough and fatigue.

Kamal A. Shair, MD, MEng; Razvan M. Chirila, MD

REVIEW

**Anticoagulation management of post-cardiac surgery new-onset atrial fibrillation 329**

A review of studies and recommendations for this condition.

Ghaith Alhatemi, MD; Mohamed Zghouzi, MD; Yasar Sattar, MD; Bachar Ahmad, BSc; Waqas Ullah, MD; M. Chadi Alraies, MD, MPH

REVIEW

Chronic anal pain: A review of causes, diagnosis, and treatment 336

The authors identify and review 3 main diagnostic categories: local causes, functional anorectal pain, and neuropathic pain syndromes.

Charles H. Knowles, PhD, FRCS, FACCRS (Hons); Richard C. Cohen, MD, FRCS

LETTERS TO THE EDITOR

Letter: Unilateral pulmonary edema 328

Abraham Joseph, MBBS, MD; Jonathan Rohde, DNP, MSN, APRN, CNP

In Reply: Unilateral pulmonary edema 328

Yoshihiro Harano, MD; Mikio Nakajima, MD, MPH, PhD

DEPARTMENTS

CME Calendar 293**CME/MOC Instructions 344**