

TABLE OF CONTENTS

FROM THE EDITOR

There should be more GOLD in the EMR 232

We can do better at making the clinical note a useful tool for communication in the electronic medical record.

Brian F. Mandell, MD, PhD

THE CLINICAL PICTURE

Hampton hump in acute pulmonary embolism 236

A 50-year-old patient presented with worsening dyspnea and cough with bilateral swelling of the lower extremities, with left-side swelling greater than right-side swelling.

Sovik De Sirkar, MD; Joshua Newman, MD; Sorcha Allen, MB, BCh, BAO; Ahmed Elkaryoni, MD; Alexandru Marginean, MD; Amir Darki, MD, MSc

THE CLINICAL PICTURE

Lacrimal gland involvement in a patient with sarcoidosis 239

The differential diagnosis included infection, malignancy, and inflammatory disorders such as immunoglobulin G4-related disease and sarcoidosis.

Tanmayi Pai, MD; Mohamed S. Muneer, MD; Kafayat Oyemade; Diva R. Salomao, MD; Vivek Gupta, MD; Dana Harris, MD

THE CLINICAL PICTURE

A brownish erythematous patch in the nipple-areola complex 241

Biopsy revealed neoplastic cells throughout the epidermis and granular layer, with abundant pale cytoplasm, intraglandular extension, and chronic inflammation in the papillary dermis.

Irene López Riquelme, MD; Elisabeth Gómez Moyano, MD, PhD; María Ayala Blanca, PhD; Leandro Martínez Pilar, MD, PhD

GUIDELINES TO PRACTICE

Managing stage 1 hypertension: Consider the risks, stop the progression 244

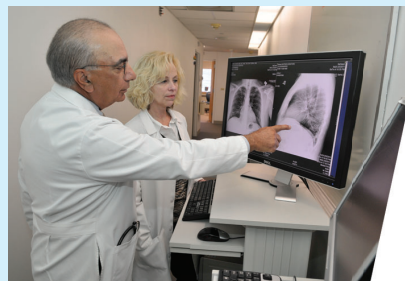
Guidelines on managing patients with stage 1 hypertension and a low 10-year risk of atherosclerotic cardiovascular disease.

Abel Hooker, MD; Kevin G. Buda, DO; Maarya Pasha, MD

CONTINUED ON PAGE 231

Upcoming Features

- Women's health update
- Biliary duct dilation
- Atrial fibrillation management after surgery



CONTINUED FROM PAGE 227

COMMENTARY

The underappreciated role of documentation in improving COPD care 249

Despite the importance of providing guideline-concordant care, there are still barriers to implementing evidence-based recommendations in providing care for patients with chronic obstructive pulmonary disease.

Solmaz Ehteshami-Afshar, MD, MSc; Naseema Merchant, MD

REVIEW

Psychogenic nonepileptic seizure: An empathetic, practical approach 252

Barriers to care include clinician misperceptions, lack of acceptance of the diagnosis, poor patient engagement with treatment, and lack of access to care.

Becky Bikat S. Tilahun, PhD; Jocelyn F. Bautista, MD

EDITORIAL

Psychogenic nonepileptic seizure: A neurologist's perspective 260

Confirming the diagnosis is only the start of the journey. The greater challenge and opportunity lie in how physicians present the diagnosis to the patient and family.

Elaine Wyllie, MD

REVIEW

Palliative care: An update for internists 262

A review of recent research to guide symptom management, advance-care planning, and communication training to maximize compassionate care.

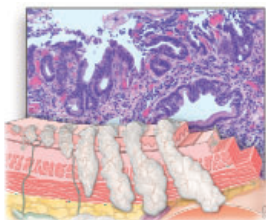
Rachel D. Havyer, MD, FAAHPM; Nauseley Abedini, MD, MSc; Robert L. Jayes, MD; Brenda Matti-Orozco, MD; Daniel H. Pomerantz, MD, MPH; Aziz A. Ansari, DO, SFHM, FAAHPM, FACP

REVIEW CME MOC

Esophageal adenocarcinoma: A dire need for early detection and treatment 269

A clinical overview focused on screening, multidisciplinary evaluation, and treatment of early esophageal adenocarcinoma.

Abel Joseph, MD; Siva Raja, MD, PhD; Suneel Kamath, MD; Sunguk Jang, MD; Daniela Allende, MD; Mike McNamara, MD; Gregory Videtic, MD; Sudish Murthy, MD; Amit Bhatt, MD



DEPARTMENTS

CME Calendar 234**CME/MOC Test instructions** 280