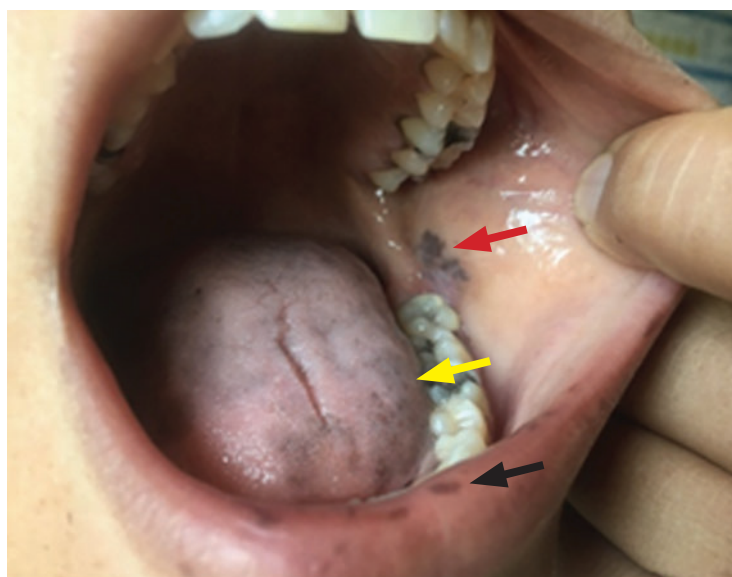


**Joseph Zhou, MD**  
Central Michigan University College  
of Medicine, Mount Pleasant, MI

**S. Sethu K. Reddy, MD, MBA, FRCPC, FACP, MACE**  
Senior Associate Dean—Research, and Professor, Central Michigan  
University College of Medicine, Mount Pleasant, MI

## Oral hyperpigmentation with weakness and salt-craving



**Figure 1.** Hyperpigmented lesions involved the lower lip (black arrow), tongue (yellow arrow), and buccal mucosa (red arrow).

A 30-YEAR-OLD WOMAN came to the emergency department with episodes of weakness and presyncope, as well as constipation, nausea, vomiting, and salt-craving. The symptoms had begun 9 months earlier, after a miscarriage at 10 weeks of pregnancy, and had increased in frequency. She had also noticed dark colorations on her lower lip and inner cheek, which her primary physician had told her might be due to ink from a pen.

She also said that after searching the Internet for conditions that included her symptoms, she was convinced that she had Addison disease.

### INITIAL MANAGEMENT AND WORKUP

Intravenous fluids were initiated for her symptoms of weakness and presyncope.

Physical examination demonstrated generalized cutaneous hyperpigmentation involving the lips, tongue, and buccal mucosa (**Figure 1**), as well as the gums and palmar creases.

Laboratory testing revealed a cortisol level of 0.8 µg/dL (reference range 3.10–22.40) and adrenocorticotropic hormone (ACTH) greater than 1,250 pg/mL (0.00–45.99). Intravenous saline and hydrocortisone succinate were initiated. The thyroid-stimulating hormone level was slightly elevated and, of note, her electrolytes and blood urea nitrogen-to-creatinine ratio were normal at the time of presentation to the emergency department. She was transitioned to hydrocortisone and fludrocortisone the next day.

### ADDISON DISEASE: KEY FEATURES

In the United States and Western Europe, Addison disease has a prevalence of 1 in 20,000 persons, higher in women than in men.<sup>1</sup> The diagnosis is challenging due to the nonspecific constitutional symptoms, which are frequently mistaken for psychiatric disorders, extra-adrenal gastrointestinal endocrine disorders, or other endocrine disorders such as hypothyroidism.<sup>2</sup> The symptoms are subtle and often insidious and can include hyperpigmentation, anorexia, nausea, and fatigue. Elevated ACTH levels and lack of a rise in cortisol levels after an ACTH stimulation test confirm the diagnosis. In our patient, the almost undetectable cortisol level combined with extremely high ACTH level confirmed primary adrenal insufficiency and obviated the need for a formal ACTH-stimulation test.

doi:10.3949/ccjm.89a.21036

The mainstay of treatment is lifelong oral hormone replacement therapy with glucocorticoids and mineralocorticoids at doses sufficient to keep electrolytes and plasma renin activity levels in the upper limits of normal.<sup>3,4</sup>

### Addisonian crisis

Undiagnosed Addison disease may lead to addisonian crisis, a life-threatening acute cortisol deficiency presenting as a rapid clinical decompensation to obtundation, encephalopathy, and shock, requiring emergency administration of intravenous fluids and parenteral glucocorticoids to prevent circulatory collapse.<sup>5,6</sup> A high index of suspicion and early diagnosis are paramount.

Adrenal insufficiency causes hyponatremia through insufficient excretion of free water and sodium wasting.<sup>7</sup> In a retrospective multicenter study of patients with autoimmune Addison disease,<sup>8</sup> of 247 patients for whom sodium concentrations were available, hyponatremia was present in 84% (207) and was the most consistent biochemical finding of Addison disease. Many patients may have concurrent autoimmune thyroiditis with high levels of thyroid-stimulating hormone.<sup>8</sup> Introducing thyroxine replacement before steroid replacement may cause addisonian crisis.<sup>8,9</sup>

### Hyperpigmentation

A hallmark sign of Addison disease is hyper-

pigmentation due to excess pituitary secretion of pro-opiomelanocortin, which is cleaved to ACTH, beta-endorphin, and melanocyte-stimulating hormone.<sup>10,11</sup> Intraoral pigmentation usually occurs before dermatologic pigmentation.<sup>11</sup>

### CASE CONCLUSION AND TAKE-HOME MESSAGE

Our patient's case illustrates how misattributing hyperpigmented lesions on the lip, tongue, and buccal mucosa as due to pen ink in a patient with symptoms of weakness, presyncope, salt-craving, nausea, and vomiting delayed the diagnosis of this potentially life-threatening disease. In this case, the patient's own Internet search raised suspicion of adrenal insufficiency.

At 6 months after her presentation to the emergency department, she had gained about 10 pounds, with no recurrence of the periods of weakness. Her buccal hyperpigmentation also appeared to be lightening.

Thus, in a patient presenting with new onset of oral hyperpigmentation, clinicians should consider the pigmented lesions in the context of clinical symptoms with a high degree of suspicion for Addison disease.

### DISCLOSURES

The authors report no relevant financial relationships which, in the context of their contributions, could be perceived as a potential conflict of interest.

### REFERENCES

1. Michels A, Michels N. Addison disease: early detection and treatment principles. *Am Fam Physician* 2014; 89(7):563–568. PMID:24695602
2. Joersjö P, Block L. A Challenging diagnosis that eventually results in a life-threatening condition: Addison's disease and adrenal crisis. *BMJ Case Rep* 2019; 12(12):e231858. doi:10.1136/bcr-2019-231858
3. Arit W, Allolio B. Adrenal insufficiency. *Lancet* 2003; 361(9372):1881–1893. doi:10.1016/S0140-6736(03)13492-7
4. Schmidt IL, Lahner H, Mann K, Petersenn S. Diagnosis of adrenal insufficiency: Evaluation of the corticotropin-releasing hormone test and Basal serum cortisol in comparison to the insulin tolerance test in patients with hypothalamic-pituitary-adrenal disease. *J Clin Endocrinol Metab* 2003; 88(9):4193–4198. doi:10.1210/jc.2002-021897
5. Burton C, Cottrell E, Edwards J. Addison's disease: identification and management in primary care. *Br J Gen Pract* 2015; 65(638):488–490. doi:10.3399/bjgp15X686713
6. Allolio B. Extensive expertise in endocrinology. Adrenal crisis. *Eur J Endocrinol* 2015; 172(3):R115–R124. doi:10.1530/EJE-14-0824
7. Garrahy A, Thompson CJ. Hyponatremia and glucocorticoid deficiency. *Front Horm Res* 2019; 52:80–92. doi:10.1159/000493239
8. Sævik ÅB, Åkerman AK, Grønning K, et al. Clues for early detection of autoimmune Addison's disease—myths and realities. *J Intern Med* 2018; 283(2):190–199. doi:10.1111/joim.12699
9. Osman IA, Leslie P. Addison's disease. Adrenal insufficiency should be excluded before thyroxine replacement is started. *BMJ* 1996; 313(7054):427. doi:10.1136/bmj.313.7054.427
10. Iyengar B, Misra RS, Subalakshmi. ACTH acts directly on melanocytes to stimulate melanogenesis—an in vitro study. *Indian J Pathol Microbiol* 1995; 38(4):399–402. PMID:9726151
11. Sarkar SB, Sarkar S, Ghosh S, Bandyopadhyay S. Addison's disease. *Contemp Clin Dent* 2012; 3(4):484–486. doi:10.4103/0976-237X.107450

**Address:** S. Sethu K. Reddy, MD, MBA, FRCPC, FACP, MACE, Central Michigan University College of Medicine, 1280 East Campus Drive, Mount Pleasant, MI 48858; redy3s@cmich.edu