

TABLE OF CONTENTS

FROM THE EDITOR

Decongesting heart failure with diuretics: Easier to prescribe than to fully understand 545

Digging deep into the pathophysiology of diuretic resistance reveals complex interacting pathways. But none of these pathways can fully explain or be used to safely reverse diuretic resistance.

Brian F. Mandell, MD, PhD

THE CLINICAL PICTURE

Blue sclera: An overlooked finding of iron deficiency 549

The pathogenesis is thought to involve thinning of collagen fibers of the sclera due to iron deficiency, allowing the bluish color of the underlying uvea to become visible.

Yasuhiro Kano, MD

THE CLINICAL PICTURE

Scaly plaques in a malnourished patient 551

A markedly low serum zinc level and the characteristic location of the rash in a patient with long-standing alcohol use disorder and cirrhosis led to the correct diagnosis.

Sandra Oska, MD; Harleen Arora, MD; Allison Zarbo, MD

THE CLINICAL PICTURE

Mucormycosis presenting as dental pain 553

A root canal procedure failed to relieve the pain, and 1 week later the patient developed mobility of the left upper teeth.

Pankaj Garg, MS, MBBS; Aalam Sohal, MD; Sankalp Mittal, MDS

1-MINUTE CONSULT

CME MOC

How do I interpret and use quantitative buprenorphine and norbuprenorphine urine levels? 557

Confirmatory testing of urine samples can be useful in outpatient settings where buprenorphine dosing is not directly observed. But retaining and engaging the patient in effective treatment should be the ultimate goals of testing.

Richard C. Waters, MD, MSc; Matthew Perez, MD

CONTINUED ON PAGE 544

Upcoming Features

- Update on benign paroxysmal positional vertigo
- When and when not to treat urinary tract infection



CLEVELAND
CLINIC
JOURNAL OF
MEDICINE

CONTINUED FROM PAGE 543

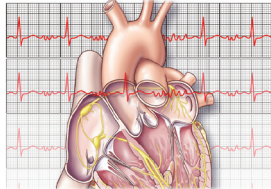
1-MINUTE CONSULT CME MOC

How do we maximize diuresis in acute decompensated heart failure? 561

The initial goal is to maximize loop diuretic therapy using urine output or urinary sodium for guidance. Combination therapy can be used when patients respond poorly to escalating loop diuretic doses.

Saeid Mirzai, DO; Christopher N. Kanaan, MD; Felix Berglund, MD; Maria Mountis, DO; Heba Wassif, MD, MPH

1-MINUTE CONSULT



Atrial fibrillation: Rate control or rhythm control? 567

Rate control has been preferred as the primary approach, but the pendulum is swinging in favor of rhythm control.

Radhika Deshpande, MBBS; Yasser Al Khadra, MD; Raad Al-Tamimi, MBBS; Nour Albast, MBBS; Mohamed Labedi, MD

SYMPTOMS TO DIAGNOSIS

A 65-year-old man with melena and a blood disorder 573

The patient had chronic anemia related to primary myelofibrosis and was being treated with epoetin alfa and ruxolitinib, with blood transfusions every other week.

Monia E. Werlang, MD; Marilia L. Montenegro, MD; Bhaumik Brahmbhatt, MD, MBBS

GUIDELINES TO PRACTICE

Diagnostic stewardship for urinary tract infection: A snapshot of the expert guidance 581

New guidance on ordering, processing, and reporting urine cultures focuses on reducing unnecessary antibiotic use and the misdiagnosis of urinary tract infection.

Glenn T. Werneburg, MD, PhD; Daniel D. Rhoads, MD

SYMPTOMS TO DIAGNOSIS

Confusion in a 22-year-old woman, and diagnostic uncertainty 589

The patient had been complaining of gradual-onset and progressive headache and neck and back pain for 3 weeks.

Brian Elliott, MD; Christopher Newey, DO, MS; Katelynn Alcorn, MPH; Luke McCoy, MD

DEPARTMENTS

CME Calendar 547

Correction: 597

The role of GLP-1 receptor agonists in managing type 2 diabetes

The following article in the August 2022 issue contained an error: *Nachawi N, Rao PP, Makin V. The role of GLP-1 receptor agonists in managing type 2 diabetes. Cleve Clin J Med 2022; 89(8): 457–464. doi:10.3949/ccjm.89a.21110*

CME/MOC Instructions 600