

TABLE OF CONTENTS

FROM THE EDITOR

Sometimes the look is worth the walk 4

We do not routinely look at blood smears today. The need for expediency and efficiency limit the time spent on activities with a low yield for influencing care. And yet, for some conditions in some patients, going back to the basics can be clinically rewarding, and even memorable.

Brian F. Mandell, MD, PhD

THE CLINICAL PICTURE

Megaloblastic anemia due to vitamin B₁₂ deficiency 8

The 75-year-old patient presenting with altered mental status and pancytopenia had a history of peptic ulcer disease and subtotal gastrectomy.

Nellowe Candelario, MD; Catherine Klein, MD

THE CLINICAL PICTURE

A large, painless bulla on the right foot 10

A patient with a history of type 2 diabetes and diabetic neuropathy had a hemoglobin A1c of 10.3% at presentation.

Jorge Camilo Mora, MD, MPH; Amalia Galindez, MD, FACP

REVIEW

Clinical impact of 2020 American Heart Association statement on menopause and cardiovascular disease risk 13

The statement supports the notion that the transition of menopause itself leads to increased cardiovascular risk and mortality.

Tara K. Iyer, MD, NCMP; Heather Hirsch, MD, MS, NCMP

CONTINUED ON PAGE 3

Upcoming Features

- Evaluating breast cancer risk
- When is testing needed for penicillin allergy?
- Anemia of chronic kidney disease



CLEVELAND
CLINIC
JOURNAL OF
MEDICINE

CONTINUED FROM PAGE 2

REVIEW

Discontinuing antidepressants: Pearls and pitfalls 18

To date, no formal schedule for tapering antidepressants has been validated. The maxim “slower is better” applies.

Samantha J. Zwiebel, MD; Adele C. Viguera, MD

SYMPTOMS TO DIAGNOSIS **CME MOC**

A painful mass in the jaw 27

The patient presented with a painful mass in the left side of her jaw, headache, lockjaw, painful swallowing, night sweats, and unintentional weight loss.

Kanishka G. Patel, MD; Jasmine C. Huynh, MD; James Liu, MD; Paul Aronowitz, MD; May Cho, MD

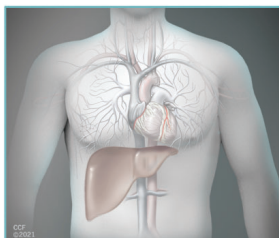
MEDICAL GRAND ROUNDS

Evaluation and management of orthostatic hypotension: Limited data, limitless opportunity 36

Orthostatic hypotension is common and can have serious consequences. The author offers a systematic approach to evaluation and management.

Aldo J. Peixoto, MD

REVIEW



Cardiac considerations in liver transplantation 46

Today's transplant patients are older and more likely to have cardiac comorbidities, and effects of advanced liver disease on the circulatory system pose challenges in perioperative management.

Vikram Sharma, MD, MD(Res); Cerise Kleb, MD; Chirag Sheth, MD; Beni Rai Verma, MD; Vardhmaan Jain, MD; Ruchi Sharma, MD, MS; Parth Parikh, MD; Jacek Cywinski, MD; K. V. Narayanan Menon, MD, FAASLD; Jamak Modaresi Esfeh, MD; Bijan Egtesad, MD; Cristiano Quintini, MD; Teresa Diago Uso, MD; Michael Z. Y. Tong, MD; Ravi Nair, MD; Ajay Bhargava, MD; Maan Fares, MD

DEPARTMENTS

CME Calendar 6

CME/MOC Instructions 56



**Visit WWW.CCJM.ORG
Test your knowledge
of clinical topics**

**CLEVELAND
CLINIC
JOURNAL OF
MEDICINE**