

TABLE OF CONTENTS

FROM THE EDITOR	
Awareness can prompt the search for clinical zebras	133
When do we look hard for uncommon causes of common symptoms?	
Brian F. Mandell, MD, PhD	
THE CLINICAL PICTURE	
Median arcuate ligament syndrome: Incidental finding or real problem?	140
A woman was admitted with pain in the epigastrium and right upper quadrant that radiated to the back, as well as nausea and dry heaves.	
Bayarmaa Mandzhieva, MD; Hammad Zafar, MD; Akriti Jain, MD; Manoucher Manoucheri, MD, FACP	
EDITORIAL	
Median arcuate ligament syndrome: A clinical dilemma	143
Patients with chronic abdominal pain can benefit from a multidisciplinary evaluation.	
John H. Rodriguez, MD, FACS	
THE CLINICAL PICTURE	
A cutaneous clue to HIV infection	145
A retired trucker presented with fever, cough, dyspnea, and a rash on his forehead.	
Stephen Chan, MD; Paul Aronowitz, MD	
THE CLINICAL PICTURE	
Not all wheezing is COPD	147
A missed diagnosis led to inappropriate referral for lung transplant.	
Vipul Patel, MD; Nikhil Madan, MD, FCCP	
EDITORIAL	
All that wheezes...	150
All that wheezes is not asthma, but it is airway obstruction of one kind or another.	
Aparna Bhat, MD; Rendell W. Ashton, MD	
THE CLINICAL PICTURE	
Anterior interosseous nerve palsy caused by Parsonage-Turner syndrome	155
A 58-year-old man presented with difficulty moving his left hand.	
Kosuke Ishizuka, MD; Kiyoshi Shikino, MD, PhD; Masatomi Ikusaka, MD, PhD	

CONTINUED ON PAGE 132

CONTINUED FROM PAGE 130

REVIEW

**Vaccination in pregnancy:
A call to all providers for help** **157**

Vaccination in pregnancy is a public health priority that is often neglected.

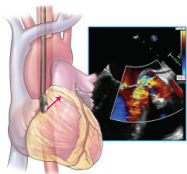
Jonathan D. Emery, MD; Daniel Moussa, BS

REVIEW **CME MOC**

Imaging to evaluate suspected infective endocarditis **163**

What if echocardiographic findings are initially negative and the patient continues to have bacteremia?

Ikram-UI Haq, MD; Iqraa Haq, BS; Brian Griffin, MD; Bo Xu, MD, FACC, FRACP, FASE



REVIEW

**Male and female pattern hair loss:
Treatable and worth treating** **173**

Early recognition and treatment can help preserve as much hair as possible.

Nina L. Tamashunas, BS; Wilma F. Bergfeld, MD, FAAD

REVIEW **CME MOC**

**Frequently asked questions about managing cancer pain:
An update** **183**

Pain management can involve pharmacologic and nonpharmacologic therapies.

Renato V. Samala, MD, MHPE, FACP, FAAHPM; Ruth L. Lagman, MD, MPH, MBA, FACP, FAAHPM;
Sina Najafi, DO; Flannery Fielding, CNP, MSN

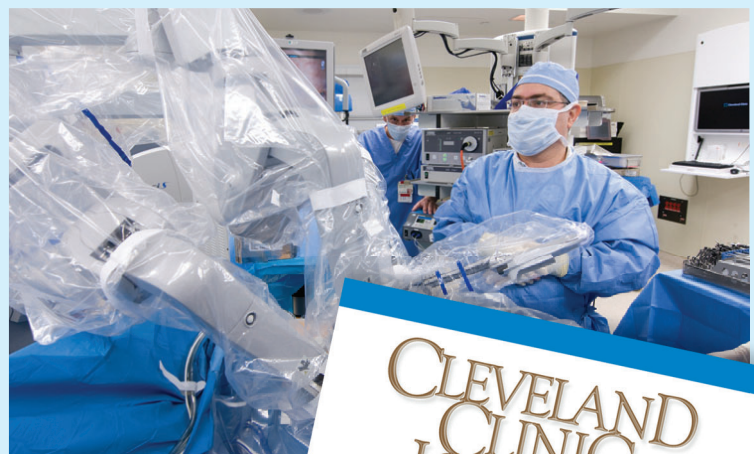DEPARTMENTS

CME Calendar **136**

CME/MOC Instructions **192**

Upcoming Features

- Dual antiplatelet therapy:
Personalize duration
- COVID-19 long-haulers:
Hard road ahead
- Quetiapine is not a sleeping pill
- Acute hip fracture:
Update on management
- CABG: When, why, and how?



**CLEVELAND
CLINIC
JOURNAL OF
MEDICINE**