

## TUYET NGUYEN ABRAHAM, MD, MSc

Department of Primary Care, Captain James A. Lovell Federal Healthcare Center, North Chicago, IL; Clinical Educator, Rosalind Franklin University of Medicine and Science, North Chicago, IL

## PETER MORAWIECKI, MD

Department of Pathology, Captain James A. Lovell Federal Healthcare Center, North Chicago, IL; Assistant Professor, Rosalind Franklin University of Medicine and Science, North Chicago, IL

## AMY FLISCHEL, MD

Department of Dermatology, Captain James A. Lovell Federal Healthcare Center, North Chicago, IL

## BHARATA AGRAWAL, MD

Department of Hematology and Oncology, Captain James A. Lovell Federal Healthcare Center, North Chicago, IL

# Aleukemic leukemia cutis

**A**N 85-YEAR-OLD MAN presented with a 2-week history of rapidly progressive nodules on the scalp, neck, trunk, and extremities (**Figure 1**). He denied fever, weight loss, anorexia, night sweats, pruritus, or pain, and he had not started any new medications.

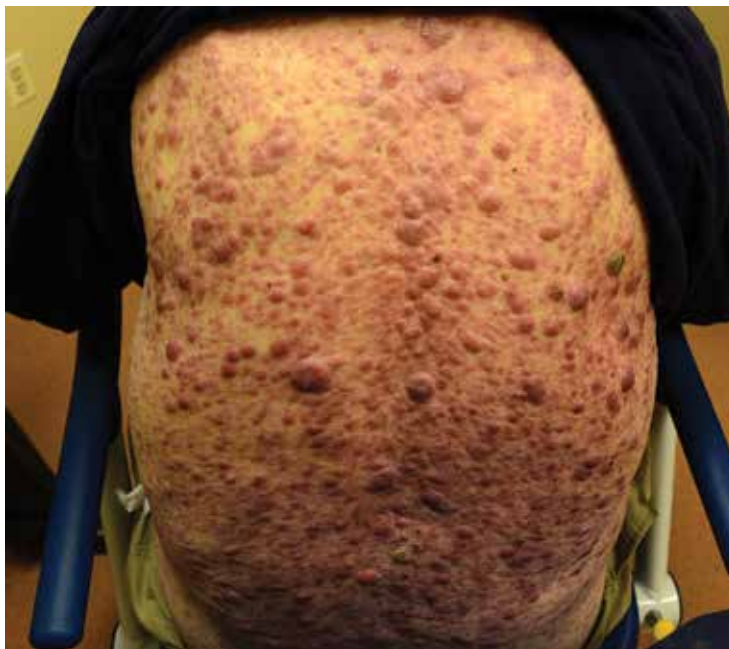On examination, the numerous firm, indurated nodules ranged in size from 1 to 4 cm. There was no palpable lymphadenopathy.

Results of a peripheral blood cell count showed the following:

- Hemoglobin 12.5 g/dL (reference range 13.0–17.0)
- Platelet count  $154 \times 10^9/L$  (130–400)
- White blood cell count  $5.0 \times 10^9/L$  (4.0–11.0)
- Neutrophils  $1.7 \times 10^9/L$  (1.5–8.0)
- Lymphocytes  $2.2 \times 10^9/L$  (1.0–4.0)
- Monocytes  $1.0 \times 10^9/L$  (0.2–1.0)
- Eosinophils 0 (0–0.4)
- Basophils 0 (0–0.2)
- Blasts 0.

Punch biopsy study of the skin (**Figure 2**), showed diffuse atypical cellular infiltrate in the dermis, sparing the epidermis, with a distinct grenz zone, a narrow band of uninvolved papillary dermis between the neoplastic process and the uninvolved epidermis. The tumor cells were large, with ample, vacuolated cytoplasm, large blastic nuclei with irregular nuclear membranes, and abundant mitotic figures (**Figure 3**). The cells were arranged in a diffuse sheet, without glandular, squamous, or adnexal differentiation. They did not demonstrate pigment, which would have suggested melanoma. There was no lymphoid follicle formation.

Immunohistochemistry study demonstrated that the cells co-expressed T-cell markers (CD4 and CD43) and monocyte markers (CD68 and lysozyme). CD30 and ALK-1 were not expressed, ruling out primary cutaneous CD30 T-cell lymphoproliferative disorders



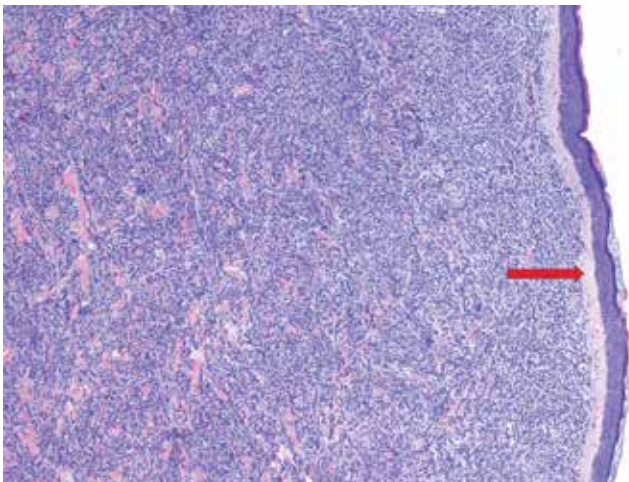
**Figure 1.** The firm, indurated nodules ranged in size from 1 to 4 cm.

and anaplastic large-cell lymphoma. CD2 and CD3 are typically expressed in mycosis fungoides, but these were not expressed. The tumor cells did not express myeloperoxidase, a myeloid marker.

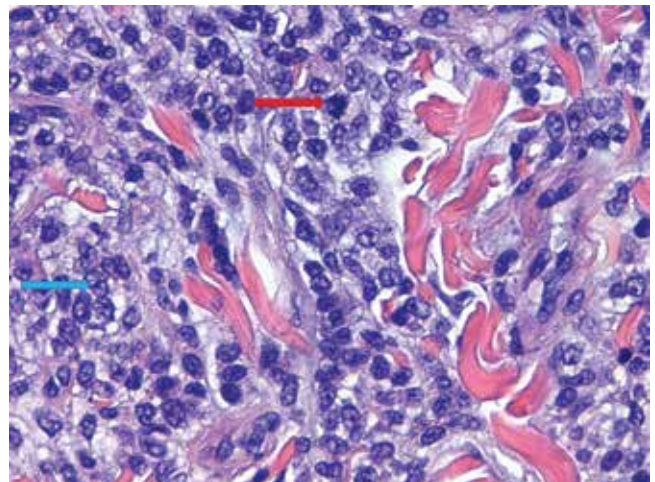
The findings were consistent with leukemic cells with monocytic differentiation. The infiltrate was unusual because leukemic infiltrates typically demonstrate a high nuclear-to-cytoplasmic ratio, but in this case the malignant cells had moderate amounts of cytoplasm due to the monocytic differentiation. Also, a grenz zone is more typically seen in B-cell lymphomas, and T cells more typically demonstrate epidermotropism.

Bone marrow aspiration was performed and revealed a hypercellular bone marrow with trilineage maturation with only 2% blasts. The fluorescence in situ hybridization testing for

doi:10.3949/ccjm.86a.18057



**Figure 2.** Punch biopsy showed diffuse atypical cellular infiltrate in the dermis, with a grenz zone (red arrow) of uninvolved papillary dermis (hematoxylin and eosin,  $\times 10$ ).



**Figure 3.** The tumor cells were large, with ample, vacuolated cytoplasm, large blastic nuclei (blue arrow) with irregular nuclear membranes, and abundant mitotic figures (red arrow) (hematoxylin and eosin,  $\times 40$ ).

myelodysplastic syndrome and acute myeloid leukemia was normal. A diagnosis of aleukemic leukemia cutis was made.

After 2 months of chemotherapy with azacitidine, the nodules were less indurated. Treatment was briefly withdrawn due to the development of acute pneumonia, leading to a rapid progression of cutaneous involvement. Despite restarting chemotherapy, the patient died.

### ■ ALEUKEMIC LEUKEMIA CUTIS

The differential diagnosis of leukemia cutis is diverse and extensive. Patients often present with painless, firm, indurated nodules, papules, and plaques.<sup>1</sup> The lesions can be small, involving a small amount of body surface area, but can also be very large and diffuse.

In our patient's case, there were no new drugs or exposures to suggest a drug-related eruption, or pruritus or pain to suggest an inflammatory process. The rapid progression of the lesions suggested either an infectious or malignant process. The top 3 conditions in the differential diagno-

sis, based on his clinical presentation, were cutaneous T-cell lymphoma, cutaneous CD30+ anaplastic large-cell lymphoma, and a drug-induced cutaneous pseudolymphoma.

Skin biopsy is required to differentiate leukemia cutis from the other conditions. On skin biopsy study, leukemia cutis is characterized by infiltration of the skin by leukemic cells and is seen in 10% to 15% of patients with acute myeloid leukemia.<sup>2</sup> In 5% of cases, leukemia cutis can present without bone marrow or peripheral signs of leukemia, hence the term aleukemic leukemia cutis.<sup>3</sup> Cutaneous signs can occur before, after, or simultaneously with systemic leukemia.<sup>4</sup>

In the absence of systemic symptoms, the diagnosis is made when progressive cutaneous symptoms are present. The prognosis for aleukemic leukemia cutis is poor. Prompt diagnosis with skin biopsy is paramount to improve outcomes.

**ACKNOWLEDGMENT:** We would like to recognize Maanasa Devabhaktuni for her assistance in reporting this case.

### ■ REFERENCES

1. Yonal I, Hindilerden F, Coskun R, Dogan OI, Nalcaci M. Aleukemic leukemia cutis manifesting with disseminated nodular eruptions and a plaque preceding acute monocytic leukemia: a case report. *Case Rep Oncol* 2011; 4(3):547–554. doi:10.1159/000334745
2. Cho-Vega JH, Medeiros LJ, Prieto VG, Vega F. Leukemia cutis. *Am J Clin Pathol* 2008; 129(1):130–142. doi:10.1309/WYACYWVF6NGM3WBRT
3. Kang YS, Kim HS, Park HJ, et al. Clinical characteristics of 75 patients with leukemia cutis. *J Korean Med Sci* 2013; 28(4):614–619. doi:10.3346/jkms.2013.28.4.614
4. Obiozor C, Ganguly S, Fraga GR. Leukemia cutis with lymphoglandular bodies: a clue to acute lymphoblastic leukemia cutis. *Dermatol Online J* 2015; 21(8)pii:13030/qt6m18g35f. PMID:26437164

**ADDRESS:** Tuyet Nguyen Abraham, MD, MSc, Department of Primary Care, Captain James A. Lovell Federal Healthcare Center, 3001 Green Bay Road, North Chicago, IL 60064; tuyet.abraham@va.gov