

JOSIAH D. MCCAIN, MD
Department of Internal Medicine,
Mayo Clinic, Jacksonville, FL

MONIA E. WERLANG, MD
Department of Gastroenterology and
Hepatology, Mayo Clinic, Jacksonville, FL

ANDRAS KHOOR, MD, PhD
Department of Laboratory Medicine
and Pathology, Mayo Clinic,
Jacksonville, FL

ISABEL MIRA-AVENDANO, MD
Department of Pulmonary Medicine, Mayo
Clinic, Jacksonville, FL

Lung complications of prescription drug abuse

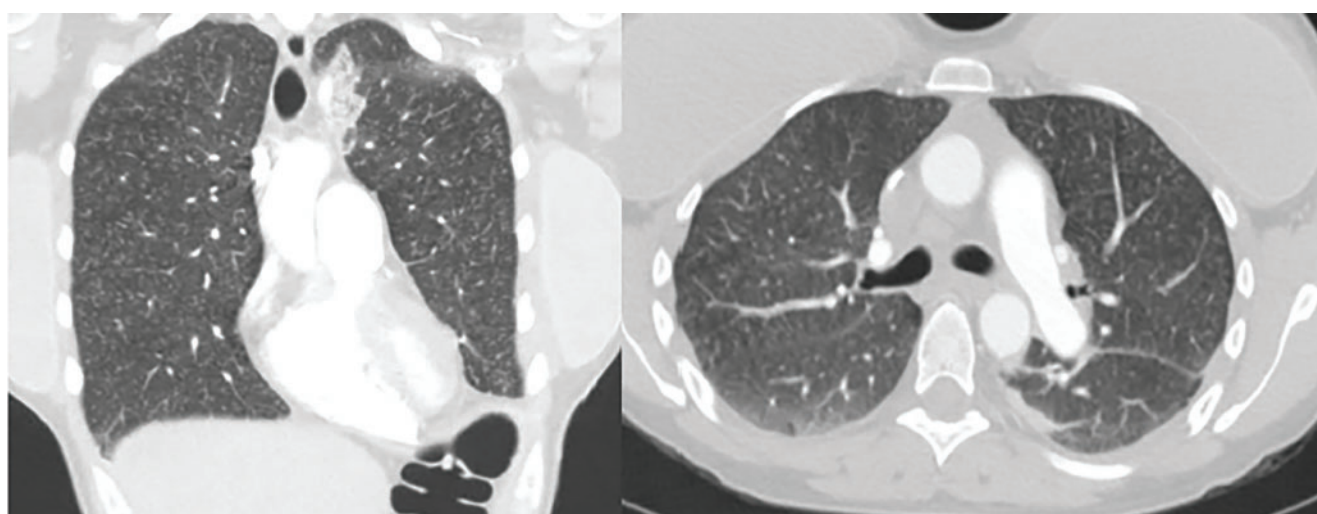


Figure 1. Computed tomography of the chest showed innumerable, diffuse micronodules in a centrilobular pattern.

A 39-YEAR-OLD WOMAN presented to the emergency department with a 2-day history of exertional dyspnea, left-sided chest pain with pleuritic characteristics, and cough without fever or chills. She had a history of severe postprandial nausea and vomiting, weight loss, and malnutrition, which had necessitated placement of a peripherally inserted central catheter in her right arm for total parenteral nutrition.

On physical examination, the patient was afebrile but tachycardic and tachypneic. Her oxygen saturation on room air by pulse oximetry was 91%, though she was not in significant distress. Breath sounds were equal bilaterally and clear, with symmetrical chest wall expansion.

Her white blood cell count was $18.5 \times 10^9/L$ (reference range 3.5–10.5), with 19.3% eosinophils (reference range 1%–7%); her D-

dimer level was also elevated.

Computed tomography of the chest showed innumerable, diffuse micronodules in a centrilobular pattern (**Figure 1**).

Conditions to consider in a patient with these imaging findings in the setting of leukocytosis and eosinophilia include mycobacterial infection, hypersensitivity reaction, diffuse fungal infiltrates, and possibly metastatic disease such as thyroid carcinoma or melanoma. The patient reported having had a purified protein derivative test that was positive for tuberculosis, but she denied having had active disease.

She underwent bronchoscopy. Bronchoalveolar lavage specimen study showed an elevated eosinophil count of 17%. Acid-fast staining detected no organisms. Transbronchial biopsy study revealed foreign-body granulomas from microcrystalline cellulose

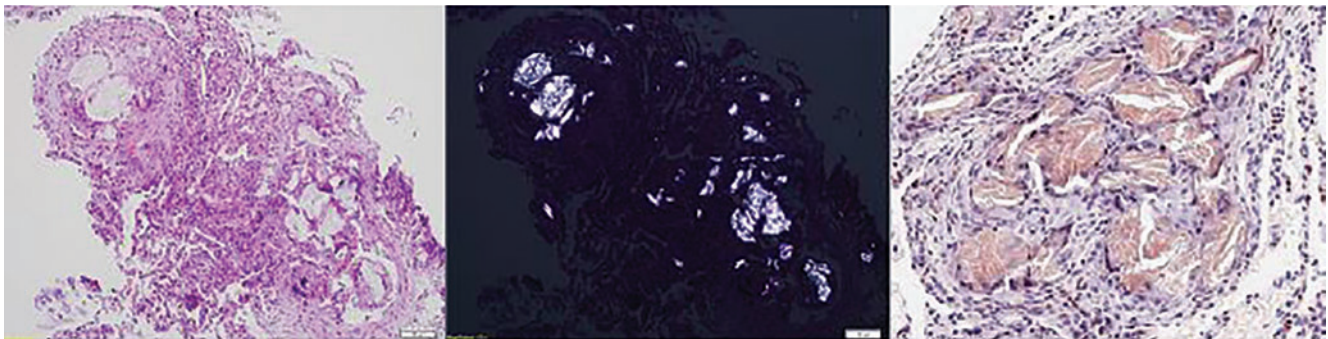


Figure 2. A transbronchial biopsy revealed microcrystalline cellulose particles. Left, hematoxylin-eosin stain (original magnification $\times 60$); middle, polarized light ($\times 60$); right, Congo red stain ($\times 200$).

microemboli deposited in the microvasculature of the patient's lungs. Upon further questioning the patient admitted she had crushed oral tablets of prescribed opioids and injected them intravenously.

■ A COMPLICATION OF INJECTING ORAL TABLETS

Oral tablets typically contain talc, cellulose, cornstarch, or combinations of these substances as binding agents. When pulverized, the powder can be combined with water to form an injectable solution with higher and more rapid bioavailability.^{1,2} The binders, however, are insoluble and accumulate in various tissues.

Intravenous injection of microcellulose has been shown to produce pulmonary and peripheral eosinophilia in birds. In humans, the immune response in foreign body granulomatosis can vary, and case reports have not men-

tioned eosinophils in the lungs or serum.^{3,4}

Deposition of these particles in pulmonary vessels is common and can trigger a potentially fatal reaction, presenting as acute onset of cough, chest pain, dyspnea, fever, and pulmonary hypertension. The severity of these clinical findings is relative to the degree of pulmonary hypertension created by the arteriolar involvement of these emboli.^{2,5}

In our patient's lung biopsy samples, microcrystalline cellulose was clearly visible under polarized light, and it stained with Congo red (Figure 2).

Our patient's exertional dyspnea and hypoxemia resolved during 1 week of hospitalization with conservative management and supplemental oxygen. She was referred to our pain rehabilitation clinic, where she was successfully weaned from narcotics. Her pulmonary findings on computed tomography were still present 3 years after her initial images, though less prominent.

The patient had crushed her oral tablets of prescribed opioids and injected them intravenously

■ REFERENCES

1. Nguyen VT, Chan ES, Chou SH, et al. Pulmonary effects of IV injection of crushed oral tablets: "excipient lung disease." *AJR Am J Roentgenol* 2014; 203(5):W506–W515. doi:10.2214/AJR.14.12582
2. Bendeck SE, Leung AN, Berry GJ, Daniel D, Ruoss SJ. Cellulose granulomatosis presenting as centrilobular nodules: CT and histologic findings. *AJR Am J Roentgenol* 2001; 177(5):1151–1153. doi:10.2214/ajr.177.5.1771151
3. Radow SK, Nachamkin I, Morrow C, et al. Foreign body granulomatosis. Clinical and immunologic findings. *Am Rev Respir Dis* 1983; 127(5):575–580. doi:10.1164/arrd.1983.127.5.575
4. Wang W, Wideman RF Jr, Bersi TK, Erf GF. Pulmonary and hematological inflammatory responses to intravenous cellulose micro-particles in broilers. *Poult Sci* 2003; 82(5):771–780. doi:10.1093/ps/82.5.771
5. Marchiori E, Lourenco S, Gasparetto TD, Zanetti G, Mano CM, Nobre LF. Pulmonary talcosis: imaging findings. *Lung* 2010; 188(2):165–171. doi:10.1007/s00408-010-9230-y

ADDRESS: Josiah McCain, MD, Department of Internal Medicine, Mayo Clinic, 4500 San Pablo Road, Jacksonville, FL 32224; mccain.josiah@mayo.edu