

STUART SILVERMAN, MD

Cedars-Sinai Medical Center, Los Angeles, CA;
Medical Director, OMC Clinical Research Center,
Beverly Hills, CA; Clinical Professor of Medicine, David
Geffen School of Medicine at UCLA, Los Angeles, CA

ELI KUPPERMAN, MD

Department of Orthopaedic Surgery,
University of California, Los Angeles

SUSAN BUKATA, MD

David Geffen School of Medicine at UCLA,
Los Angeles, CA

Bisphosphonate-related atypical femoral fracture: Managing a rare but serious complication

ABSTRACT

Atypical femoral fracture is a rare but serious complication of long-term bisphosphonate therapy. Although the benefit of preventing osteoporotic fractures greatly outweighs the risk of atypical fracture in bisphosphonate users, concern about atypical fracture risk has led to a decrease in bisphosphonate use. What are the risks, and how do we treat atypical femoral fracture?

KEY POINTS

The benefits of bisphosphonate therapy in reducing fracture risk outweigh the risk of atypical fracture.

Bisphosphonate use for longer than 5 years greatly increases the risk of atypical femoral fracture.

Treatment of atypical femoral fracture varies depending on whether the patient has pain and whether the fracture is complete or incomplete.

BISPHTHOSPHONATE THERAPY minimizes bone loss and reduces fracture risk by up to 50% in patients with osteoporosis,¹ but it is also associated with increased risks of osteonecrosis of the jaw and atypical femoral fracture. Although atypical femoral fractures are rare, they can have a devastating effect. Patient concern about this complication has contributed to a decrease in bisphosphonate use by about half in the last decade or so,^{2,3} and we fear this could result in an increase in hip fracture rates.

In this article, we examine the evidence on bisphosphonate-associated atypical femoral fractures, including risks, pathogenesis, treatment, and prevention.

■ ATYPICAL FRACTURES INVOLVE THE FEMORAL SHAFT, NOT THE HEAD

An atypical femoral fracture is a transverse fracture of the femoral shaft (diaphysis), defined by both clinical criteria and radiographic appearance.

To be defined as atypical, a femoral fracture must meet 4 of the following 5 criteria⁴:

- Occurs with minimal or no trauma
- Has a predominantly transverse fracture line, originating at the lateral cortex and sometimes becoming oblique as it progresses medially across the femur
- Extends through both cortices and may be associated with a medial spike (complete fractures); or involves only the lateral cortex (incomplete fractures)
- Is noncomminuted or minimally comminuted

Dr. Silverman has disclosed commercial interests (consulting, board membership, teaching, and speaking) with Amgen, Eli Lilly, Pfizer, Radius Health, and Roche Pharmaceuticals.

Dr. Bukata has disclosed commercial interests (consulting, teaching, and speaking) with Amgen, Eli Lilly, and Radius Health.

doi:10.3949/ccjm.85a.17119

- Shows localized periosteal or endosteal thickening (termed “beaking” or “flaring”) of the lateral cortex at the fracture site.

Several minor features are also important but are not required, eg:

- Cortical thickening of the femoral shaft
- Unilateral or bilateral prodromal pain preceding the fracture
- Bilateral incomplete or complete femoral diaphysis fractures
- Delayed fracture healing.

Atypical femoral fracture can occur anywhere along the shaft, from just distal to the lesser trochanter to just proximal to the supracondylar flare. However, most occur in 2 areas, with 1 cluster centered at about 41 mm from the lesser trochanter (more common in relatively younger patients) and the other at 187 mm.⁵

■ ABSOLUTE RISK IS LOW BUT INCREASES WITH LONGER USE

Atypical femoral fractures are rare. Schilcher et al⁶ reviewed radiographs of 1,234 women who had a subtrochanteric or shaft fracture and found 59 (4.6%) of fractures were atypical. In a systematic review of 14 studies,⁷ the incidence ranged from 3.0 to 9.8 cases per 100,000 patient-years.

Furthermore, not all atypical femoral fractures are in bisphosphonate users: 7.4% were in nonusers in 1 series⁸ and 22% in another.⁹

Nevertheless, most studies show that bisphosphonate use increases the incidence of atypical femoral fracture, and the incidence increases with duration of use, especially after 3 years.⁷

An international task force of the American Society for Bone and Mineral Research listed the absolute risk as between 3.2 and 50 cases per 100,000 patient-years, with longer use (> 5 years) increasing the risk to about 100 per 100,000 patient-years.⁴ After stopping bisphosphonate therapy, the risk diminished by 70% per year.⁹

In another study, for 0.1 to 1.9 years of therapy, the age-adjusted atypical fracture rates were 1.78 per 100,000 per year (95% confidence interval [CI] 1.5–2.0), increasing to 113.1 per 100,000 per year (95% CI 69.3–156.8) with exposure from 8 to 9.9 years.¹⁰

A case-control study found that more than 5 years of bisphosphonate use increased the

fracture risk by an odds ratio of 2.74 (95% CI 1.25–6.02).¹¹

The incidence of typical femoral fracture was higher in those who adhered better to their oral bisphosphonate regimen in some studies,¹² but the opposite was true in others.¹³

The benefits of bisphosphonate therapy in reducing fracture risk, however, outweigh the risk of atypical fracture.⁴

We do not know whether the rate of atypical femoral fracture is increasing. A review of Kaiser Permanente Northwest records found that the rates of atypical femoral shaft fracture had remained stable from 1996 to 2009. However, 61.9% of patients who met the strict radiographic criteria had taken oral bisphosphonates.¹⁴ These data suggest that bisphosphonate use has not increased the overall population-based risk for subtrochanteric and femoral shaft fractures, but that bisphosphonates and other risk factors may have increased the likelihood that such fractures will exhibit atypical radiographic features.

A population-based study in Denmark¹³ found that alendronate use longer than 10 years was associated with an adjusted 30% lower risk of hip fracture and no increase in the risk of subtrochanteric and femoral shaft fracture. In addition, the risk of subtrochanteric and femoral shaft fracture was lower with high adherence to alendronate treatment (based on medication possession ratio > 80%) compared with low adherence (ratio < 50%) (odds ratio 0.88, 95% CI 0.77–0.99). The risk was not increased in current vs past users.

The Danish study¹³ used the coding of the 10th revision of the International Statistical Classification of Diseases and Related Health Problems (ICD-10) to identify subtrochanteric and femoral shaft fractures without radiologic review for atypical radiographic features. The lack of specific ICD-10 coding for subtrochanteric and femoral shaft fractures with atypical radiographic features has limited our knowledge of their incidence.

Contralateral fracture in more than one-fourth of cases

After an atypical femoral fracture, patients have a significant risk of fracture on the contralateral side. In a case-control study, 28% of patients with atypical femoral fracture

The benefits of bisphosphonates outweigh the low risk of atypical femoral fracture

suffered a contralateral fracture, compared with 0.9% of patients presenting with a typical fracture pattern (odds ratio 42.6, 95% CI 12.8–142.4).¹⁵

Contralateral fracture occurs from 1 month to 4 years after the index atypical femoral fracture.¹⁶

There are reports of bisphosphonate-related low-impact fractures in other sites such as the tibia¹⁷ and forearm.¹⁸ However, they may be too rare to warrant screening.

Mortality rates

A Swedish database study found that patients with atypical femoral fractures, whether bisphosphonate users or nonusers, do not have higher mortality rates than patients with ordinary subtrochanteric or femoral shaft fractures.¹⁹ Furthermore, the mortality rates for those with atypical femoral fracture were similar to rates in the general population. In contrast, patients with an ordinary femoral fracture had a higher mortality risk than the general population.¹⁹

Other studies suggest that atypical femoral fracture may be associated with a less favorable prognosis in older patients,²⁰ but this could be due to differences in demographics, treatment adherence, or postfracture care.²¹

In addition, functional outcomes as measured by independent mobility at discharge and at 3 months were comparable between patients with atypical fracture and those with typical fracture.²²

IMAGING STUDIES

If a long-term bisphosphonate user presents with hip, thigh, or groin pain, imaging studies are recommended.

Plain radiography

Radiography is usually the first step and should include a frontal view of the pelvis (**Figure 1**) and 2 views of the full length of each femur. If radiography is not conclusive, bone scan or magnetic resonance imaging (MRI) should be considered.

A linear cortex transverse fracture pattern and focal lateral cortical thickening are the most sensitive and specific radiographic features.^{23,24} Because of the risk of fracture on the contralateral side, radiographic study of that side is recommended as well.

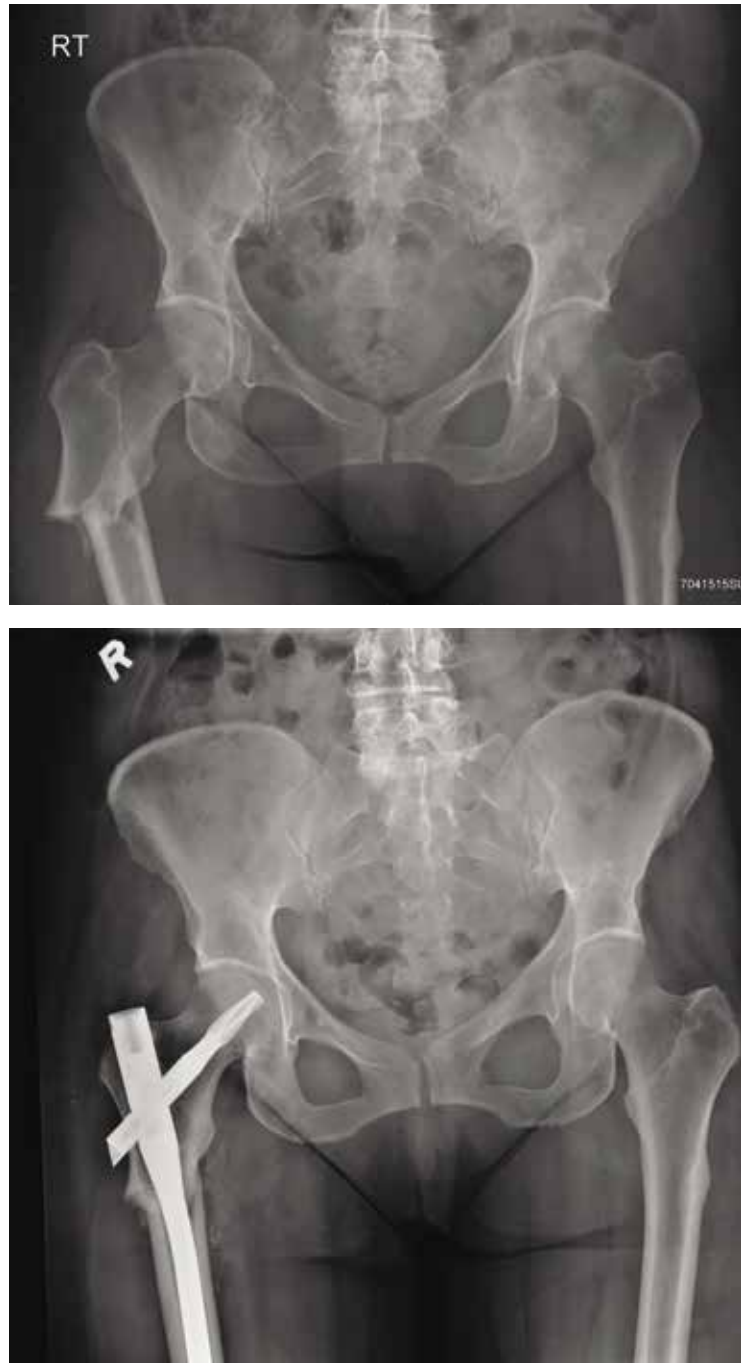

Figure 1. Top, an atypical femoral fracture. Bottom, after surgical repair.

Computed tomography

Computed tomography (CT) is not sensitive for early stress fractures and, given the radiation burden, is not recommended in the work-up of atypical fracture.

Bone scanning

Bone scanning using technetium 99m-labeled methylene diphosphonate with a gamma camera shows active bone turnover. Stress fractures and atypical femoral fractures are most easily identified in the third (delayed) phase of the bone scan. Although bone scanning is highly sensitive, the specificity is limited by lack of spatial resolution. Atypical femoral fracture appears as increased activity in the subtrochanteric region with a predilection for the lateral cortex.

Dual-energy x-ray absorptiometry

Conventional dual-energy x-ray absorptiometry (DXA) extends only to 1 to 2 cm below the lesser trochanter and can therefore miss atypical fractures, which usually occur farther down. The overall detection rate for DXA was 61% in a sample of 33 patients.²⁵

Newer scanners can look at the entire femoral shaft.²⁶ In addition, newer software can quantify focal thickening (beaking) of the lateral cortex and screen patients who have no symptoms. The results of serial measurements can be graphed so that the practitioner can view trends to help assess or rule out potential asymptomatic atypical femoral fracture.

A localized reaction (periosteal thickening of the lateral cortex or beaking) often precedes atypical femoral fracture. A 2017 study reported that patients with high localized reaction (mean height 3.3 mm) that was of the pointed type and was accompanied by prodromal pain had an increased risk of complete or incomplete atypical femoral fracture at that site.²⁷ This finding is used by the newer DXA software. The predictive value of beaking on extended femoral DXA may be as high as 83%.²⁶

Magnetic resonance imaging

The MRI characteristics of atypical femoral fracture are similar to those of other stress fractures except that there is a lateral-to-medial pattern rather than a medial pattern. The earliest findings include periosteal reaction about the lateral cortex with a normal marrow signal.

MRI may be of particular benefit in patients with known atypical femoral fracture to screen the contralateral leg. It should image the entire length of both femurs. Contrast enhancement is not needed.

Regardless of whether initial findings were discovered on conventional radiographs or DXA, MRI confirmation is needed. Radionuclide bone scanning is currently not recommended because it lacks specificity. Combination imaging is recommended, with either radiography plus MRI or DXA plus MRI.

DIFFERENTIAL DIAGNOSIS

The differential diagnosis of atypical femoral fracture includes stress fracture, pathologic fracture, hypophosphatasia, and osteogenesis imperfecta.²⁸ Hypophosphatemic osteomalacia can cause Looser zones, which can be confused with atypical femoral fractures but usually occur on the medial side.⁴ Stress fracture of the femur can occur below the lesser trochanter but usually begins in the medial, not the lateral, cortex.

Pathologic fractures from underlying osseous lesions can mimic the cortical beaking of bisphosphonate-related fracture, but they usually show the associated underlying lucent lesion and poorly defined margins. A sinus tract along the region of a chronic osteomyelitis may also appear similar.

Hypophosphatasia is an inborn error of metabolism caused by a loss-of-function mutation in the gene encoding alkaline phosphatase, resulting in pyrophosphate accumulation and causing osteomalacia from impaired mineralization. This can result in femoral pseudofracture that is often bilateral and occurs in the subtrochanteric region.²⁹

ADDITIONAL RISK FACTORS

Patients with atypical femoral fracture are generally a heterogeneous group, but there are risk factors to note other than bisphosphonate exposure.

Asian women had a risk 8 times higher than white women in 1 study.³⁰

Bone geometry. Mahjoub et al⁸ reported that compared with controls, patients with atypical femoral fracture had greater offset of the femoral shaft from the center of rotation of the femoral head, a more acute angle between the femoral neck and shaft, and greater proximal cortical thickness.

Medications. In addition to bisphosphonates, other drugs associated with atypical

An atypical femoral fracture is defined by both radiographic and clinical criteria

femoral fracture include RANK-ligand inhibitors such as denosumab (another drug for osteoporosis),³¹ glucocorticoids,^{32,33} and proton pump inhibitors.^{32,33}

Genetics. Three sisters with atypical femoral fracture were found to have 37 rare mutations in 34 genes, including one in the *GGPS1* gene, which codes for geranylgeranyl pyrophosphate synthase—an enzyme that bisphosphonates inhibit.³⁴

Medical conditions other than osteoporosis include collagen diseases, chronic pulmonary disease, asthma, rheumatoid arthritis, and diabetes.³⁵

Clinical recommendations

Current recommendations are to reevaluate bisphosphonate use in patients with osteoporosis after 5 or more years of therapy.³⁶

Given that patients with osteoporosis are at increased risk of typical fracture, those at higher risk should be considered for continued bisphosphonate therapy. Factors for high risk include the following:

- History of fracture on therapy
- Hip T score -2.5 or lower
- Older age (≥ 70)
- Other strong risk factors for fracture such as smoking, alcohol use, corticosteroid use, rheumatoid arthritis, and family history
- World Health Organization FRAX fracture risk score above the country-specific threshold.

Those at lower risk should be considered for a 2- to 3-year bisphosphonate holiday with periodic reevaluation of bone density and, possibly, bone markers.³⁶

■ WHAT IS THE UNDERLYING PATHOPHYSIOLOGY?

The mechanism by which bisphosphonates increase the risk of atypical femoral fracture is not clear. These drugs work by suppressing bone turnover; however, in theory, prolonged use could suppress it too much and increase bone fragility.

One hypothesis is that bisphosphonates impair the toughening of cortical bone, an important barrier to clinical fracture. This is supported by a study that found bisphosphonate users with atypical femoral fracture had deficits in intrinsic and extrinsic bone toughness, per-

haps due to treatment-related increases in matrix mineralization.³⁷ Although this study and others showed an increase in matrix mineralization and reduced mineralization heterogeneity with bisphosphonate use,^{38,39} it is unclear whether such changes contributed to reduced toughness or to atypical femoral fracture.

Changes in the skeletal geometry of the lower limb such as femoral neck-shaft angle and femoral curvature alter the stresses and strains experienced by the femoral diaphysis with loading. Because the incidence of incomplete atypical femoral fracture is much greater than that of complete fracture, most incomplete atypical femoral fractures heal before the fracture progresses.

Ultimately, all fractures, including atypical femoral fractures, occur when mechanical stress and strain exceed bone strength.

Antiresorptive drugs such as bisphosphonates, estrogen, calcitonin, and RANK ligand inhibitors prevent hip fracture by increasing the strength of the proximal femur—perhaps at the expense of the strength (or toughness) of the subtrochanteric shaft. It is also possible that treatment-related increases in hip strength (and reduced hip fracture rates) promote or sustain the transfer of stress and strain to femoral regions that experience lesser or no increases in strength from treatment, which likely includes the shaft.^{40,41}

CT studies in Japanese women with osteoporosis have shown that 2 years of zoledronate therapy had greater effects in the hip than in the femoral shaft, with significant increases in cortical thickness and volumetric bone mineral density at the femoral neck and intertrochanteric region compared with baseline.⁴² But zoledronate did not increase femoral shaft cortical thickness and caused only a minor increase in femoral shaft volumetric bone mineral density. Fracture patterns may have depended on damage and effects of bone turnover on mass and structure.

This hypothetical scenario portrays a possible “hip survival bias” mechanism for atypical femoral fracture, with the association with antiresorptive drugs arising from greater stress and strain in cortical regions where these fractures occur rather than from treatment-related reductions in cortical bone strength or toughness.

Risk factors include Asian ethnicity, femoral geometry, genetic mutations, and bisphosphonate use for more than 5 years

■ PRODROMAL PAIN IS COMMON

From 32% to 76% of patients who have incomplete or developing atypical femoral fracture present with a prodrome of groin or hip pain.^{4,43} Prodromal pain occurs any time from 2 weeks to several years before the fracture, presenting as pain in the anterior or lateral thigh or in the groin.

Prodromal pain in a patient on antiresorptive therapy should be a signal for the clinician to obtain a radiograph of the hip and to look for contralateral symptoms and fractures. The most common mechanism of injury appears to be a ground-level fall or even a nontraumatic activity such as walking or stepping off a curb.

■ MEDICAL MANAGEMENT

In bisphosphonate users with radiographic evidence of atypical femoral fracture, the bisphosphonate should be discontinued and the patient assessed for calcium and vitamin D deficiency, with supplements prescribed if needed.⁴

For patients with incomplete fracture and persistent pain after 3 months of medical management, prophylactic surgical nail fixation is recommended to prevent complete fracture.

Teriparatide, which has been associated with enhanced bone fracture healing, is a possible treatment to promote healing of atypical femoral fracture, either alone or as an adjunct to surgical fixation. A systematic review published in 2015 supported the use of teriparatide for enhancing fracture healing in atypical femoral fracture.⁴⁴ In addition, a 10-patient series⁴⁵ showed that incomplete fractures without radiolucent lines responded to teriparatide alone, whereas those with radiolucent lines needed intramedullary nailing.

These results suggest that teriparatide works best when the fracture site is stable, either inherently or with surgical fixation.

■ ORTHOPEDIC CARE

Orthopedic care for atypical femoral fracture differs depending on whether the patient experiences pain and whether the fracture is incomplete or complete. **Figure 2** shows a treatment algorithm for atypical femoral fracture.

These are difficult fractures to manage, complicated by delayed healing in the elderly, complex displacement patterns, altered bone

geometry, and risk of fracture in the opposite limb, all of which raise questions about recommending protected weight-bearing exercise.

Furthermore, atypical femoral fracture is often associated with increased anterolateral bowing of the femur, making it difficult to insert an intramedullary nail: the radius of curvature of the bone is shorter than that of a standard femoral nail. This mismatch can lead to intraoperative complications such as iatrogenic fracture during prophylactic nailing, malunion from excess straightening of the femur (which can itself lead to leg length discrepancy), and gapping of the fracture site, particularly on the medial side.

Intramedullary nailing for complete fracture

Intramedullary nailing is the first-line treatment for complete atypical femoral fracture, although the risk of delayed healing and revision surgery may be somewhat higher than with typical femoral fracture.⁴⁶ Prophylactic intramedullary nailing should be considered for a patient with intractable pain.²

A radiograph of the opposite leg should be obtained routinely, looking for an asymptomatic fracture. Bisphosphonates should be discontinued and calcium and vitamin D continued. Teriparatide therapy can be considered as an alternative treatment.

Conservative management for incomplete fracture without pain

Incomplete atypical femoral fracture unaccompanied by pain can be followed conservatively.⁴⁷ In addition to stopping antiresorptive therapy, patients need to avoid high-impact and repetitive-impact activities such as jumping or running. If pain occurs, patients should begin protected weight-bearing exercise.

Treatment is uncertain for incomplete fracture with pain

For patients with incomplete atypical femoral fracture and pain, treatment is controversial. Regimens that include 2 to 3 months of protected weight-bearing exercise, a full metabolic bone workup, calcium and vitamin D supplementation, and anabolic bone agents have produced some success. Some authors have reported poor results from conservative care, with few patients achieving pain relief or signs of complete healing.^{48,49} Additionally,

Orthopedic treatment depends on whether the patient has pain and whether the fracture is complete

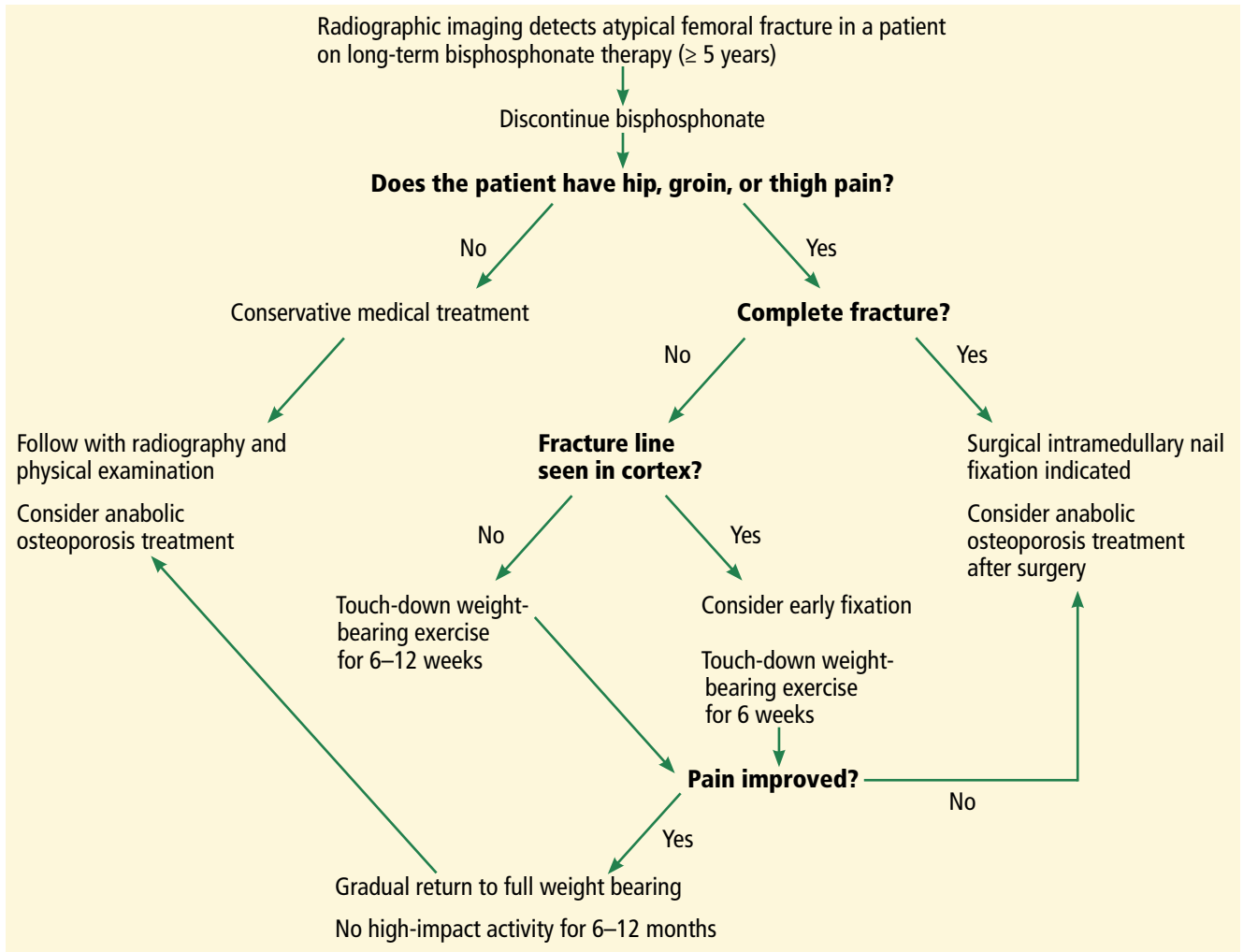


Figure 2. An algorithm for treating bisphosphonate-associated atypical femoral fracture.

if an incomplete fracture is found in the opposite femur, protected weight-bearing of both legs may not be possible.

Patients with incomplete fracture should be monitored regularly with radiography and physical examination. If there is progression of the fracture, escalation of pain, or failure to heal within 2 to 3 months, then surgical treatment is necessary.

Prophylactic placement of an intramedullary nail to prevent completion of the fracture and allow a return to full weight-bearing is generally advised.⁵⁰ A long locking plate can be used if bone deformities make it difficult to place an intramedullary nail; however, nails are preferred because they allow formation of endochondral callus, which can be helpful in these difficult-to-heal fractures.

Results from retrospective reviews have shown that surgically treated patients with bisphosphonate-associated incomplete atypical femoral fracture were more likely than those treated nonsurgically to be pain-free (81% vs 64%) and have radiographic healing (100% vs 18% at final follow-up).⁴⁶ Results have also been positive for those with complete atypical femoral fracture. At 6 months, 64% of surgically treated patients were pain-free and 98% were radiographically healed.⁵¹

The unusual geometry of the femur in patients with atypical femoral fracture and the presence of intramedullary cortical callus makes the placement of an intramedullary femoral rod more complex than in typical femoral fracture.⁸

Intramedullary nailing of atypical femoral fracture is a challenge for even the most ex-

perienced surgeon, and vigilance is imperative to avoid iatrogenic fracture and malunion.

MANY QUESTIONS REMAIN

We need more studies on the pathophysiology of bisphosphonate-associated atypical femoral frac-

ture, the value of periodic screening with DXA, and which factors predict high risk (eg, Asian ethnicity, use of certain medications, femoral geometry). In addition, we need more data on the success of conservative management of incomplete fracture, including use of teriparatide.

REFERENCES

- Black DM, Cummings SR, Karpf DB, et al. Randomised trial of effect of alendronate on risk of fracture in women with existing vertebral fractures. Fracture Intervention Trial Research Group. *Lancet* 1996; 348(9041):1535–1541. PMID:8950879
- Jha S, Wang Z, Laucis N, Bhattacharyya T. Trends in media reports, oral bisphosphonate prescriptions, and hip fractures 1996–2012: an ecological analysis. *J Bone Miner Res* 2015; 30(12):2179–2187. doi:10.1002/jbmr.2565
- Solomon DH, Johnston SS, Boytsov NN, McMorrow D, Lane JM, Krohn KD. Osteoporosis medication use after hip fracture in US patients between 2002 and 2011. *J Bone Miner Res* 2014; 29(9):1929–1937. doi:10.1002/jbmr.2202
- Shane E, Burr D, Abrahamsen B, et al. Atypical subtrochanteric and diaphyseal femoral fractures: second report of a task force of the American Society for Bone and Mineral Research. *J Bone Miner Res* 2014; 29(1):1–23. doi:10.1002/jbmr.1998
- Koeppen VA, Schilcher J, Aspenberg P. Dichotomous location of 160 atypical femoral fractures. *Acta Orthop* 2013; 84(6):561–564. doi:10.3109/17453674.2013.866193
- Schilcher J, Koeppen V, Aspenberg P, Michaëlsson K. Risk of atypical femoral fracture during and after bisphosphonate use. *Acta Orthop* 2015; 86(1):100–107. doi:10.3109/17453674.2015.1004149
- Khow KS, Shibu P, Yu SC, Chehade MJ, Visvanathan R. Epidemiology and postoperative outcomes of atypical femoral fractures in older adults: a systematic review. *J Nutr Health Aging* 2017; 21(1):83–91. doi:10.1007/s12603-015-0652-3
- Mahjoub Z, Jean S, Lederc JT, et al. Incidence and characteristics of atypical femoral fractures: clinical and geometrical data. *J Bone Miner Res* 2016; 31(4):767–776. doi:10.1002/jbmr.2748
- Schilcher J, Michaëlsson K, Aspenberg P. Bisphosphonate use and atypical fractures of the femoral shaft. *N Engl J Med* 2011; 364(18):1728–1737. doi:10.1056/NEJMoa1010650
- Dell RM, Adams AL, Greene DF, et al. Incidence of atypical nontraumatic diaphyseal fractures of the femur. *J Bone Miner Res* 2012; 27(12):2544–2550. doi:10.1002/jbmr.1719
- Park-Wyllie LY, Mamdani MM, Juurlink DN, et al. Bisphosphonate use and the risk of subtrochanteric or femoral shaft fractures in older women. *JAMA* 2011; 305(8):783–789. doi:10.1001/jama.2011.190
- Wang Z, Ward MM, Chan L, Bhattacharyya T. Adherence to oral bisphosphonates and the risk of subtrochanteric and femoral shaft fractures among female Medicare beneficiaries. *Osteoporos Int* 2014; 25(8):2109–2116. doi:10.1007/s00198-014-2738-x
- Abrahamsen B, Eiken P, Prieto-Alhambra D, Eastell R. Risk of hip, subtrochanteric, and femoral shaft fractures among mid and long term users of alendronate: nationwide cohort and nested case-control study. *BMJ* 2016; 353:i3365. doi:10.1136/bmj.i3365
- Feldstein AC, Black D, Perrin N, et al. Incidence and demography of femur fractures with and without atypical features. *J Bone Miner Res* 2012; 27(5):977–986. doi:10.1002/jbmr.1550
- Meier RP, Perneger TV, Stern R, Rizzoli R, Peter RE. Increasing occurrence of atypical femoral fractures associated with bisphosphonate use. *Arch Intern Med* 2012; 172(12):930–936. doi:10.1001/archinternmed.2012.1796
- La Rocca Vieira R, Rosenberg ZS, Allison MB, Im SA, Babb J, Peck V. Frequency of incomplete atypical femoral fractures in asymptomatic patients on long term bisphosphonate therapy. *AJR Am J Roentgenol* 2012; 198(5):1144–1151. doi:10.2214/AJR.11.7442
- Bissonnette L, April PM, Dumais R, Boire G, Roux S. Atypical fracture of the tibial diaphysis associated with bisphosphonate therapy: a case report. *Bone* 2013; 56(2):406–409. doi:10.1016/j.bone.2013.07.012
- Moon J, Bither N, Lee T. Atypical forearm fractures associated with long-term use of bisphosphonate. *Arch Orthop Trauma Surg* 2013; 133(7):889–892. doi:10.1007/s00402-013-1760-3
- Kharazmi M, Hallberg P, Schilcher J, Aspenberg P, Michaëlsson K. Mortality after atypical femoral fractures: a cohort study. *J Bone Miner Res* 2016; 31(3):491–497. doi:10.1002/jbmr.2767
- Medin E, Goude F, Melberg HO, Tediosi F, Belicza E, Peltola M; EUROHOPE Study Group. European regional differences in all-cause mortality and length of stay for patients with hip fracture. *Health Econ* 2015; 24(suppl 2):53–64. doi:10.1002/hec.3278
- Abrahamsen B, Prieto-Alhambra D. Patients with atypical femur fractures have the same mortality as the background population—drug channeling bias, bisphosphonate effects and public health implications. *J Bone Miner Res* 2016; 31(3):488–490. doi:10.1002/jbmr.2801
- Khow KS, Paterson F, Shibu P, Yu SC, Chehade MJ, Visvanathan R. Outcomes between older adults with atypical and typical femoral fractures are comparable. *Injury* 2017; 48(2):394–398. doi:10.1016/j.injury.2016.10.035
- Adams AL, Xue F, Chantra JQ, et al. Sensitivity and specificity of radiographic characteristics in atypical femoral fractures. *Osteoporos Int* 2017; 28(1):413–417. doi:10.1007/s00198-016-3809-y
- Rosenberg ZS, La Rocca Vieira R, Chan SS, et al. Bisphosphonate-related complete atypical subtrochanteric femoral fractures: diagnostic utility of radiography. *AJR Am J Roentgenol* 2011; 197(4):954–960. doi:10.2214/AJR.10.6262
- Kim S, Yang KH, Lim H, et al. Detection of prefracture hip lesions in atypical subtrochanteric fracture with dual-energy x-ray absorptiometry images. *Radiology* 2014; 270(2):487–495. doi:10.1148/radiol.13122691
- van de Laarschot DM, Smits AA, Buitendijk SK, Stegenga MT, Zillikens MC. Screening for atypical femur fractures using extended femur scans by DXA. *J Bone Miner Res* 2017; 32(8):1632–1639. doi:10.1002/jbmr.3164
- Sato H, Kondo N, Nakatsue T, et al. High and pointed type of femoral localized reaction frequently extends to complete an incomplete atypical femoral fracture in patients with autoimmune diseases on long-term glucocorticoids and bisphosphonates. *Osteoporos Int* 2017; 28(8):2367–2376. doi:10.1007/s00198-017-4038-8
- Giacini JC, Watterson CT. Bisphosphonate-related atypical femur fractures and the radiographic features. In: Silverman SL, Abrahamsen B, eds. *The Duration and Safety of Osteoporosis Treatment*. Switzerland: Springer International Publishing; 2016:107–124. doi:10.1007/978-3-319-23639-1
- Whyte MP. Atypical femoral fractures, bisphosphonates, and adult hypophosphatasia. *J Bone Miner Res* 2009; 24(6):1132–1134. doi:10.1359/jbmr.081253
- Lo JC, Hui RL, Grimsrud CD, et al. The association of race/ethnicity and risk of atypical femoral fracture among older women receiving oral bisphosphonate therapy. *Bone* 2016; 85:142–147. doi:10.1016/j.bone.2016.01.002
- Bone HG, Wagman RB, Brandi ML, et al. 10 years of denosumab treatment in postmenopausal women with osteoporosis: results from the phase 3 randomised FREEDOM trial and open-label extension. *Lancet Diabetes Endocrinol* 2017; 5(7):513–523. doi:10.1016/S2213-8587(17)30138-9
- Koh JH, Myong JP, Yoo J, et al. Predisposing factors associated with atypical femur fracture among postmenopausal Korean women

- receiving bisphosphonate therapy: 8 years' experience in a single center. *Osteoporos Int* 2017; 28(11):3251–3259. doi:10.1007/s00198-017-4169-y
33. Kim D, Sung YK, Cho SK, Han M, Kim YS. Factors associated with atypical femoral fracture. *Rheumatol Int* 2016; 36(1):65–71. doi:10.1007/s00296-015-3323-0
 34. Roca-Ayats N, Balcells S, Garcia-Giralt N, et al. GGPS1 mutation and atypical femoral fractures with bisphosphonates. *N Engl J Med* 2017; 376(18):1794–1795. doi:10.1056/NEJMc1612804
 35. Giusti A, Hamdy NA, Dekkers OM, Ramautar SR, Dijkstra S, Papapoulos SE. Atypical fractures and bisphosphonate therapy: a cohort study of patients with femoral fracture with radiographic adjudication of fracture site and features. *Bone* 2011; 48(5):966–971. doi:10.1016/j.bone.2010.12.033
 36. Adler RA, El-Hajj Fuleihan G, Bauer DC, et al. Managing osteoporosis in patients on long-term bisphosphonate treatment: report of a task force of the American Society for Bone and Mineral Research. *J Bone Miner Res* 2016; 31(1):16–35. doi:10.1002/jbmr.2708
 37. Lloyd AA, Gludovatz B, Riedel C, et al. Atypical fracture with long-term bisphosphonate therapy is associated with altered cortical composition and reduced fracture resistance. *Proc Natl Acad Sci USA* 2017; 114(33):8722–8727. doi:10.1073/pnas.1704460114
 38. Ettinger B, Burr DB, Ritchie RO. Proposed pathogenesis for atypical femoral fractures; lessons from materials research. *Bone* 2013; 55(2):495–500. doi:10.1016/j.bone.2013.02.004
 39. Burr DB, Liu Z, Allen MR. Duration-dependent effects of clinically relevant oral alendronate doses on cortical bone toughness in beagle dogs. *Bone* 2015; 71:58–62. doi:10.1016/j.bone.2014.10.010
 40. Sasaki S, Miyakoshi N, Hongo M, Kasukawa Y, Shimada Y. Low-energy diaphyseal femoral fractures associated with bisphosphonate use and severe curved femur: a case series. *J Bone Miner Metab* 2012; 30(5):561–567. doi:10.1007/s00774-012-0358-0
 41. Pulkkinen P, Gluer C, Jamsa T. Investigation of differences between hip fracture types: a worthy strategy of improved risk assessment and fracture prevention. *Bone* 2011; 49(4):600–604. doi:10.1016/j.bone.2011.07.022
 42. Ito M, Sone T, Shiraki M, et al. The effect of once-yearly zoledronic acid on hip structural and biomechanical properties derived using computed tomography (CT) in Japanese women with osteoporosis. *Bone* 2018; 106:179–186. doi:10.1016/j.bone.2017.10.013
 43. Bogdan Y, Einhorn TA. Clinical presentation of atypical femur fractures. In: Silverman SL, Abrahamsen B, eds. *The Duration and Safety of Osteoporosis Treatment*. Switzerland: Springer International Publishing; 2016:137–140. doi:10.1007/978-3-319-23639-1
 44. Im GI, Lee SH. Effect of teriparatide on healing of atypical femoral fractures: a systemic review. *J Bone Metab* 2015; 22(4):183–189. doi:10.11005/jbm.2015.22.4.183
 45. Saleh A, Hegde VV, Potty AG, Schneider R, Cornell CN, Lane JM. Management strategy for symptomatic bisphosphonate-associated incomplete atypical femoral fractures. *HSS J* 2012; 8(2):103–110. doi:10.1007/s11420-012-9275-y
 46. Egol KA, Park JH, Prenskey C, Rosenberg ZS, Peck V, Tejwani NC. Surgical treatment improves clinical and functional outcomes for patients who sustain incomplete bisphosphonate-related femur fractures. *J Orthop Trauma* 2013; 27(6):331–335. doi:10.1097/BOT.0b013e31827240ae
 47. Koh A, Guerado E, Giannoudis PV. Atypical femoral fractures related to bisphosphonate treatment: issues and controversies related to their surgical management. *Bone Joint J* 2017; 99-B(3):295–302. doi:10.1302/0301-620X.99B3.BJJ-2016-0276.R2
 48. Oh CW, Oh JK, Park KC, Kim JW, Yoon YC. Prophylactic nailing of incomplete atypical femoral fractures. *ScientificWorldJournal* 2013; 2013:450148. doi:10.1155/2013/450148
 49. Ha YC, Cho MR, Park KH, Kim SY, Koo KH. Is surgery necessary for femoral insufficiency fractures after long-term bisphosphonate therapy? *Clin Orthop Relat Res* 2010; 468(12):3393–3398. doi:10.1007/s11999-010-1583-2
 50. Tosounidis TH, Lampropoulou-Adamidou, Kanakaris NK. Intramedullary nailing of sequential bilateral atypical subtrochanteric fractures and the management of distal femoral intraoperative fracture. *J Orthop Trauma* 2015 Jun 11. Epub ahead of print. doi:10.1097/BOT.0000000000000370
 51. Egol KA, Park JH, Rosenberg ZS, Peck V, Tejwani NC. Healing delayed but generally reliable after bisphosphonate-associated complete femur fractures treated with IM nails. *Clin Orthop Relat Res* 2014; 472(9):2728–2734. doi:10.1007/s11999-013-2963-1

ADDRESS: Stuart Silverman, MD, 8641 Wilshire Boulevard, Suite 301, Beverly Hills, CA 90211; stuart@bhillsra.com