

THE CLINICAL PICTURE

MUHAMMED RAZMI T, MD, DNB

Senior Resident, Department of Dermatology, Venereology, and Leprology, Postgraduate Institute of Medical Education and Research, Chandigarh, India

DEBAJYOTI CHATTERJEE, MD

Senior Resident, Department of Histopathology, Postgraduate Institute of Medical Education and Research, Chandigarh, India

DAVINDER PARSAD, MD

Professor, Department of Dermatology Venereology, and Leprology, Postgraduate Institute of Medical Education and Research, Chandigarh, India

Scapular rash and endocrine neoplasia

A WOMAN IN HER 30s presented with an itchy skin-colored rash over her left scapular region that had first appeared 8 years earlier. It had started as itchy skin-colored papules that coalesced to a patch and later became hyperpigmented because of repeated scratching.

She had undergone total thyroidectomy for medullary thyroid carcinoma 1 year ago, and the rash had been diagnosed at that time as lichen planus. She was referred to us by her physician for histopathologic confirmation of the lesions. She denied any history of episodic headache or palpitation.

Her blood pressure was 134/86 mm Hg. On physical examination, groups of small hyperpigmented papules were noted over the left scapula (**Figure 1**).

Histopathologic study of a biopsy sample revealed focal degeneration of the basal cell layer with pigment incontinence and deposition of eosinophilic hyaline material along the tip of the papillary dermis, which was confirmed to be amyloid (**Figure 2**).

Her urine normetanephrine excretion was elevated at 1,425 µg/day (reference range 148–560), and her metanephrine excretion was also high at 2,024 µg/day (reference range 44–261).

Contrast-enhanced computed tomography of the abdomen revealed a right adrenal mass (**Figure 3**). Biopsy study of the mass confirmed pheochromocytoma, a manifestation of multiple endocrine neoplasia (MEN) type 2A.

At a 3-month follow-up visit, the woman's skin lesions had improved with twice-a-day application of mometasone 0.1% cream; she was lost to follow-up after that visit.

■ MULTIPLE ENDOCRINE NEOPLASIA

Our patient's scapular lesions and first-degree family history of MEN type 2A confirmed the diagnosis of the newly recognized variant, MEN type 2A-related cuta-

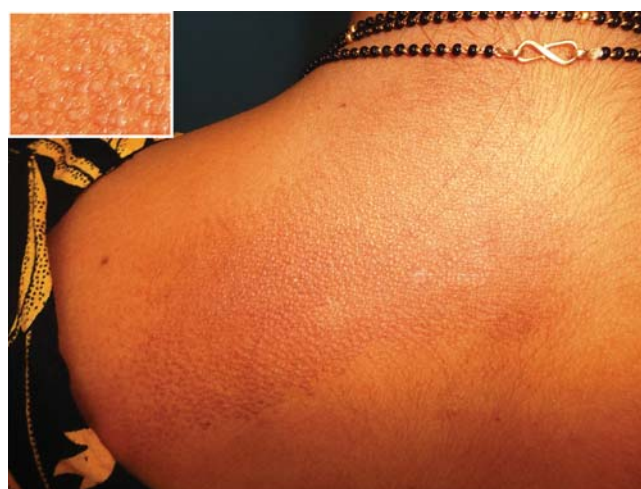

FIGURE 1. As seen in the inset, the skin-colored to hyperpigmented plane-topped papules coalesced to form a plaque over the left scapular area.

neous lichen amyloidosis, in which the characteristic pigmented scapular rash typically predates the first diagnosis of neoplasia.¹ The dermal amyloidosis is caused by deposition of keratinlike peptides rather than calcitoninlike peptides.²

A recent systematic review on MEN type 2A with cutaneous lichen amyloidosis showed a female preponderance and a high penetrance of cutaneous lichen amyloidosis, which was the second most frequent manifestation of the syndrome, preceded only by medullary thyroid carcinoma.¹

As in our patient's case, scapular rash and a history of medullary thyroid carcinoma should prompt an investigation for MEN type 2A. These patients should be closely followed for underlying MEN type 2A-related neoplasms.

The mucosal neuromas and skin lipomas seen in MEN type 1 and MEN type 2B are absent in MEN type 2A.³ Cutaneous lichen amyloidosis is the only dermatologic marker for MEN type 2A. Owing to a similar

doi:10.3949/ccjm.84a.16121

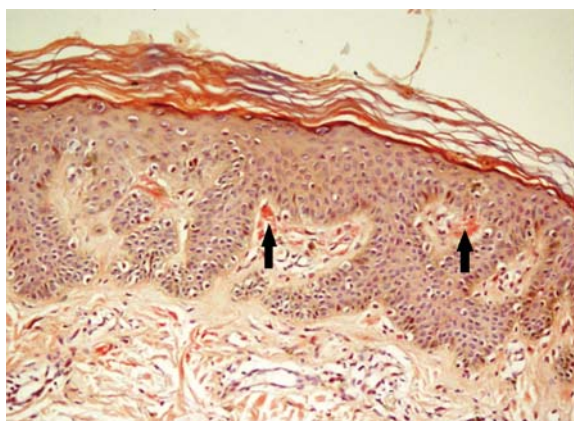


FIGURE 2. Biopsy study of the rash showed congophilic hyaline material along the tip of the papillary dermis (arrows). The apple-green birefringence on polarization confirmed the material to be amyloid (Congo red, $\times 200$).

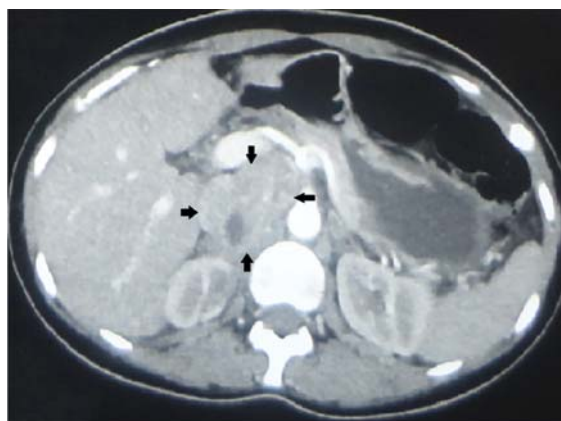

FIGURE 3. Computed tomography of the abdomen with contrast showed a heterogeneously enhancing lesion (arrows) in the right suprarenal area that measured 6.5 \times 5.5 \times 3.5 cm and displaced the inferior vena cava anteriorly.

genetic background, cutaneous lichen amyloidosis is also associated with familial medullary thyroid carcinoma, another rare variant of MEN type 2A.⁴

DIFFERENTIAL DIAGNOSIS

Notalgia paresthetica is a unilateral chronic neuropathic pruritus on the back, mostly located between the shoulders and corresponding to the second and the sixth thoracic nerves. It is mostly attributed to compression of spinal nerves by an abnormality of the thoracic spine.⁵ In our patient, this was ruled out by the radiologic evaluation.

Before MEN type 2A with cutaneous lichen amyloidosis was recognized as a variant of MEN type 2A, lesions suggestive of notalgia paresthetica were reported with MEN type 2A.³ The classic infrascapular location, history of painful neck muscle spasms, touch hyperesthesia of the lesions, and absence of amyloid

deposits on histopathologic study help to differentiate notalgia paresthetica from cutaneous lichen amyloidosis. However, later phases of notalgia paresthetica may show amyloid deposits on histopathologic study, while detection of a scant amount of amyloid is difficult in the early stages of cutaneous lichen amyloidosis.

TAKE-HOME POINT

Cutaneous lichen amyloidosis is usually seen on the extensor surfaces of the extremities. It is considered benign, caused by filamentous degeneration of keratinocytes from repeated scratching. But cutaneous lichen amyloidosis at an early age in the scapular area of women warrants a detailed family history for endocrine neoplasia, blood pressure monitoring, thyroid palpation, and blood testing for serum calcium, calcitonin, and parathyroid hormone.

The patient had a personal and family history of medullary thyroid carcinoma

REFERENCES

- Scapinelli JO, Ceolin L, Puñales MK, Dora JM, Maia AL. MEN 2A-related cutaneous lichen amyloidosis: report of three kindred and systematic literature review of clinical, biochemical and molecular characteristics. *Fam Cancer* 2016; 15:625–633.
- Donovan DT, Levy ML, Furst EJ, et al. Familial cutaneous lichen amyloidosis in association with multiple endocrine neoplasia type 2A: a new variant. *Henry Ford Hosp Med J* 1989; 37:147–150.
- Cox NH, Coulson IH. Systemic disease and the skin. In: Burns T,

Breathnach S, Cox N, Griffiths C, eds. *Rook's Textbook of Dermatology*. 8th ed. Chichester, UK: John Wiley and Sons Ltd; 2010:62.24.

- Moline J, Eng C. Multiple endocrine neoplasia type 2: an overview. *Genet Med* 2011; 13:755–764.
- Savk O, Savk E. Investigation of spinal pathology in notalgia paresthetica. *J Am Acad Dermatol* 2005; 52:1085–1087.

ADDRESS: Davinder Parsad, MD, Department of Dermatology, Venereology, and Leprology, Postgraduate Institute of Medical Education and Research, Sector 12, Chandigarh 160012, India; parsad@me.com