



Online Features

Access

Cleveland Clinic Journal of Medicine content is readily available to all and is free of charge at www.ccjm.org. On your first visit, we will ask you to take a few minutes to register, but subsequent visits will be unencumbered except for an occasional request for your e-mail address when you visit using another device (eg, mobile phone, tablet).

Services

- Navigate quickly to articles in current and past issues via links on the home page and pull-down menus at the top of the page. Use the search function to find a specific article, or browse by topic or article type.
- Continuing medical education activities are accessible from article links and from a CME pull-down menu on the home page. Participation is free.
- Follow links on the home page to news, summaries of recent scientific meetings, and interactive quizzes.
- Click on the PDF symbol at the top of any online article to read, download, or print the article in PDF format.

Social Networking

To post a CCJM article to Facebook or Twitter, just click on the icon at the top of any online article.

www.ccjm.org

SEPTEMBER 2016

TABLE OF CONTENTS

FROM THE EDITOR

The people behind the *Journal* really matter 631

This month, the *Journal* bids farewell to sales and marketing director Joe Dennehy and deputy editor Jim Pile.

B.F. MANDELL

THE CLINICAL PICTURE

'Air-raising': An air-fluid level in the right subphrenic region 638

Plain chest radiography showed dramatic elevation of the right hemidiaphragm with a large subphrenic air-fluid level.

A. GUPTA AND O. EPELBAUM

THE CLINICAL PICTURE

A man with HIV and papules and nodules on the knees 641

Erythema elevatum diutinum may be confused with Sweet syndrome, Kaposi sarcoma, or bacillary angiomatosis.

A.M. VICTORIA-MARTÍNEZ, L. CUBELLS-SÁNCHEZ, L. MARTÍNEZ-LEBORANS, J.L. SÁNCHEZ-CARAZO, AND V.A. DE MIQUEL

THE CLINICAL PICTURE

An abnormal peripheral blood smear and altered mental status 643

Therapeutic plasma exchange has greatly increased the survival rate in thrombotic thrombocytopenic purpura.

S. WONGRAKPANICH, M. SALAHUDDIN, AND P. MITTAR

1-MINUTE CONSULT

Are there alternatives to surgery for Zenker diverticulum? 645

High rates of complications in elderly patients have led to the development of endoscopic procedures.

N. AGGARWAL AND P.N. THOTA

IM BOARD REVIEW

Erythrocytosis due to presumed polycythemia vera 648

Erythrocytosis has a variety of potential causes.

R. PATELL, K. THEIL, AND A. LICHTIN



CONTINUED ON PAGE 630



REVIEW

Managing irritable bowel syndrome: The low-FODMAP diet 655

A diet low in fermentable oligosaccharides, disaccharides, monosaccharides, and polyols (FODMAPs) reduces symptoms.

M. DUGUM, K. BARCO, AND S. GARG

EDITORIAL

Diet in the pathophysiology and management of irritable bowel syndrome 663

Diet plays an important role in the pathophysiology of this disorder and is an effective tool in managing it.

M. EL-SALHY



ADDRESSING DISPARITIES IN HEALTHCARE.....

Gout and African Americans: Reducing disparities 665

African Americans are more likely to suffer from gout and are less likely to receive optimal treatment for it.

B. KUMAR AND P. LENERT

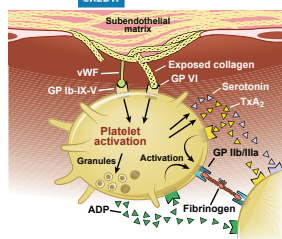


CURRENT DRUG THERAPY

Dual antiplatelet therapy for acute coronary syndromes: How long to continue? 675

After drug-eluting stent placement, at least 12 months of dual antiplatelet therapy is recommended. Would longer be better?

M. HALKAR AND A.M. LINCOFF



DEPARTMENTS

CME Calendar 633

Correction 644

An error appeared in the article "Total pancreatectomy and islet cell autotransplantation: Definitive treatment for chronic pancreatitis" (Arce KM, Lin YK, Stevens T, Walsh RM, Hatipoglu BA. Cleve Clin J Med 2016; 83:435-442.)

CME Test Directions

Inside back cover

Upcoming Features

- Update in perioperative cardiac medicine
- The ABCs of managing systolic heart failure
- Breaking the pain contract for chronic opioid therapy
- Dermatologic signs of nutritional deficiencies
- Serotonin syndrome: Not just from SSRIs
- Taurine energy drinks: Any risks? Benefits?
- Benign prostatic hyperplasia: Primary care management
- Give thrombolysis for submassive pulmonary embolism?
- Iodine deficiency: Clinical implications
- Bedbugs: A practical review



DEDICATED TO IMPROVING LEARNING
CLEVELAND CLINIC JOURNAL OF MEDICINE