

TABLE OF CONTENTS

FROM THE EDITOR

Predicting is tough, especially about the future 324

All risk calculators—not just for anticoagulation—are based on the “average” patient. And no patient is average.

B.F. MANDELL

THE CLINICAL PICTURE.....

Hordeolum: Acute abscess within an eyelid sebaceous gland 332

Chalazion and hordeolum are similar in appearance and often confused.

C. McALINDEN, M. GONZÁLEZ-ANDRADES, AND E. SKIADARESIS

THE CLINICAL PICTURE.....

This is not an acute coronary syndrome 335

Stress cardiomyopathy—broken heart syndrome—typically affects older women exposed to a stressful life event.

A.M. MAY, K. SHARAIN, J. BRENES-SALAZAR, AND L.J. SINAK

THE CLINICAL PICTURE.....

Epiglottic cysts in clinical practice 338

If the cysts are symptomatic, patients describe nonspecific pharyngeal discomfort or a foreign-body sensation.

Z. VOUREXAKIS



REVIEW

Measles: Back again 340

The disease is serious and highly contagious. Vaccination is safe and should be strongly promoted for healthy children.

D. KUMAR AND C. SABELLA

1-MINUTE CONSULT

How can I predict bleeding in my elderly patient taking anticoagulants? 345

We have tools, but their predictive value is modest. Clinical judgment is important.

G.R. QUINN AND M.C. FANG



CARDIOVASCULAR BOARD REVIEW.....

An 85-year-old woman with respiratory failure and positional hypoxemia 349

Her oxygen saturation was more than 93% when lying down but dropped to less than 85% when she was upright.

A. SENAPATI, H. RAI, AND A. DUGGAL

CONTINUED ON PAGE 320



Online Features

Access

Cleveland Clinic Journal of Medicine content is readily available to all and is free of charge at www.ccjm.org. On your first visit, we will ask you to take a few minutes to register, but subsequent visits will be unencumbered except for an occasional request for your e-mail address when you visit using another device (eg, mobile phone, tablet).

Services

- Navigate quickly to articles in current and past issues via links on the home page and pull-down menus at the top of the page. Use the search function to find a specific article, or browse by topic or article type.
- Continuing medical education activities are accessible from article links and from a CME pull-down menu on the home page. Participation is free.
- Follow links on the home page to news, summaries of recent scientific meetings, and interactive quizzes.
- Click on the PDF symbol at the top of any online article to read, download, or print the article in PDF format.

Social Networking

To post a *CCJM* article to Facebook or Twitter, just click on the icon at the top of any online article.

www.ccjm.org

CONTINUED FROM PAGE 318

REVIEW

Self-monitoring of blood glucose: Advice for providers and patients 355

Self-monitoring provides essential data and also motivates patients. A certified diabetes educator can help.

S. KNAPP, P. MANROA, AND K. DOSHI



REVIEW

Pseudomembranous colitis: Not always *Clostridium difficile* 361

Other causes include other infections, ischemia, medications, and inflammatory mucosal diseases.

D.M. TANG, N.H. URRUNAGA, AND E.C. VON ROSENVINGE



REVIEW

Reproductive health and the environment: Counseling patients about risks 367

Endocrine-disrupting chemicals are ubiquitous and affect multiple pathways. The precautionary principle should apply.

B. HARUTY, J. FRIEDMAN, S. HOPP, R. DANIELS, AND J. PREGLER

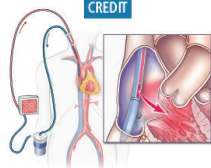


REVIEW

Extracorporeal membrane oxygenation in adults: A practical guide for internists 373

Principles, patient selection, monitoring, and complications of this form of life support.

T. KULKARNI, N.S. SHARMA, AND E. DIAZ-GUZMAN



REVIEW

Evaluation of nail lines: Color and shape hold clues 385

Inspection of the fingernails and toenails should be part of a complete physical examination.

S.R. LIPNER AND R.K. SCHER

DEPARTMENTS

CME Calendar 325**Letter to the Editor 326**

A reader comments on serum IgE testing for allergy (January 2016).

CME Test Directions 392

Upcoming Features

- Urinary stones: Preventing recurrence
- Prostate cancer: Every man's fate?
- Acute liver failure: ABCs of management
- Opioids for persistent pain in older adults
- Navigating pneumococcal vaccination
- I had a liver transplant—can I still have children?
- Dermatologic signs of nutritional deficiencies
- The low-FODMAP diet for irritable bowel syndrome
- Diagnosing cancer in primary care
- Suspect sleep apnea in difficult hypertension



DEDICATED TO IMPROVING LEARNING

CLEVELAND CLINIC JOURNAL OF MEDICINE