

Online Features

Access

Cleveland Clinic Journal of Medicine content is readily available to all and is free of charge at www.ccjm.org. On your first visit, we will ask you to take a few minutes to register, but subsequent visits will be unencumbered except for an occasional request for your e-mail address when you visit using another device (eg, mobile phone, tablet).

Services

- Navigate quickly to articles in current and past issues via links on the home page and pull-down menus at the top of the page. Use the search function to find a specific article, or browse by topic or article type.
- Continuing medical education activities are accessible from article links and from a CME pull-down menu on the home page. Participation is free.
- Follow links on the home page to news, summaries of recent scientific meetings, and interactive quizzes.
- Click on the PDF symbol at the top of any online article to read, download, or print the article in PDF format.

Social Networking

To post a CCJM article to Facebook or Twitter, just click on the icon at the top of any online article.

www.ccjm.org

DECEMBER 2016

TABLE OF CONTENTS

FROM THE EDITOR

- Hiding in clear sight: Complications of immunosuppressive therapies** 862
Immunosuppressive drugs can mask the signs of deep infection and thus delay its diagnosis.

B.F. MANDELL

THE CLINICAL PICTURE.....

- Phlegmasia cerulea dolens from radiation-induced venous stenosis** 865
The patient had received pelvic radiation 10 years earlier for prostate cancer.

S. PAUL AND M. SHEIKH

THE CLINICAL PICTURE.....

- Abdominal pain under immunosuppressive conditions** 874
A cancer patient receiving corticosteroids for a brain metastasis developed emphysematous cystitis and psoas muscle abscess.

T. OTA, M. NAKANO, N. TANAKA, T. SUZUMURA, N. MIYATAKE, Y. HASEGAWA, T. OZAKI, H. TSUKUDA, AND M. FUKUOKA

THE CLINICAL PICTURE.....

- Minocycline-induced hyperpigmentation** 876
The patient presented with extensive bluish skin discoloration that had started 1 year earlier as a small area and then spread.

M. ABDELGHANY AND A.J. KIVITZ

SMART TESTING

- What stool testing is appropriate when diarrhea develops in a hospitalized patient?** 882
Most cases are not due to infection, but *Clostridium difficile* is the most common infectious cause.

S.K. RAMDEEN AND G.W. WORTMANN

1-MINUTE CONSULT

- When should an indwelling pleural catheter be considered for malignant pleural effusion?** 891
Consider catheter placement if symptoms and effusions recur or if pleurodesis fails.

A.H. ALRAIYES, K. HARRIS, AND T.R. GILDEA

CONTINUED ON PAGE 860

CONTINUED FROM PAGE 855

REVIEW

Taurine, energy drinks, and neuroendocrine effects 895

Taurine is a major ingredient in popular energy drinks, but little is known about its neuroendocrine effects.

J.J. CAINE AND T.D. GERACIOTI



REVIEW

Women's health 2016: An update for internists 905

Important studies of urinary tract infections, bisphosphonates, ovarian cancer screening, and contraception.

P. BATUR, E.B. SCHWARZ, J.M.E. WALSH, AND K.M. JOHNSON



REVIEW

Radiation-induced heart disease: A practical guide to diagnosis and management 914

Unfortunately, radiotherapy for breast cancer or lymphoma can damage the heart.

E. DONNELLAN, D. PHELAN, P. COLLIER, M. DESAI, AND B. GRIFFIN

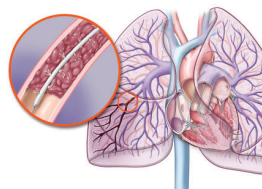


REVIEW

Do patients with submassive pulmonary embolism benefit from thrombolytic therapy? 923

The risk of hemorrhage is significant, and the benefit is unclear. A one-treatment-for-all approach cannot be applied.

A. ATAYA, J. COPE, A. SHAHMOHAMMADI, AND H. ALNUAIMAT



EDITORIAL

Thrombolysis in submassive pulmonary embolism: Finding the balance 933

In massive pulmonary embolism, thrombolytic therapy is usually indicated; in submassive cases the decision is not so clear.

C.L. ALVIAR AND G.A. HERESI

DEPARTMENTS

CME Calendar 854

CME Test Directions Inside back cover

Upcoming Features

- Postexposure management of infectious diseases
- Managing benign prostatic hyperplasia in primary care
- Statins and the frail elderly: When is it time to forgo?
- What is the role of roflumilast in COPD?
- Blood transfusion: Is less really more?
- Vulvovaginitis: Not only infectious causes
- Diagnosing acid-base disorders in 5 easy steps
- Staying afloat in a sea of information
- Female sexual dysfunction: Common and complex

